

Correlation of Clinical, Radiological and Endoscopic Grading of Adenoid Hypertrophy in Paediatric Population: A Cross-sectional Study

ISHI JAIN¹, PUSHKAR KHARE²

ABSTRACT

Introduction: Adenoid hypertrophy is one of the most common conditions encountered by Ear, Nose and Throat (ENT) surgeons in the paediatric age group. Clinical assessment of adenoid hypertrophy is the first step, but to confirm the degree of adenoid hypertrophy, both X-ray soft-tissue neck and endoscopy are needed.

Aim: To correlate the clinical grading of adenoid hypertrophy with endoscopic and radiological findings.

Materials and Methods: This was a hospital-based cross-sectional analytical study conducted at Chhatrapati Shivaji Subharti Hospital Meerut, Uttar Pradesh, India from August 2023 to January 2024. A total of 50 children aged between 4 and 15 years, who presented to the outpatient department of ENT with signs and symptoms of adenoid hypertrophy, were evaluated. These children underwent clinical evaluation, followed by endoscopy and X-ray lateral view of the soft-tissue neck.

Adenoid hypertrophy was graded clinically, endoscopically and radiologically. Statistical analysis was performed using Kendall's tau correlation analysis.

Results: In the study population, the majority of children 17 (34%) were between the ages of 7 and 9 years, with a male predominance of 32 (64%). Grade-3 adenoid hypertrophy was the most common finding, observed in 21 (42%) based on clinical grading, 26 (52%) on endoscopy, and 19 (38%) on X-ray lateral view of the soft-tissue neck. There was a strong correlation between endoscopic and clinical grading (p -value=0.001), and the correlation between radiological and endoscopic grading was highly significant (p -value=0.001). Clinical grading and radiological findings also showed a significant correlation (p -value=0.002).

Conclusion: All three modalities of adenoid grading are correlated and reliable. They can be used in different combinations for grading adenoid hypertrophy and determining the management plan.

Keywords: Adenoids, Endoscopy, Radiology

INTRODUCTION

Adenoid hypertrophy is one of the most common conditions encountered by ENT surgeons in the paediatric age group. The adenoid is a component of Waldeyer's ring, formed by the aggregation of lymphoid tissue at the junction of the oropharynx and nasopharynx [1]. Adenoids develop during the seventh month of intrauterine life, continue to grow until the fifth year of life, and then gradually atrophy [2]. The arterial supply of the tonsil comes from the ascending pharyngeal artery, the pharyngeal branch of the maxillary artery, the ascending palatine artery, the artery of the pterygoid canal, and the tonsillar branch of the facial artery [1]. Venous drainage occurs through the pharyngeal plexus, which further drains into the pterygoid plexus, ultimately leading to the internal jugular and facial veins [2]. Adenoids are supplied by the pharyngeal plexus and lymphatic drainage occurs to the retropharyngeal and pharyngomaxillary space lymph nodes [2].

Adenoids play an important role in the development of immunity in young children; thus, the removal of adenoids at an early age can lead to lowered immunity [3]. Adenoid hypertrophy can result in eustachian tube dysfunction, otitis media with effusion, acute otitis media, obstructive sleep apnoea, failure to thrive, poor cognitive development, poor academic performance, and complete or partial obstruction of the nasal choanae, which can lead to diseases of the upper respiratory tract [4].

Assessment of adenoid hypertrophy can be performed clinically, endoscopically and radiologically. Clinical evaluation involves

examining signs and symptoms such as mouth breathing, adenoid facies, otitis media, snoring and sleep disturbances [5]. During the first pass of diagnostic nasal endoscopy, adenoids can be graded from 1 to 4 [1]. Radiologically, a lateral view X-ray of the soft neck is utilised to evaluate the adenoids and the adenoid-nasopharynx ratio is measured to grade the adenoid hypertrophy [6]. This study aimed to correlate the clinical grading of adenoid hypertrophy with endoscopic and radiological findings.

MATERIALS AND METHODS

This was a hospital-based cross-sectional analytical study conducted at Chhatrapati Shivaji Subharti Hospital Meerut, Uttar Pradesh, India from August 2023 to January 2024, following clearance from the ethical committee of Subharti University (SMC/UECN/2023/246/186). A total of 50 children, aged between 4 to 15 years, who presented to the outpatient department of ENT during the study period were evaluated.

Inclusion criteria: Parents of children who actively gave consent, children aged between 4 to 15 years, children with signs and symptoms of adenoid hypertrophy (otitis media with effusion, acute otitis media, mouth breathing, snoring, elongated dull-looking face, irregular or crowded dentition, high-arched palate, hitched upper lip and sleep disturbances) were included in the study.

Exclusion criteria: Children with congenital anomalies such as Down syndrome, choanal atresia, upper respiratory tract infections, septal deviations and allergic rhinitis were excluded from the study.

Study Procedure

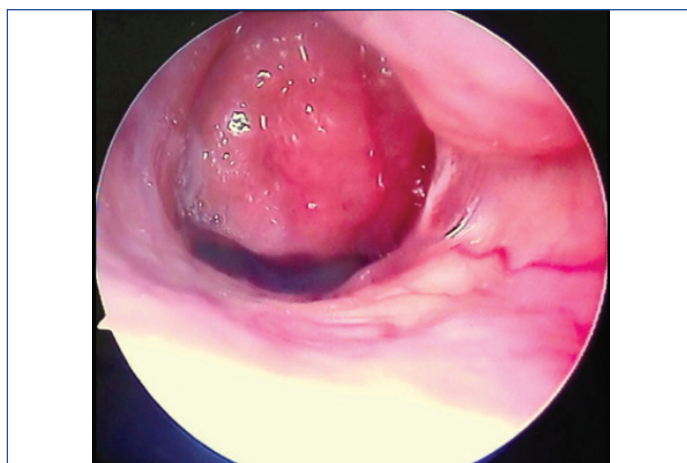
Children were first clinically assessed by taking a history of mouth breathing, ear pain or discharge, previous ear infections, snoring during sleep and sleep disturbances. The patient was inspected for craniofacial abnormalities, such as an elongated face, high-arched palate, or irregular dentition. Clinical grading was then conducted [Table/Fig-1] [7]. Following this, diagnostic nasal endoscopy was performed, and adenoid hypertrophy was graded based on the Clements and McMurray classification, which measures the extent to which the adenoids fill the vertical height of the choanae [Table/Fig-2,3]. Lastly, a soft-tissue lateral view X-ray of the neck was taken, and the Adenoid-Nasopharyngeal Ratio (ANR) was calculated. The size of the adenoid was determined by drawing a perpendicular line from the anterior margin of the basiocciput to the maximum convexity of the adenoid [Table/Fig-4,5]. The size of the nasopharynx was calculated by drawing a line between the posterior-superior edge of the hard palate and the anterior-inferior edge of the sphenobasiocciput. The adenoid size and nasopharyngeal size were measured separately, and the adenoid-nasopharyngeal ratio was calculated [8].

	Category	Score
—	Nose	
	Severity	
1	Mouth breathing/snoring is absent	0
2	Mouth breathing/snoring present on few occasions	1
3	Mouth breathing/snoring present whenever asleep	2
4	Mouth breathing/snoring always present	3
—	Ear	
1	Absent	0
2	Occasional serous otitis media/acute suppurative otitis media	1
3	Persistent serous otitis media/ <3 episodes/ year of acute suppurative otitis media	2
4	Unilateral or bilateral chronic suppurative otitis media of tubotympanic type/atelectasis with impending cholesteatoma	3
—	Craniofacial abnormalities	
1	Absent	0
2	Elongated dull looking face	1
3	Irregular/crowded dentition, high arched palate, hitched upper lip	2
4	All features of adenoid facies	3
—	Sleep disturbance	
1	Absent	0
2	Present occasionally during upper respiratory tract infections	1
3	Present everyday with <= 3 episodes /night daily	2
4	>3 episodes/ night daily.	3
Scoring		
Grade	Score	
Grade I	0-3	
Grade II	4-6	
Grade III	7-9	
Grade IV	10-12	

[Table/Fig-1]: Clinical scoring [7].

Clements and Mc Murray classification	
Grade I	Adenoid tissue filling 1/3 rd of the vertical height of choana
Grade II	Adenoid tissue filling up to 2/3 rd of the vertical height of choana
Grade III	From 2/3 rd to nearly all but not completely filling the choana.
Grade IV	Complete choanal obstruction

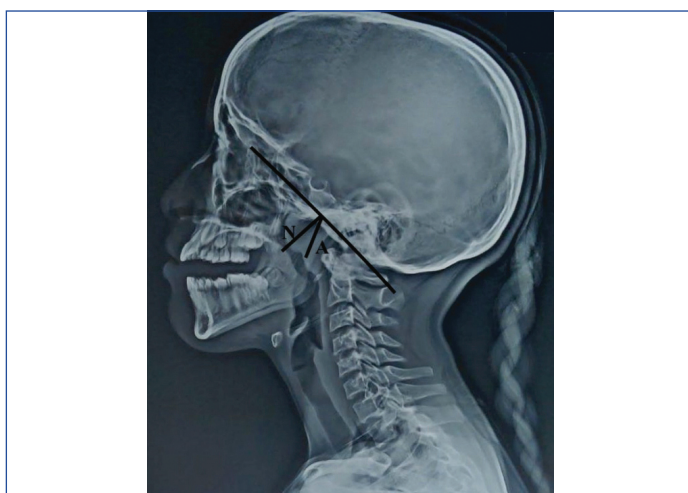[Table/Fig-2]: Endoscopic scoring [1].



[Table/Fig-3]: Adenoid on endoscopy.

Grading	Adenoid Nasopharyngeal Ratio (ANR)
Grade I	0-25%
Grade II	25-50%
Grade III	50-75%
Grade IV	75-100%

[Table/Fig-4]: Radiological grading [8].



[Table/Fig-5]: X-ray neck soft-tissue lateral view.

STATISTICAL ANALYSIS

All categorical variables were analysed using frequency and percentage. The correlation between clinical findings, radiographic findings and nasal endoscopy was calculated using Kendall's tau correlation analysis. Statistical Package for Social Sciences (SPSS) software version 21.0 was used, and a p-value <0.005 was considered significant.

RESULTS

In the study population, 32 (64%) of the children were male, while 18 (36%) were female. Out of 50 children, 11 (22%) were between 4-6 years old, the majority, 17 (34%), were between 7-9 years old, 14 (28%) were between 10-12 years old, and only 8 (16%) were between 13-15 years old. In the study, according to signs and symptoms, the majority of the children, 21 (42%), had Grade-III adenoid hypertrophy [Table/Fig-6]. On diagnostic nasal endoscopy, it was observed that 26 (52%) of the children had Grade-III adenoid hypertrophy [Table/Fig-7]. On X-ray lateral view of the soft tissue neck, 19 (38%) of the children had Grade-III adenoid hypertrophy [Table/Fig-8]. The coefficient of 0.84 suggests a very high positive correlation [Table/Fig-9]. The coefficient of 0.53 suggests a positive correlation [Table/Fig-10]. The coefficient of 0.81 suggests a very high positive correlation [Table/Fig-11].

Grade	n (%)
Grade I	8 (16)
Grade II	12 (24)
Grade III	21 (42)
Grade IV	9 (18)

[Table/Fig-6]: Distribution of subjects according to clinical grading.

Grade	n (%)
Grade I	6 (12)
Grade II	11 (22)
Grade III	26 (52)
Grade IV	7 (14)

[Table/Fig-7]: Distribution of subjects according to endoscopic grading.

Grade	n (%)
Grade I	12 (24)
Grade II	9 (18)
Grade III	19 (38)
Grade IV	10 (20)

[Table/Fig-8]: Distribution of subjects according to radiological grading.

	Endoscopic grading					Total
	Grading	Grade I	Grade II	Grade III	Grade IV	
Clinical grading	Grade I	6	0	2	0	8
	Grade II	0	9	3	0	12
	Grade III	0	1	18	2	21
	Grade IV	0	1	3	5	9
	Total	6	11	26	7	50

[Table/Fig-9]: Correlation between clinical and endoscopic grading.
p-value (p)= 0.001, correlation coefficient (r)= 0.84

	Radiological grading					Total
	Grading	Grade I	Grade II	Grade III	Grade IV	
Clinical grading	Grade I	5	1	2	0	8
	Grade II	1	6	5	0	12
	Grade III	4	1	12	4	21
	Grade IV	2	1	0	6	9
	Total	12	9	19	10	50

[Table/Fig-10]: Correlation between radiological and clinical grading.
p-value (p)= 0.002, correlation coefficient (r)= 0.53

	Radiological grading					Total
	Grading	Grade I	Grade II	Grade III	Grade IV	
Endoscopic grading	Grade I	5	1	0	0	6
	Grade II	2	6	3	0	11
	Grade III	5	2	15	4	26
	Grade IV	0	0	1	6	7
	Total	12	9	19	10	50

[Table/Fig-11]: Correlation between radiological and endoscopic grading.
p-value (p)=0.001, correlation coefficient (r)= 0.81

DISCUSSION

In the current study, the male population constituted 64%, while the female population accounted for 36%, which was similar to the study conducted by Jyothirmal ASL et al., where the male population was 58% and the female population was 42% [7]. In present study, the association between endoscopic grading and clinical grading was highly significant (p-value=0.001), which aligns with studies conducted by Sharifkashani S et al., Saedi B et al., and Kugelman N et al., which also demonstrated a highly significant correlation between endoscopic grading and clinical grading (p-value<0.001), (p-value<0.001), and (p-value<0.0001), respectively [8-10].

Furthermore, present study found a significant correlation between radiological and clinical grading (p-value=0.002), which was consistent with the results of studies conducted by Jyothirmal ASL et al., (p-value=0.04), Saedi B et al., (p-value<0.001), and Dixit Y and Tripathi PS [7,9,11]. However, studies conducted by Sharifkashani S et al., and Kugelman N et al., reported no such correlation [8,10].

The correlation between radiological and endoscopic grading was highly significant in present study (p-value=0.001). The results were similar to those of studies conducted by Lourenco EA et al., (p-value=0.002), Kurien M et al., (p-value=0.002), Dawood MR and Khammas AH (p-value=0.0005), and Yaseen ET et al., (p-value=0.0003) [12-15].

Each modality has its own merits and demerits. Clinical grading is primarily dependent on the history provided by the patient, which can sometimes be misleading. On the other hand, clinical grading is non invasive and does not involve radiation. Endoscopic grading, which involves diagnostic nasal endoscopy using a 0-degree endoscope, is an invasive procedure, and some patients may not co-operate during the process, making it difficult to visualise the nasopharynx. Radiological grading is performed using an X-ray soft-tissue neck lateral view, which is a convenient, non invasive, and patient-independent method, but it does require radiation exposure.

Limitation(s)

A small sample size and a single-centre study may limit the generalisability of the findings.

CONCLUSION(S)

All three modalities of adenoid grading are correlated and reliable. They can be used in different combinations for grading adenoid hypertrophy and deciding on a management plan. In conclusion, a combination of two modalities is required to achieve accurate grading and formulate an effective management plan.

REFERENCES

- [1] Browning GG, Burton MJ, Clarke R, Hibbert J, Jones NS, Lund VJ, et al. Scott-brown's otorhinolaryngology: Head and Neck Surgery, 7th ed. Hodder Education (UK); 2008.
- [2] Flint PW, Haughey BH, Lund JV, Niparko JK, Richardson MA, Robbins KT, et al. Cummings otolaryngology- Head and Neck Surgery, 5th ed. Elsevier (PA); 2010.
- [3] Peter J. The adenoid and adenoidectomy. In: George GB, Ray C, John H, Martin JB, Nicholas SJ, editors. 7th Edn. vol. 1. London; Arnold: Hodder; 2008. Pp. 1095-101.
- [4] Orji FT, Ezeanolue BC. Evaluation of adenoidal obstruction in children: Clinical symptoms compared with roentgenographic assessment. J Laryngol Otol. 2008;122(11):1201-05. Doi: 10.1017/s0022215108001916.
- [5] Muzumdar H, Arens R. Diagnostic issues in pediatric obstructive sleep apnea. Proc Am Thoracic Soc. 2008;5(2):263-73. Doi:10.1513/pats.200707-113mg.
- [6] Fujioka M, Young LW, Girdany BR. Radiographic evaluation of adenoidal size in children: Adenoidal-nasopharyngeal ratio. Am J Roentgenol. 1979;133(3):401-04. Doi: 10.2214/ajr.133.3.401.
- [7] Jyothirmal ASL, Sadhana O, Chandra TS, Murthy PSN. Assessment of adenoid hypertrophy with clinical grading versus radiology and endoscopy- A cross-sectional study. IP J Otorhinolaryngol Allied Sci. 2020;3(4):130-35.
- [8] Sharifkashani S, Dabirmoghaddam P, Kheirkhan M, Hosseizadehnik R. A new clinical scoring system for adenoid hypertrophy in children. Iranian J Otorhinolaryngol. 2015;27(78):55-61.
- [9] Saedi B, Sadeghi M, Mojtahed M, Mahboubi H. Diagnostic efficacy of different methods in the assessment of adenoid hypertrophy. Am J Otolaryngol. 2011;32(2):147-51.
- [10] Kugelman N, Ronen O, Stein N, Huberfeld O, Cohen-Kerem R. Adenoid obstruction assessment in children: Clinical evaluation versus endoscopy and radiography. Isr Med Assoc J. 2019;21(6): 376-80.
- [11] Dixit Y, Tripathi PS. Community level evaluation of adenoid hypertrophy on the basis of symptom scoring and its X-ray correlation. J Family Med Prim Care. 2016;5(4):789-91.
- [12] Lourenco EA, Lopes KC, Pontes A, Oliveira MH, Umemuro A, Vargas A, et al. Comparison between radiological and laryngoscopic assessment of adenoid tissue volume in mouth breathing children. Rev Bras Otorhinolaryngol. 2005;71:23-28.
- [13] Kurien M, Lepcha A, Mathew J, Ali A, Jeyaseelan L. X-rays in the evaluation of adenoid hypertrophy: It's role in the endoscopic era. Indian J Otolaryngol Head Neck Surg. 2005;57(1):45-47.

[14] Dawood MR, Khammas AH. Diagnostic accuracy of radiology and endoscopy in the assessment of adenoid hypertrophy. An Int J Otorhinolaryngol Clin. 2017;9(1):06-09.

[15] Yaseen ET, Khammas AH, Al-Anbaky F. Adenoid enlargement, assessment by plain X-ray and nasoendoscopy. Iraqi J Comm Med. 2012;2012(1):88-91.

PARTICULARS OF CONTRIBUTORS:

1. Junior Resident, Department of Otorhinolaryngology, Subharti University, Meerut, Uttar Pradesh, India.
2. Associate Professor, Department of Otorhinolaryngology, Subharti University, Meerut, Uttar Pradesh, India.

NAME, ADDRESS, E-MAIL ID OF THE CORRESPONDING AUTHOR:

Dr. Ishi Jain,
3 Gulmohar Park Colony Baghpat Road, Meerut, Uttar Pradesh, India.
E-mail: jain.ishi17@gmail.com

PLAGIARISM CHECKING METHODS: [\[Jain H et al.\]](#)

- Plagiarism X-checker: Jul 09, 2024
- Manual Googling: Oct 08, 2024
- iThenticate Software: Oct 14, 2024 (14%)

ETYMOLOGY: Author Origin

EMENDATIONS: 7

AUTHOR DECLARATION:

- Financial or Other Competing Interests: None
- Was Ethics Committee Approval obtained for this study? Yes
- Was informed consent obtained from the subjects involved in the study? Yes
- For any images presented appropriate consent has been obtained from the subjects. Yes

Date of Submission: **Jul 09, 2024**

Date of Peer Review: **Sep 11, 2024**

Date of Acceptance: **Oct 15, 2024**

Date of Publishing: **Nov 01, 2024**