

A Cross-sectional Study of Wormian Bones in the Cranium: Exploring their Clinical Significance and Diagnostic Implications

ABHINAV KUMAR¹, JOLLY AGARWAL², ANJALI SHARAN³, SHRIKANT BHARTI⁴, PUNEET CHAUDHARY⁵, SHIVANGI THAKUR⁶, SWATI SAXENA⁷, MAHENDRA KUMAR PANT⁸



ABSTRACT

Introduction: Wormian Bones (WBs) are small, irregularly shaped ossicles often located within the cranial sutures and at the fontanelles, with the majority found in the lambdoid sutures. They result from the formation of abnormal ossification centres in the cranium that develop through an unknown mechanism. Clinically, Significant Wormian Bones (SWBs) are defined as bones arranged in a general mosaic-like pattern with a size larger than 6×4 mm; for pathological significance, more than 10 such SWBs should be present.

Aim: To study the incidence of WBs in various sutures of human dry skulls and to investigate the incidence of the metopic suture and Inca bone in human dry skulls.

Materials and Methods: The present cross-sectional study was conducted in the Department of Anatomy, Government Doon Medical College, Dehradun, Uttarakhand, India, from January

2024 to May 2024. In the present study, 38 dried adult human skulls of unknown age and sex were examined for the presence, number and location of WBs, the metopic suture, and the Inca bone in various sutures of the skull. The data were analysed using descriptive statistics, and results were expressed in terms of incidence.

Results: Wormian bones were present in 21 (55.26%) skulls, while 17 (44.74%) had no WBs. One (0.27%) skull had a metopic suture, and 1 (0.27%) skull had an Inca bone. Pathologically significant WBs were not found in any of the skulls examined.

Conclusion: The overall incidence of WBs is 55.26%, while the incidences of the metopic suture and Inca bone are both 2.63%. Thus, WBs may mimic a cranial fracture, leading to misdiagnosis, which could delay or alter treatment. Additionally, some WBs may be lost during putrefaction, giving the appearance of an entry/exit gunshot wound in postmortem cases.

Keywords: Accidental bones, Epipteric bones, Intercalated bones, Pterion ossicles, Supernumerary ossicles, Sutural bones

INTRODUCTION

The human cranium consists of numerous bones that fuse together after delivery, further to the regular centers of ossification of the skull [1]. Sutural bones are small, irregularly shaped ossicles often located within the cranial sutures and at the fontanelles, especially in relation to the parietal bones. They are most commonly found in the lambdoid suture, while the next most common site is the epipteric bone (pterion ossicle), located near the former anterolateral fontanelle [2,3].

The term WBs is synonymous with supernumerary ossicles, sutural bones, intercalated bones, accidental bones, pterion ossicles, epipteric bones and flower's bones [1]. Thomas Bartholin coined the term WBs in honour of the Dutch anatomist Olaus Wormius. More recently, Bellamy, in 1842, described this variation in two mummified Peruvian skulls. Bellamy's observations were confirmed by others, although it was initially believed that this anomaly only occurred in Incan populations [4]. The consequence of these irregular ossification centers is the formation of islands of isolated bones in various locations in the skull [1].

The WBs result from the formation of abnormal ossification centers in the cranium that develop in addition to the normal ossification process. The mechanisms responsible for the formation of WBs are not precisely known [2]. Some authors believe that extrinsic influences, such as metabolic disorders of the mesoderm and head stress (including pathology and hydrocephaly), are responsible for their occurrence. However, many other authors argue that sutural bones derive from normal developmental processes and are genetically determined. It has also been reported that sometimes sutural bones at the lambda represent pre-interparietal components

of the occipital bone. According to these authors, it is difficult to differentiate a pre-interparietal squamous bone from a true sutural bone at the lambda [3]. The reported incidence of WBs is variable, ranging from around 10% in Caucasian skulls to 40% in Indian skulls and up to 80% in Chinese skulls. In general, males are more frequently affected than females [5].

Wormian bones have both diagnostic and pathological significance, as they can provide important information or act as crucial markers for illnesses that appear to be silent. The size, number and placement of these bones are significant parameters for examining and differentiating pathological from typical WBs variations. For WBs to be considered pathologically significant, they must be more than ten in number and arranged in a general mosaic-type pattern, with sizes larger than 6×4 mm [6]. Conditions such as Down syndrome, hypothyroidism, osteogenesis imperfecta, hypophosphatasia, rickets (in the healing phase), otopalatodigital syndrome and kinky hair syndrome have been found to be associated with the formation of WBs. Increased intracranial pressure, as seen in hydrocephalus, causes the sutures to spread out, while cranial sutures and fontanelles become wider in diseases associated with decreased skull ossification [7,8].

The presence of sutural bones may mislead the diagnosis when X-rays are taken, as they may be mistaken for fractures [2]. A study reported that individuals with WBs often exhibit cranial and central nervous system disorders. WBs are also present in normal individuals and in various disorders, including pycnodysostosis, osteogenesis imperfecta, rickets, kinky hair syndrome, cleidocranial dysostosis, hypothyroidism, hypophosphatasia, otopalatodigital syndrome, primary acro-osteolysis and Down syndrome [1,6].

According to Cremin B et al., a Significant Wormian Bone (SWB) is defined as having a diameter greater than 6 mm on one axis and 4 mm on another at right angles, with an arrangement tending toward a mosaic pattern [6]. To be considered pathologically significant, the skull should have more than ten SWBs.

The aim of the present study was to determine the incidence of WBs in various sutures and to investigate the incidence of the metopic suture and Inca bone in human dry skulls from the Dehradun district, Uttarakhand, India. A similar study has not been conducted in the Uttarakhand region to date. The current study adds to the current data with findings from related studies, emphasising the ethnic and genetic differences in the occurrence of WBs, the metopic suture and the Inca bone. By contributing new data, the present study was aimed to fill the existing gap in knowledge.

MATERIALS AND METHODS

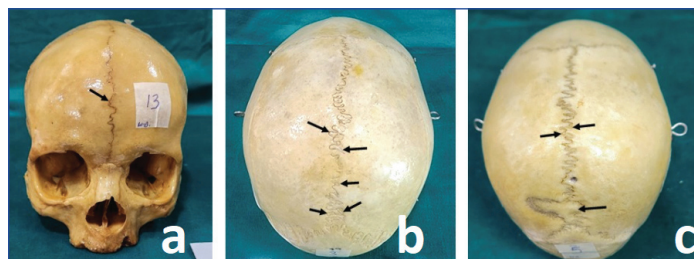
The present cross-sectional study was carried out in the Department of Anatomy, Government Doon Medical College, Dehradun, Uttarakhand, India, from January 2024 to May 2024. The study was conducted on 38 dried adult human skulls of unknown age and sex.

Inclusion criteria: Anatomically normal and undamaged skulls were included in the study.

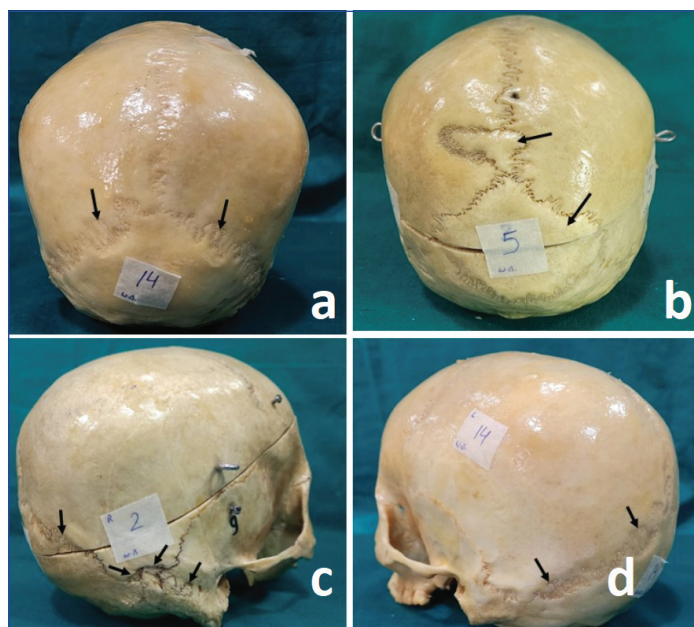
Exclusion criteria: Skulls with any injury, fracture, or pathological findings were excluded from the study.

Study Procedure

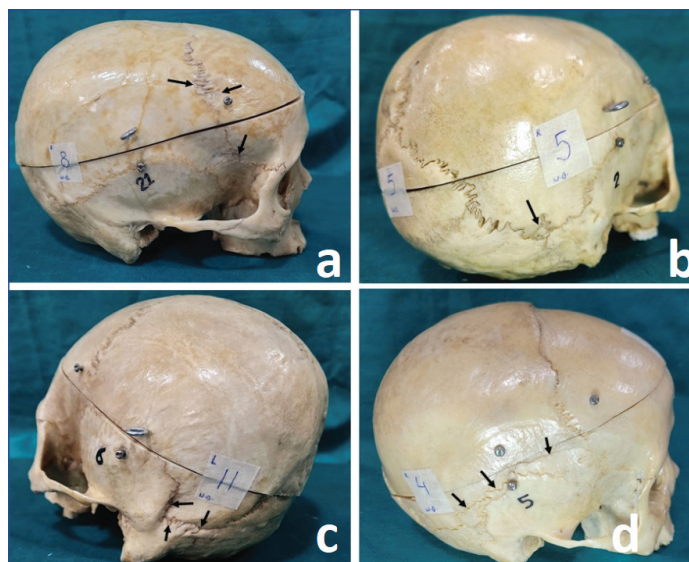
All sutures (lambdoid, coronal, sagittal, squamous, parietomastoid, occipitomastoid, sphenosquamous, sphenofrontal, sphenoparietal and metopic) on the skull were observed closely and examined systematically for the presence or absence of WBs, the metopic suture and the Inca bone [Table/Fig-1-4]. The findings were documented, and the incidences at individual sutures were noted. Photographs were taken using a Samsung SM-S908E camera.



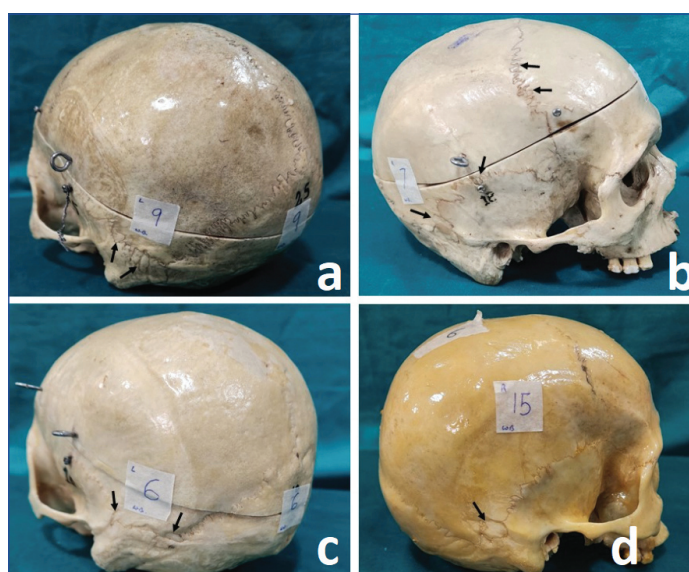
[Table/Fig-1]: a) Presence of metopic suture; b,c) Presence of WB's at sagittal suture.



[Table/Fig-2]: a) Presence of WB's at lambdoid suture; b) Sagittal suture and Inca bone; c) Lambdoid, right asterion and occipitomastoid suture; d) Left-side of lambdoid suture.



[Table/Fig-3]: a) Presence of WB's at coronal suture and right pterion; b) Right asterion; c) Left squamous, left parietomastoid and left asterion; d) Right squamous, right parietomastoid suture.



[Table/Fig-4]: a) Presence of WB's at left parietomastoid suture; b) Coronal suture and right squamous suture; c) Left squamous suture and left asterion; d) Right parietomastoid suture.

STATISTICAL ANALYSIS

The data were analysed using descriptive statistics by Statistical Package for the Social Sciences (SPSS), version 27.0, and results were expressed in terms of incidence.

RESULTS

In the present study, a total of 38 dried adult human skulls were examined for the presence of WBs, the metopic suture, and the Inca (interparietal) bone. It was observed that 21 out of the 38 skulls had multiple WBs, resulting in an incidence of 55.26%. Of these, 17 (44.74%) had no WBs, 1 (0.27%) skull had a metopic suture [Table/Fig-1a], and 1 (0.27%) skull had an Inca bone [Table/Fig-2b].

A total of 364 WBs were found in 21 skulls, with one metopic suture [Table/Fig-1a] and one Inca bone [Table/Fig-2b]. The maximum number of WBs was found in the coronal suture (number of WBs=111, incidence=30.49%) [Table/Fig-3a], followed by the lambdoid suture (number of WBs=105, incidence=28.84%) [Table/Fig-2a-d] and the left parietomastoid suture (number of WBs=30, incidence=8.24%) [Table/Fig-4a].

Pathologically, SWBs were absent in all the skulls examined. WBs were found more frequently on the left-side in the squamous, parietomastoid and occipitomastoid sutures, and on the right-side in the sphenosquamous, asterion and pterion sutures. No WBs

were found in the sphenofrontal and sphenoparietal sutures. The incidence of WBs in each skull, organised by suture, is given in [Table/Fig-5].

Suture	Incidence of Wormian Bones (WB's) n (%)
Lambdoid	105 (28.85)
Coronal	111 (30.49)
Sagittal	10 (2.75)
Right squamous	13 (3.57)
Left squamous	15 (4.12)
Right parietomastoid	22 (6.04)
Left parietomastoid	30 (8.24)
Right occipitomastoid	13 (3.57)
Left occipitomastoid	14 (3.85)
Right sphenosquamous	2 (0.55)
Left sphenosquamous	1 (0.27)
Right sphenofrontal	0
Left sphenofrontal	0
Right sphenoparietal	0
Left sphenoparietal	0
Right asterion	7 (1.92)
Left asterion	4 (1.10)
Right pterion	4 (1.10)
Left pterion	3 (0.82)
Lambda	8 (2.20)
Metopic	1 (0.27)
Inca	1 (0.27)

[Table/Fig-5]: Incidence of presence of Wormian Bones (WB's) in different sutures.

be lost during putrefaction, potentially giving the appearance of entry or exit gunshot wounds, especially in postmortem cases. The presence of WBs may lead to misdiagnosis, which can delay or alter treatment [1].

In the present study, the overall incidence of WBs was 55.26% (21/38 skulls). The maximum number of WBs was observed along the coronal suture, as opposed to the lambdoid suture, in contrast to previous studies [2]. The total Incidence (I) found in the present study is closely aligned with the study conducted by Atoni AD et al., (I=55.9%), while the incidence of WBs at the lambdoid suture (I=28.84%) closely corresponds with the study by Goyal N et al., (I=28.89) [1,9]. According to previous studies, the incidence of sutural bones/WBs ranged from 13.2-59.3% [10,11]. In the present study, there was an incidence of 55.26%, which falls within the range of previous studies [Table/Fig-6] [1,3,5,9-20]. The incidence of WBs at the lambdoid suture in the present study (I=28.84%) aligned with that of previous studies, which ranged from 12.5-72.7% [10,12].

The incidence of WBs at the coronal suture ranged from 2.42-8%, while the present study showed an incidence of 30.41%, which is higher than the incidences reported in previous studies [5,13]. The incidence of the metopic suture and Inca bone in previous studies ranged from 0.61-2.66% and from 1.315-8.8%, respectively [9,13-15]. In contrast, the present study found an incidence of 0.27% for both, which is lower than the incidences reported in previous studies.

The present study found that the incidence of WBs was highest at the coronal suture and second highest at the lambdoid suture, whereas previous studies reported the highest incidence at the lambdoid suture.

Year	Author	Place of study	Sample size	Incidence of Wormian Bones (WB's) in various sutures (%)				Incidence of Wormian Bones (WB's)
				Lambdoid	Coronal	Metopic	Inca	
2024	Shadlinski VB and Abdullayev AS, [16]	Azerbaijan	200	-	-	-	1.5	-
2024	Aragão JA et al., [17]	Brazil	1	88.9	-	-	-	-
2023	Ogut E and Yildirim FB, [18]	Turkey	58	43.19	-	-	-	52.72
2021	Li JH et al., [19]	China	285	78.57	-	10.18	3.85	63.86
2021	Atoni AD et al., [9]	Nigeria	34	32.4	5.9	-	8.8	55.9
2021	Jyothi N et al., [10]	Puducherry, India	128	12.5	-	-	5.4	13.2
2020	Ratnaningrum SD [12]	Indonesia	69	72.7	-	-	2.9	15.9
2019	Goyal N et al., [1]	Haryana, India	147	28.89	6.12	-	-	35.3
2017	Diwan RK et al., [20]	Lucknow, India	90	47.77	4.44	-	-	38.88
2017	Ghosh SK et al., [13]	Kolkata, India	120	53.33	2.42	0.61	-	45
2015	Cirpan S et al., [11]	Turkey	150	56.5	4.8	-	-	59.3
2011	Khan AA et al., [5]	Malaysia	25	-	8	-	-	28
2010	Marathe RS et al., [15]	Wardha, India	380	-	-	-	1.315	-
1986	Pal GP et al., [3]	Gujarat, India	370	37.4	-	-	-	-
1979	Agarwal SK et al., [14]	Kanpur, India	1276	-	-	2.66	-	-
2024	Present study	Dehradun, India	38	28.84	30.41	0.27	0.27	55.26

[Table/Fig-6]: Comparison of similar studies with the present study [1,3,5,9-20].

DISCUSSION

In the present study, the maximum number of WBs found in a single skull was 37, while the minimum was 6, with one skull having a metopic suture and one having an Inca bone. WBs usually occur in the sutures separating the flat bones that constitute the neurocranium of the skull and are present in both normal and pathological skulls. To be classified as pathologically significant, SWBs should be more than 10 in number, with a size greater than 6x4 mm, arranged in a mosaic pattern [8]. Small WBs may

Limitation(s)

The sample size of the present study was small, and the age and sex of the subjects were unknown. Therefore, further studies are needed with a larger sample size that includes known age and sex.

CONCLUSION(S)

The present study demonstrated an overall incidence of WBs at 55.26%, with an incidence of 28.84% at the lambdoid suture and 30.41% at the coronal suture. The incidences of both the metopic

suture and the Inca bone were found to be 0.27%. Knowledge of WBs is important as their presence can mimic a cranial fracture due to trauma and brittle bones.

REFERENCES

- [1] Goyal N, Garg A, Kumar Y. Incidence and medicolegal significance of wormian bones in human skulls in North India Region. *Int J Appl Basic Med Res.* 2019;9(3):165-168.
- [2] Reverón RR. Anatomical classification of sutural bones. *MOJ Anat Physiol.* 2017;3(4):130-31.
- [3] Pal GP, Bhagwat SS, Routal RV. A study of sutural bones in Gujarati (Indian) crania. *Anthropol Anz.* 1986;44(1):67-76.
- [4] Shapiro R, Robinson F. The os incae. *AJR Am J Roentgenol.* 1976;127(3):469-71.
- [5] Khan AA, Asari MA, Hassan A. Unusual presence of Wormian (sutural) bones in human skulls. *Folia Morphol (Warsz).* 2011;70(4):291-94.
- [6] Cremin B, Goodman H, Spranger J, Beighton P. Wormian bones in osteogenesis imperfecta and other disorders. *Skeletal Radiol.* 1982;8(1):35-38.
- [7] Sanchez T, Stewart D, Walvick M, Swischuk L. Skull fracture vs. accessory sutures: How can we tell the difference? *Emerg Radiol.* 2010;17(5):413-18.
- [8] Bellary SS, Steinberg A, Mirzayan N, Shirak M, Tubbs RS, Cohen-Gadol AA, et al. Wormian bones: A review. *Clinical Anatomy.* 2013;26(8):922-27.
- [9] Atoni AD, Tabowei UL, Francis DAU, John AO, Oboro-Aye W. The frequency and topographical distribution of sutural bones in adult dry skulls. *European Journal of Biomedical and Pharmaceutical Sciences.* 2021;8(9):83-87.
- [10] Jyothi N, Kumar S, Muraleedharan A, Gunasegaran JP, Devi R. The morphometric analysis of accessory sutural bones with an emphasis on association with parietal emissary foramina. *International Journal of Cadaveric Studies and Anatomical Variations.* 2022;2(2):42-46.
- [11] Cirpan S, Aksu F, Mas N. The incidence and topographic distribution of sutures including wormian bones in human skulls. *J Craniofac Surg.* 2015;26(5):1687-90.
- [12] Ratnaningrum SD. Identification of sutural bones in Indonesian skulls. *Translational Research in Anatomy.* 2020;18:100061.
- [13] Ghosh SK, Biswas S, Sharma S, Chakraborty S. An anatomical study of wormian bones from the eastern part of India: Is genetic influence a primary determinant of their morphogenesis? *Anat Sci Int.* 2017;92(3):373-82.
- [14] Agarwal SK, Malhotra VK, Tewari SP. Incidence of the metopic suture in adult Indian crania. *Acta Anat (Basel).* 1979;105(4):469-74.
- [15] Marathe RR, Yogesh AS, Pandit SV, Joshi M, Trivedi GN. Inca-Interparietal bones in neurocranium of human skulls in central India. *J Neurosci Rural Pract.* 2010;1(1):14-16.
- [16] Shadlinski VB, Abdullayev AS. The Interparietal (INCA) Bones: The cranioscopic and craniometric investigation. *Naturalista Campano.* 2024;28(1):2313-23.
- [17] Aragão JA, de Oliveira RF, de Sousa Silva SO, Riffel LI, Aragão ICS, Aragão FMS, et al. Multiple wormian bones in the lambdoid suture: A report of rare occurrence. *Brazilian Journal of Case Reports.* 2024;4(4):141-49.
- [18] Ogut E, Yildirim FB. Wormian bone types: Investigating their appearance, correlation to sex, population affinity, and clinical syndromes. *Egypt J Forensic Sci.* 2023;13(19):01-12.
- [19] Li JH, Chen ZJ, Zhong WX, Yang H, Liu D, Li YK. Anatomical characteristics and significance of the metopism and Wormian bones in dry adult-Chinese skulls. *Folia Morphol (Warsz).* 2023;82(1):166-75.
- [20] Diwan RK, Verma RK, Pankaj AK, Rani A, Tomar S, Sehgal G, et al. Study of Wormian bones in north Indian population. *J Anat Soc India.* 2017;66:S52.

PARTICULARS OF CONTRIBUTORS:

1. Postgraduate Resident, Department of Anatomy, Government Doon Medical College, Dehradun, Uttarakhand, India.
2. Associate Professor, Department of Anatomy, Government Doon Medical College, Dehradun, Uttarakhand, India.
3. Postgraduate Resident, Department of Anatomy, Government Doon Medical College, Dehradun, Uttarakhand, India.
4. Postgraduate Resident, Department of Anatomy, Government Doon Medical College, Dehradun, Uttarakhand, India.
5. Postgraduate Resident, Department of Anatomy, Government Doon Medical College, Dehradun, Uttarakhand, India.
6. Postgraduate Resident, Department of Anatomy, Government Doon Medical College, Dehradun, Uttarakhand, India.
7. Assistant Professor, Department of Anatomy, Government Doon Medical College, Dehradun, Uttarakhand, India.
8. Professor and Head, Department of Anatomy, Government Doon Medical College, Dehradun, Uttarakhand, India.

NAME, ADDRESS, E-MAIL ID OF THE CORRESPONDING AUTHOR:

Dr. Jolly Agarwal,
Associate Professor, Department of Anatomy, Government Doon Medical College,
Dehrakhas, Patel Nagar, Dehradun-248001, Uttarakhand, India.
E-mail: drjolly21177@gmail.com

PLAGIARISM CHECKING METHODS: (Jain H et al.)

- Plagiarism X-checker: Apr 30, 2024
- Manual Googling: Jul 19, 2024
- iThenticate Software: Jul 23, 2024 (16%)

ETYMOLOGY: Author Origin

EMENDATIONS: 8

AUTHOR DECLARATION:

- Financial or Other Competing Interests: None
- Was Ethics Committee Approval obtained for this study? No
- Was informed consent obtained from the subjects involved in the study? No
- For any images presented appropriate consent has been obtained from the subjects. NA

Date of Submission: **Apr 29, 2024**

Date of Peer Review: **Jun 05, 2024**

Date of Acceptance: **Jul 24, 2024**

Date of Publishing: **Sep 01, 2024**