

Variable Anatomical Presentation of Testicular Veins: A Cross-sectional Study

SUSHMA DARIPELLI¹, ROHINI MOTWANI², SIPRA ROUT³, MRUDULA CHANDRUPATLA⁴, T BHAVANI⁵

ABSTRACT

Introduction: The anatomy of gonadal veins is of growing importance, with an increased number of laparoscopic and open intra-abdominal surgical procedures. Gonadal veins display great variability concerning their course, number, and termination site.

Aim: To explore the possible anatomical variations in the course and termination pattern of testicular veins.

Materials and Methods: A cross-sectional study was conducted on 35 human male cadavers in Gandhi Medical College, Secunderabad, Telangana, India and All India Institute of Medical Sciences (AIIMS), Bibinagar, Telangana, India, from 2019-2021. The course numbers and drainage pattern of testicular veins were analysed for any anatomical variations.

Results: Two out of the 35 (5.71%) cases had shown multiple testicular veins. One case showed quadruple testicular veins with two oblique communicating veins on the right side and double left testicular veins on the left side. In another case, double right testicular veins with a single vein on the left side. However, no significant variations of arteries were noted in any of these cases.

Conclusion: Detailed knowledge of variable presentations of testicular veins is necessary for vascular surgeons, urologists, nephrologists, and radiologists in safeguarding these veins intraoperatively and also, reducing any postoperative vascular complications.

Keywords: Anatomical variation, Nephrologist, Oblique communicating branch, Testicular vein, Vascular complications

INTRODUCTION

Gonadal (testicular and ovarian) veins drain the gonads (testis and ovaries) and are asymmetric anatomically. About 15-20 veins appear from the posterior border of the testis and epididymis and unite to form several highly anastomotic channels surrounding the testis, known as the pampiniform plexus which forms the bulk of the spermatic cord [1]. This vascular arrangement means, that counterflowing arteries and veins are separated only by the thickness of their vascular walls, permitting the exchange of heat and small molecules and facilitating the maintenance of lower testicular temperature [2]. The pampiniform plexus ascends anterior to the ductus deferens and is drained by 3-4 veins in the inguinal canal. The veins enter the abdomen through the Deep Inguinal Ring (DIR) and coalesce into a single testicular vein at variable levels [3]. The right testicular vein drains into the inferior vena cava directly on its right anterolateral aspect at an acute angle, about 2 cm inferior to the Left Renal Vein (LRV) in adults; occasionally, it drains into the right renal vein [4]. The left testicular vein terminates in the LRV. Both these veins may be replaced by multiple vessels in the lower abdomen and sometimes, remain double as far as their termination. Of these two gonadal veins, the left is more prone to develop venous incompetence [3].

Variations in the number, course, and place of termination of the gonadal vein are ascribed to numerous clinical diseases such as varicocele and pelvic congestion syndrome [5]. Commonly reported variations of these veins include, bifurcation along with accessory renal vein [6,7], duplication [8], variations at origin and termination [9], and testicular arterio-venous anastomosis [10]. Variations of gonadal veins could indicate an abnormal complex event during their embryonic development. Variations in their origin and course have been linked to a variety of associated vascular and developmental disorders of the kidneys. Further, the lateral mesonephric branches of the dorsal aorta also supply blood to the kidneys and gonads [11]. This associated anomaly can be explained on the basis of their genesis from the common intermediate mesoderm of the mesonephric crest.

The gonadal vein has been described as a straightforward and safe way to lengthen the blood vessels available in a living donor for reconstruction. The ability to identify vascular abnormalities will aid radiologists and surgeons in recognising and protecting these veins, which play an important role in thermoregulation, and is potential for the effective functioning of the testis. Thus, an in-depth knowledge of all possible embryological variations of the gonadal vessels shown in a variable presentation in numbers or course and the draining pattern is significant for surgeons, urologists, gynaecologists, and radiologists for managing the cases adequately [12].

The present study was conducted with the aim to explore the testicular veins for their variation, course, and termination pattern.

MATERIALS AND METHODS

The present cross-sectional study was carried out in the Department of Anatomy, Gandhi Medical College, Secunderabad, Telangana, and AIIMS, Bibinagar, Telangana, India, after obtaining the permission of the Institutional Ethical Committee IE: AIIMS/BBN/IEC/NOV/2022/232.

Inclusion criteria: Only properly embalmed, adult male cadavers with an age range between 45-80 years, with clear visualisation of retroperitoneal structures on dissection were included.

Exclusion criteria: The cadavers with any surgeries performed in the retroperitoneal area involving testicular veins were excluded.

Study Procedure

A total of 35 male cadavers were dissected. The dissection steps were followed as per Cunningham's Manual of Practical Anatomy [13]. The abdominal cavity was opened, and the retroperitoneal structures were exposed. Fine dissection was done by removing all the connective tissue around the gonadal veins to get a clear field of vision.

The following morphological variations were observed on both the sides:

- Number of the gonadal veins on both the sides.
- Their site of drainage.

- Angle of drainage of gonadal veins of both the sides (oblique/perpendicular).
- Any associated anomalies related to arteries were also noted on both the sides.

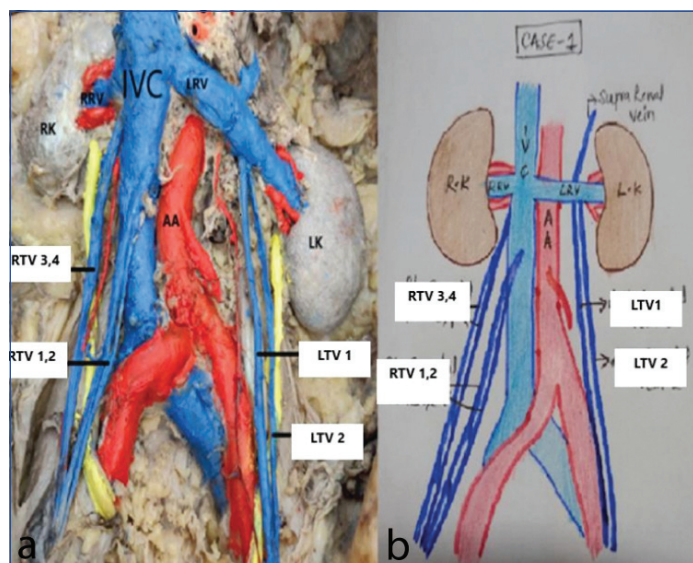
STATISTICAL ANALYSIS

As authors were not comparing both sides and have qualitative data, authors did not use any software. However, the prevalence of variations observed was expressed in percentage.

RESULTS

Out of 35 formalin preserved male cadavers, 2 (5.7%) male cadavers had variations in the testicular veins. Rest all 33 (94.2%) showed single testicular vein on either side.

Bilateral multiple gonadal veins were observed in one cadaver while other showed double gonadal veins. In one cadaver, there were four veins on the right side and two veins on the left side. The quadruple testicular veins on the right side were seen emerging out from the DIR. The two medial right testicular veins followed each other connected by an oblique communicating vein between them [Table/Fig-1a]. Later, they joined to form a single testicular vein, ahead of terminating into Inferior Vena Cava (IVC) onto its ventral surface at oblique angulation. The two lateral testicular veins followed the same pattern as that of medial ones, but they terminated at about 0.5 cm below the termination of the right renal vein with oblique angulation [Table/Fig-1a]. On the left side, double testicular veins were noticed following each other, without any connecting vein and drained separately into the middle of the LRV at the right angle [Table/Fig-1a]. The schematic representation has been shown in [Table/Fig-1b].

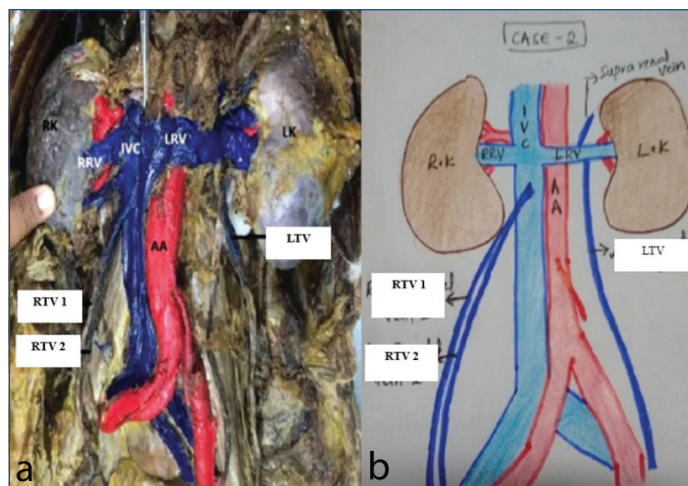


[Table/Fig-1]: a) Dissection image showing quadruple right testicular vein and double left testicular vein draining into inferior vena cava and left renal vein respectively; b) Schematic diagram of 1a.
IVC: Inferior vena cava; AA: Abdominal aorta; RTV: Right testicular vein; LTV: Left testicular vein; RRV: Right renal vein; LRV: Left renal vein; RK: Right kidney; LK: Left kidney

In the second case, we observed double testicular veins on the right side with a single testicular vein on the left side. The double testicular veins on the right side joined to form a single vein that drained into the IVC, about 2 cm below the opening of the right renal vein, on its ventral surface with an oblique angulation. The single gonadal vein on the left side terminated into the LRV [Table/Fig-2a]. The schematic representation is shown in [Table/Fig-2b]. The testicular arteries were found to have a normal origin, termination, and course on both sides. The authors could not find any other anomalies of other blood vessels nearby.

DISCUSSION

Anatomical knowledge of the gonadal vessels and their variations is vital [14,15]. Studies have shown that complications, which

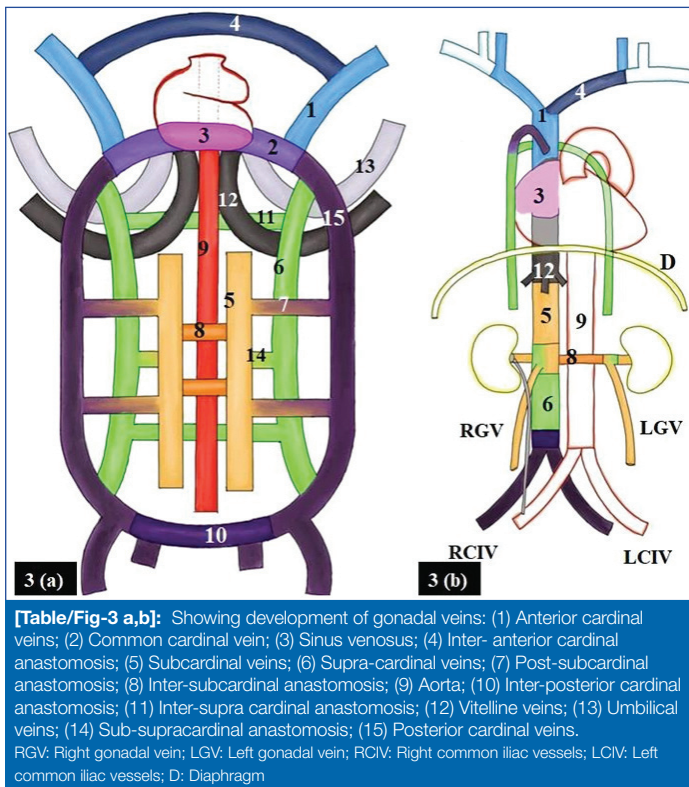


[Table/Fig-2]: a) Dissection image showing double right testicular vein and single left testicular vein draining into inferior vena cava and left renal vein respectively; b) Schematic diagram of 2a.
IVC: Inferior vena cava; AA: Abdominal aorta; RTV: Right testicular vein; LTV: Left testicular vein; RRV: Right renal vein; LRV: Left renal vein; RK: Right kidney; LK: Left kidney

usually arise during laparoscopic surgeries of the male abdomen and pelvis, are mostly the result of unfamiliar anatomical structures in the operative field [16]. Hence, awareness of the variations of the gonadal vessels, such as those being reported here, becomes important during the above mentioned surgical procedures, which would help surgeons, urologists, gynaecologists, and radiologists to prevent unforeseen complications. The testicular veins express significant anatomical inconsistency in their formation, anastomosis, number, and drainage pattern [17-19]. Testicular veins are typically singular on one or the other side however, they can be double, triple, or quadruple on one or both sides. In some cases, non-existent testicular veins is associated with agenesis of the testis [20]. Nayak SB and Kodimajalu Vasudeva S, stated that dysplasia of the subcardinal venous system causes triplication of the testicular vein, which alters the drainage pattern of the testicular veins, as it causes difficulty during renal transplant surgeries, varicocelectomy, and other surgeries that are closely related to the testicular veins [19]. In present study, none of the cadavers showed any variations in relation to testicular or ovarian arteries on any side, although Padur AA and Kumar N, have observed associated variations in testicular arteries [21].

Embryological basis and significance: Gonadal (testicular or ovarian) veins develop, in close relation to the IVC and renal vein development. Complex venous channels are involved in their development which undergoes anastomosis, regression, and extensive remodelling of three pairs of venous channels which include posterior cardinal, subcardinal, and supra-cardinal. The subcardinal and supra-cardinal veins are bilaterally symmetrical and develop in the body wall, medial to the posterior cardinal veins. These two venous channels anastomose bilaterally and lead to the formation of the renal segment of IVC [22]. The caudal part of the subcardinal veins forms the gonadal veins. The right subcardinal vein contributes to the development of IVC, hence, the right gonadal vein terminates into IVC. The left subcardinal vein contributes to the development of the LRV. Hence, the left gonadal vein terminates into the LRV [23]. The schematic representation has been shown in [Table/Fig-3a,b]. Variations of the gonadal veins are usually caused by dysplasia of the subcardinal veins, during 7-8 weeks of embryonic development [24]. Dysplasia of the subcardinal venous system could be the possible explanation for the quadruplication and duplication of the testicular vein in the current study.

In the present study, variations were observed only in the testicular veins while arteries were found normal. Asala S et al., in their study, observed variations in the gonadal vessels more commonly on the left



[Table/Fig-3 a,b]: Showing development of gonadal veins: (1) Anterior cardinal veins; (2) Common cardinal vein; (3) Sinus venosus; (4) Inter- anterior cardinal anastomosis; (5) Subcardinal veins; (6) Supra-cardinal veins; (7) Post-subcardinal anastomosis; (8) Inter-subcardinal anastomosis; (9) Aorta; (10) Inter-posterior cardinal anastomosis; (11) Inter-supra cardinal anastomosis; (12) Vitelline veins; (13) Umbilical veins; (14) Sub-supracardinal anastomosis; (15) Posterior cardinal veins. RGV: Right gonadal vein; LGV: Left gonadal vein; RCIV: Right common iliac vessels; LCIV: Left common iliac vessels; D: Diaphragm

side [9]. In the present study, the testicular veins showed duplication on both sides, bilaterally. A study reported by Mazengenya P noticed variation in the draining pattern of the quadruple testicular vein on the right side. One drained into the subcostal vein, while the other two veins joined shortly before terminating into the right renal vein. Another one was terminating into the anterior aspect of the IVC; on the other hand, the double testicular veins on the left side seen terminating into the LRV after joining [25]. In yet another study, authors have reported a prevalence of duplication of testicular veins in 5% of cases on right side whereas in left side, 2 veins in 15%, 3 veins in 2%, and 4 veins in 1% of the cases [26]. Balkund K and Praveen K in their study reported duplication of right testicular vein in 3.3% [27]. In a previous study, the variations of the gonadal veins were more commonly reported on the left side [28]. Duques P et al., in their study reported presence of a single gonadal (testicular or ovarian) vein in 85.2% and duplication in 8.8% of cases [29]. The current study has shown a unique variation of quadruple testicular veins with two oblique communicating veins between them, which finally drained into the IVC on the right side with duplication of testicular veins on the left side. This is a rare occurrence, that has not been reported in any of the previous studies so far.

Although very few studies have observed duplication of gonadal veins, quadrupling of any gonadal vein is extremely rare in the literature [Table/Fig-4] [8,9,30,31]. Thus, it should be taken care of by surgeons keeping it in mind, while dealing with surgeries of the posterior abdominal wall or pelvis. Further care should be taken during preoperative vascular evaluation, to avoid surgical complications intraoperatively, as well as, postoperatively by detecting such an anomaly beforehand.

S. No.	Study	Type of cadaveric study	Side	Number of veins				Communicating vein
				Single	Double	Triple	Quadruple	
1	Favorito LA et al., Brazil (2007) [30]	Adult (cadaveric study)	Right	85	15	-	-	Absent
			Left	82	15	2	1	
2	Favorito LA et al., Brazil (2007) [30] (foetal cadaveric study)	Foetal (cadaveric study)	Right	24	-	-	-	Absent
			Left	16	8	-	-	

3	Kara T et al., Turkey (2021) [8]	Adult (cadaveric study)	Right	99	2				Absent
4	Asala S et al., South Africa (2001) [9]	Adult (cadaveric study)	Right	150					Absent
			Left	144	6				
5	Gupta R et al., India [31] 2015	Adult (cadaveric study)	Right		2				Absent
			Left		12				
6	Present study	Adult (cadaveric study)	Right	33	1	-	1		Present
			Left	34	1	-	-		

[Table/Fig-4]: Comparison between findings of gonadal veins observed in other studies [8,9,30,31].

Limitation(s)

The variations in testicular veins are uncommon and do not follow any particular pattern. The present study mainly tried to concentrate on exploration of anatomical variations on cadavers, though, the number of cadavers was small to comment on significant prevalence pattern of variations seen, bilaterally. Further substantiation can be made with radiological studies in future studies.

CONCLUSION(S)

The anatomy of the gonadal veins has assumed much importance with the development of advanced operative techniques within the abdominal cavity for operations such as varicocele, undescended testes, and renal transplantation. Knowledge of all possible variations of gonadal vessels, as well as, a proclivity for such occurrences specific to any gender, may help to limit vascular complications during surgical procedures. The present study would add to the spectrum of possible anomalies of gonadal veins, which is of utmost practical importance for urologists, surgeons, and radiologists, while dealing with such cases.

REFERENCES

- [1] Snell R. Clinical Anatomy. Lippincott Williams & Wilkins. ISBN: 0781743168.
- [2] Harrison RJ. The vascular supply to the human testis. *J Anat.* 1949;83(Pt 1):61. PMID: 18224822.
- [3] Gray Anatomy. Chapter 76- Male reproductive system. 41st edition. Elsevier; 2015. Pp. 1273-1275.
- [4] Barber B, Horton A, Patel U. Anatomy of the origin of the gonadal veins on CT. *J Vasc Interv Radiol.* 2012;23(2):211-15.
- [5] Itoh M, Moriyama H, Tokunaga Y, Miyamoto K, Nagata W, Satriotomo I, et al. Embryological consideration of drainage of the left testicular vein into the ipsilateral renal vein: analysis of cases of a double inferior vena cava. *Int J Androl.* 2001;24(3):142-52.
- [6] Nayak SB, Padur AA, Kumar N, Reghunathan D. Terminal bifurcation and unusual communication of left testicular vein with the left suprarenal vein. *J Vasc Bras.* 2017;16(2):174-77.
- [7] Sushma D, Bhavani T, Vinodini. Variant anatomy of renal vein-a rare scenario in the cadaveric study. *International Journal of Science and Research (IJSR).* 2019;8(7):516-18.
- [8] Kara T, Younes M, Erol B, Karcaaltincaba M. Evaluation of testicular vein anatomy with multidetector computed tomography. *Surg Radiol Anat.* 2012;34(4):341-45.
- [9] Asala S, Chaudhary SC, Masumbuko-Kahamba N, Bidmos M. Anatomical variations in the human testicular blood vessels. *Ann Anat.* 2001;183(6):545-49.
- [10] Nayak BS, Rao KM, Shetty SD, Sirasanagandla SR, Kumar N, Guru A. Terminal bifurcation of the right testicular vein and left testicular arterio-venous anastomosis. *Kathmandu Univ Med J (KUMJ).* 2013;11(42):168-70.
- [11] Arey LB. Developmental anatomy. A textbook and laboratory manual of embryology, 6th edition, WB Saunders Co., Philadelphia, London, 1960;382-84.
- [12] Bandopadhyay M, Saha A. Three rare variations in the course of the gonadal artery. *Int J Morphol.* 2009;27(3):655-58.
- [13] Romanes GJ. Cunningham's manual of practical anatomy. In: The abdomen; 15th Edition, vol 2, Oxford University Press, New York, Tokyo. 142-53.
- [14] Phalgunan V, Mugunthan N, Rani DJ, Anbalagan J. A study of renal and gonadal vein variations. *NJCA.* 2012;1(3):125-28.
- [15] Dhar P, Lal K. Main and accessory renal arteries--a morphological study. *Ital J Anat Embryol.* 2005;110(2):101-10.
- [16] Brohi RA, Sargon MF, Yener N. High origin and unusual suprarenal branch of a testicular artery. *Surg Radiol Anat.* 2001;23(3):207-08.
- [17] Wishahi MM. Anatomy of the venous drainage of the human testis: Testicular vein cast, microdissection and radiographic demonstration. A new anatomical concept. *Eur Urol.* 1991;20(2):154-60.
- [18] Xue HG, Yang CY, Ishida S, Ishizaka K, Ishihara A, Ishida A, et al. Duplicate testicular veins accompanied by anomalies of the testicular arteries. *Ann Anat.* 2005;187(4):393-98.

- [19] Nayak SB, Kodimajalu Vasudeva S. Triple right testicular veins and their variant termination and communications. *Heliyon*. 2020;6(9):e05014.
- [20] Glickman MG, Weiss RM, Itzhak Y. Testicular venography for undescended testes. *AJR Am J Roentgenol*. 1977;129(1):67-70.
- [21] Padur AA, Kumar N. Unique variation of the left testicular artery passing through a vascular hiatus in renal vein. *Anat Cell Biol*. 2019;52(1):105-07.
- [22] Rudloff U, Holmes RJ, Prem JT, Faust GR, Moldwin R, Siegel D. Meso-aortic compression of the left renal vein (nutcracker syndrome): Case reports and review of the literature. *Ann Vasc Surg*. 2006;20(1):120-29.
- [23] Sadler TW. *Langman's Medical Embryology*. Twelfth edition, Lippincott Williams & Wilkins, Wolters Kluwer Business, Philadelphia, 2012.
- [24] Carlson BM. The development of the circulatory system, in: BM Carlson (Ed.), *Patten's Foundations of Embryology*, Mac-Graw-Hill, New York, pp. 1988; 586-627.
- [25] Mazenganya P. Multiple variations of the renal and testicular vessels: Possible embryological basis and clinical importance. *Surg Radiol Anat*. 2016;38(6):729-33.
- [26] Lechter A, Lopez G, Martinez C, Camacho J. Anatomy of the gonadal veins: A reappraisal. *Surgery*. 1991;109(6):735-39.
- [27] Balkund K, Praveen K. Anatomical variation of testicular veins and its embryological importance. *Int J Anat Res*. 2018;6(2.2):5268-71.
- [28] Nallikuzhy TJ, Rajasekhar SSSN, Malik S, Tamgire DW, Johnson P, Aravindhan K. Variations of the testicular artery and vein: A meta-analysis with proposed classification. *Clin Anat*. 2018;31(6):854-69.
- [29] Duques P, Rodrigues JR, Silva Neto FB, S. Neto EM, Tolêdo ES de. Anatomical study of the left renal vein of Brazilian human cadavers. *Medicine (Ribeirão Preto)* [Internet]. June 30, 2002 [cited November 30, 2021];35(2):184-91. Available at: <https://www.revistas.usp.br/rmrp/article/view/821>.
- [30] Favorito LA, Costa WS, Sampaio FJ. Applied anatomic study of testicular veins in adult cadavers and in human fetuses. *Int Braz J Urol*. 2007;33(2):176-80.
- [31] Gupta R, Gupta A, Aggarwal N. Variations of gonadal veins: Embryological prospective and clinical significance. *J Clin Diagn Res*. 2015;9(2):AC08-10.

PARTICULARS OF CONTRIBUTORS:

1. Assistant Professor, Department of Anatomy, Gandhi Medical College, Hyderabad, Telangana, India.
2. Associate Professor, Department of Anatomy, AIIMS, Bibinagar, Telangana, India.
3. Associate Professor, Department of Anatomy, AIIMS, Bhubaneswar, Odisha, India.
4. Additional Professor and Head, Department of Anatomy, AIIMS, Bibinagar, Telangana, India.
5. Assistant Professor, Department of Anatomy, Government Medical College, Sangareddy, Telangana, India.

NAME, ADDRESS, E-MAIL ID OF THE CORRESPONDING AUTHOR:

Sushma Daripelli,
Assistant Professor, Department of Anatomy, Gandhi Medical College,
Musheerabad-500003, Telangana, India.
E-mail: sushma.tulips@gmail.com

PLAGIARISM CHECKING METHODS: [\[Jain H et al.\]](#)

- Plagiarism X-checker: Jul 20, 2022
- Manual Googling: Jan 17, 2023
- iThenticate Software: Jan 20, 2023 (20%)

ETYMOLOGY: Author Origin**AUTHOR DECLARATION:**

- Financial or Other Competing Interests: None
- Was Ethics Committee Approval obtained for this study? Yes
- Was informed consent obtained from the subjects involved in the study? No
- For any images presented appropriate consent has been obtained from the subjects. NA

Date of Submission: **Jul 14, 2022**Date of Peer Review: **Sep 05, 2022**Date of Acceptance: **Jan 21, 2023**Date of Publishing: **May 01, 2023**