

# Tormenting Duck Bone in Throat- A Case Report

D BALAJI<sup>1</sup>, S RAJASEKARAN<sup>2</sup>, A RAGHVI<sup>3</sup>

(CC) BY-NC-ND

## ABSTRACT

Foreign bodies in throat is a very common entity encountered in otolaryngology practice. Out of these most common foreign bodies in adults include fish bone, mutton bone, piece of meat. Present case was the first in literature to present with duck bone stuck in throat. A 30-year-old female presented to the Ear, Nose and Throat (ENT) Outpatient Department (OPD) with history of duck meat ingestion and complaints of foreign body sensation in throat and odynophagia for a period of three days. Video laryngoscopy revealed the presence of a foreign body at the level of laryngeal inlet, just above the right vocal cord, adherent to the anterior commissure. After obtaining anaesthesia fitness on the same day, direct laryngoscopy under general anaesthesia was performed. The foreign body was visualised, found to be more adherent near the anterior commissure and was removed using microlaryngeal forceps. The patient significantly improved and was discharged. All patients who present to the Otorhinolaryngology OPD with complaints of swallowing a foreign body/bone or experiencing a foreign body sensation in the throat should be taken seriously. A lateral radiograph of the neck soft tissue may sometimes not reveal the foreign body. A video laryngoscopy examination should be done to confirm the presence and assess the site of impaction of foreign body.

**Keywords:** Cricoid, Foreign body, Larynx, Odynophagia

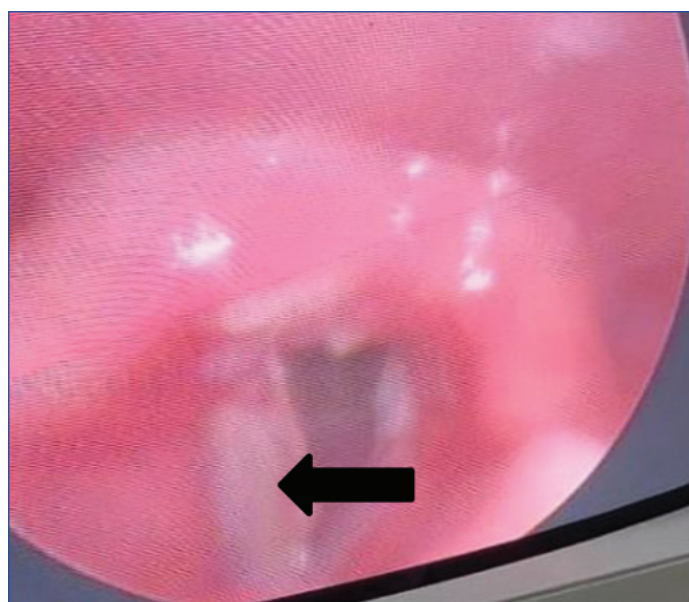
## CASE REPORT

A 30-year-old female patient presented to the Ear, Nose and Throat (ENT) Outpatient Department (OPD) with the complaints of foreign body lodgement in throat and painful swallowing for a period of three days. Patient gave a history of consumption of duck meat two days back. There was no history of change in voice, difficulty in breathing, noisy breathing. There was no history of any swelling in the neck, fever, aspiration or regurgitation. Patient was a uncontrolled diabetic for the past five years and was on irregular medications. Patient was moderately obese with a Body Mass Index (BMI) of 32.5 kg/m<sup>2</sup>. Patient had no other significant co-morbidities.

General examination showed that patient was conscious, oriented, afebrile and vital signs were stable. Patient was anaemic showing mild pallor, not icteric, no clubbing, no cyanosis, no pedal edema, no generalised lymphadenopathy. Patient was not in stridor. Systemic examination was found to be normal. Head and neck examination showed that laryngeal crepitus was blunted. Oral cavity and oropharyngeal examination was found to be normal.

The X-ray of the neck lateral view did not reveal anything significant. Videolaryngoscopy revealed the presence of a foreign body of size approximately 3×3×2 cm at the level of laryngeal inlet, just above the right vocal cord, adherent to the anterior commissure. A contact ulcer of size approximately 1×1 cm was also visualised in the right arytenoid and interarytenoid region. Right vocal cord was found to be oedematous. Mobility of both the vocal cords were normal. There was no active bleeding or blood clots. Both the pyriform fossa were normal. The base of tongue, epiglottis, vallecula, aryepiglottic fold were found to be normal [Table/Fig-1].

Routine preoperative investigations like complete haemogram, blood sugar levels, renal function tests, serology, electrolytes, urine routine analysis, echocardiogram and chest X-ray were done. The patient was found to have elevated blood sugar levels with random blood glucose values of 376 mg/dL. X-ray of the chest Anteroposterior (AP) view and X-ray of the neck AP and lateral view showed no significant changes. The patient was taken up for surgery after obtaining preanaesthetic evaluation and fitness on the



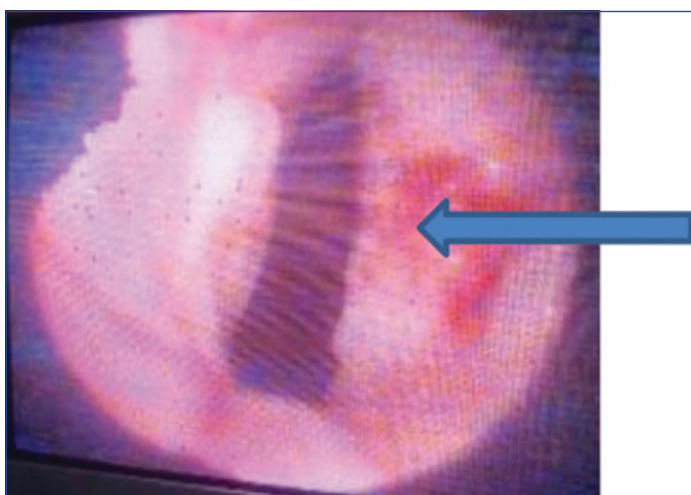
**[Table/Fig-1]:** An endoscopic view of the foreign body (duck bone) near the laryngeal inlet (black arrow).

same day. Anaesthetist was consulted and a preoperative evaluation of vocal cords were done by flexible fibreoptic laryngoscopy to decide the type of intubation to be used. The patient underwent direct laryngoscopy under general anaesthesia, the foreign body (duck bone) was visualised near the laryngeal inlet, found to be more adherent near the anterior commissure and was removed using microlaryngeal forceps [Table/Fig-2,3]. Postoperative period was uneventful.

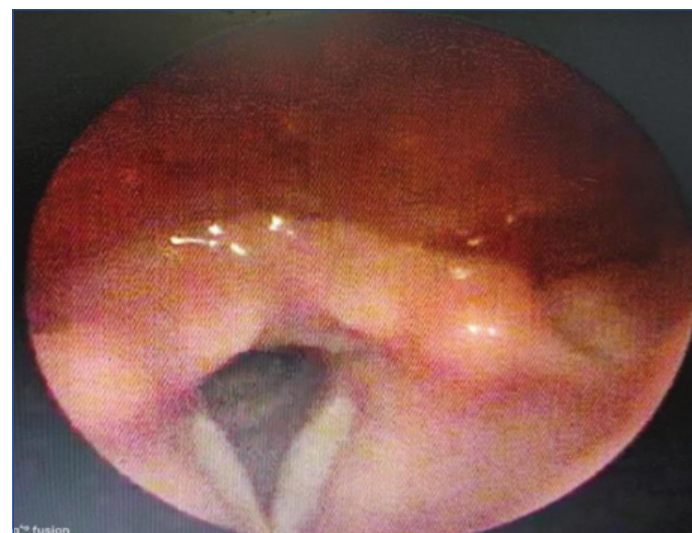
The patient was treated with intravenous antibiotics injection cefotaxime 1 gm intravenously twice daily, injection metronidazole 500 mg/100 mL thrice daily, injection dexamethasone 8 mg intravenously twice daily, injection pantoprazole 40 mg before food once daily and injection paracetamol intramuscularly for three days postoperatively. The patient was initially nil per oral, gradually started



[Table/Fig-2]: Duck bone removed from the laryngeal inlet.



[Table/Fig-3]: Postoperative image of the laryngeal inlet showing contact ulcer over right arytenoid (blue arrow).



[Table/Fig-4]: Postoperative image of the patient showing well-healed arytenoid ulcer.

on oral liquids and soft solid diet. Adequate glycaemic control was achieved by maintaining a blood glucose level charting every 8<sup>th</sup> hourly and giving insulin by physicians orders as per the blood glucose levels. The patient significantly improved, she was able to take soft solid diet from day two, symptoms were better and was discharged on day 4 after the foreign body removal. Patient came for follow-up on day 7 and she was doing better [Table/Fig-4].

## DISCUSSION

In the aerodigestive tract, Foreign Bodies (FBs) are a frequent source of morbidity and mortality across both extremes of the life span [1]. Children are more susceptible to ingesting and aspirating FBs, especially during the first six years of life [1-3]. In adults, however typically foreign body ingestion occurs while eating [4,5]. Because of a poor dentition, artificial dentures and insufficient chewing, this leads to either bone impaction or meat impaction [5,6]. Food impaction can also result from pre-existing obstructive esophageal lesions such as oesophageal (mucosal) rings, peptic or malignant esophageal strictures, or eosinophilic esophagitis [6,7].

It is more common in adults with psychiatric issues, mental retardation, inebriation caused by alcohol, trauma leading to a lowered level of awareness and compromised airway reflexes. Pin aspirations are typically easier to identify than other types of

FB aspiration because all of these inhaled FBs are radio-opaque and are easily detected by imaging of the chest [8]. Foreign objects found in the digestive tract include dentures, coins, fish bones, chopsticks, and even glass particles [9,10].

Adults most frequently consume chicken, mutton, beef and fish bones [11]. The cricopharyngeal junction is where foreign body impaction occurs most frequently. The oral cavity, oropharynx, hypopharynx and thoracic oesophagus are most common areas where FB impaction can happen. Among the organic FBs are meat bolus and bone (fish, chicken, mutton and beef meat). Dentures, money, and plastic and metallic objects are examples of inorganic FBs. In adults, it mostly happens during the sixth decade of life. Accidental ingestion of a foreign object, such as a fish bone or chicken bone, could cause it to lodge in the cervical oesophagus or hypopharynx. Food bones are typically undercalcified and difficult to see on lateral radiographs of the neck [11]. Rapid onset dysphagia when eating, being unable to finish a meal, abrupt discomfort while at rest, and otalgia are signs of a foreign body in the throat, whereas pain is less specific. Studies show that 68% of patients who had tonsil-specific discomfort correctly predict the presence of a foreign body [12,13]. The site of symptoms correctly identify the location of a foreign body. It has been proven that pooling of saliva is a reliable sign of a retained foreign body [12,13].

X-rays are not particularly sensitive to locate foreign body in the throat. As a result, both a video laryngoscopy examination in the OPD and a clinical correlation of the patient's history and symptoms should be assessed [14]. Sometimes the food bolus may get aspirated leading to airway compromise and stridor. These patients must be immediately taken up in emergency and the foreign body must be removed after securing airway. To prevent development of septicaemia, the foreign body must be located and removed as quickly as possible [15]. It must be kept in mind that soft tissue edema caused by bone impaction takes 3-12 hours to manifest and may not be visible if the patient is X-rayed right away. Since the region of the cricopharyngeus seems to be where oesophageal foreign bodies most frequently lodge, it is crucial that a lateral neck X-ray includes at least the sixth cervical vertebra [11].

If prompt diagnosis is not made then these patients might present with neck swelling, odynophagia, fever after few days. X-ray soft tissue neck can show prevertebral soft tissue swelling, features of retropharyngeal abscess [16]. It is always better to get a chest X-ray done to rule out oesophageal perforation, especially when patient complains of acute retrosternal pain and vomiting. Gas will be detected in the tissues of the neck, and a lateral image will show the trachea sliding forward. The superior mediastinum will

appear widened on chest films. On the lateral films, mediastinal emphysema, oesophageal forward displacement, and increased density of the normally translucent retrocardiac area are frequently visible [17].

## CONCLUSION(S)

In present case, the patient had a unusual bone (a duck bone) lodged in laryngeal inlet. Every patient who complains of swallowing a foreign body or feeling a foreign body in their throat, visiting the Otorhinolaryngology OPD need to be clinical examined with a video laryngoscope along with a detailed history record. In some cases, the foreign body may not always be seen on a lateral radiograph of the neck soft tissue. The foreign body should be identified and located promptly and removed either under local or general anaesthesia depending on patient age and health, general body condition, nature of foreign body and other factors.

## REFERENCES

- [1] Nandi P, Ong GB. Foreign body in the oesophagus: Review of 2394 cases. *J Br Surg*. 1978;65(1):05-09.
- [2] Gilyomaand JM, Chalya PL. Endoscopic procedures for removal of foreign bodies of the aerodigestive tract: The Bugando Medical Centre experience. *BMC Ear, Nose and Throat Disorders*. 2011;11(1):2.
- [3] Ekim H. Management of esophageal foreign bodies: A report on 26 patients and literature review. *East J Med*. 2010;15(4):21-25.
- [4] Bane A, Bekele A. Management of gastrointestinal foreign bodies using flexible endoscopy: An experience from Addis Ababa, Ethiopia. *East Cent Afr J Surg*. 2012;17:3.
- [5] Roura J, Morello A, Comas J, Ferran F, Colome M, Traserra J. Esophageal foreign bodies in adults. *J. OtoLaryngol and Its Related 243 Specialties*, vol. 52, no. 1, pg. 51-56, 1990.
- [6] George T, Andrew R. Update on foreign bodies in the esophagus: Diagnosis and management. *Current Gastroenterology Reports*. 2013;15:317.
- [7] Ambe P, Weber SA, Schauer M, Knoefel WT. Swallowed foreign bodies in adults. *Deutsches Arzteblatt Int*. 2012;109(50):869-75.
- [8] Al-Sarraf N, Jamal-Eddine H, Khaja F, Ayed AK. Headscarf pin tracheobronchial aspiration: A distinct clinical entity. *Interactive Cardiovascular and Thoracic Surgery*. 2009;9(2):187-90.
- [9] Sheng-Xi L, Hui L, Chen T, Dong Xu M. Endoscopic retrieval of an 18-cm long 253 chopstick embedded for ten months post-automutilation in the esophagus of a patient with psychosis. *World J Gastroenterol*. 2014;10:453-56.
- [10] Parajuli R. Foreign bodies in the ear, nose and throat: An experience in a tertiary care hospital in central Nepal. *Int J Otolaryngol*. 2015;19(2):121-23.
- [11] Kirkham N, English R. I have a bone stuck in my throat. *Br Med J (Clin Res Ed)*. 1984;289(6442):424-25.
- [12] Jones NS, Lannigan FJ, Salama NY. Foreign bodies in the throat: A prospective study of 388 cases. *The J Otolaryngol*. 1991;105(2):104-08.
- [13] Baraka A, Bikhazi G. Oesophageal foreign bodies. *Br Med J*. 1975;1(5957):561-63.
- [14] Stubington TJ, Kamani T. Food bolus and oesophageal foreign body: A summary of the evidence and proposed management process. *Eur Arch. Oto-Rhino-L*. 2021;278(10):3613-23.
- [15] Knight LC, Lesser TH. Fish bones in the throat. *Emerg Med J*. 1989;6(1):13-16.
- [16] Rao BT. Retro-pharyngeal abscess. *Indian J Otolaryngol*. 1950;2(1):15-20.
- [17] Adler, David & Fuller D. Traumatic perforation of the oesophagus: A review illustrated by 18 cases. *South Afr Med. J*. 1953;27(9):173-82.

### PARTICULARS OF CONTRIBUTORS:

1. Senior Resident, Department of Ear, Nose and Throat, Chettinad Academy of Research and Education, Chettinad Hospital and Research Institute, Chennai, Tamil Nadu, India.
2. Professor and Head, Department of Ear, Nose and Throat, Chettinad Academy of Research and Education, Chettinad Hospital and Research Institute, Chennai, Tamil Nadu, India.
3. Junior Resident, Department of Ear, Nose and Throat, Chettinad Academy of Research and Education, Chettinad Hospital and Research Institute, Chennai, Tamil Nadu, India.

### NAME, ADDRESS, E-MAIL ID OF THE CORRESPONDING AUTHOR:

Dr. D Balaji,  
Senior Resident, Department of Ear, Nose and Throat, Chettinad Academy of Research and Education, Chettinad Hospital and Research Institute, Chennai, Tamil Nadu, India.  
E-mail: balaji1190@gmail.com

### PLAGIARISM CHECKING METHODS: [\[Jain H et al.\]](#)

- Plagiarism X-checker: Jun 17, 2022
- Manual Googling: Aug 23, 2022
- iThenticate Software: Sep 03, 2022 (5%)

### ETYMOLOGY: Author Origin

### AUTHOR DECLARATION:

- Financial or Other Competing Interests: None
- Was informed consent obtained from the subjects involved in the study? Yes
- For any images presented appropriate consent has been obtained from the subjects. Yes

Date of Submission: **May 27, 2022**  
Date of Peer Review: **Aug 02, 2022**  
Date of Acceptance: **Sep 06, 2022**  
Date of Publishing: **Jan 01, 2023**