

A Rare Case of an Osteoid Osteoma in the Medial Cuneiform

ABDELSALAM KAK¹, MATTHEW COTCHETT², DAMIEN LAFFERTY³



ABSTRACT

Osteoid osteoma is a benign osteoblastic tumour constituting 10-20% of all benign tumours. It is rarely seen in the foot and accounts for approximately 4% of all cases. The present case was of a 23-year-old male with an osteoid osteoma in the lateral cortex of his medial cuneiform at the articulating surface. He was misdiagnosed for nine-months with initial radiographs and Magnetic Resonance Imaging (MRI) failing to diagnosis the tumour. Extensive conservative treatment failed to resolve his symptoms, although Non-Steroidal Anti-Inflammatory Drug (NSAID) provided relief. Treatment involved excising the osteoid osteoma and filling the void left from the tumour with a synthetic bone graft.

Keywords: Bone neoplasm, Bone transplantation, Foot, Tarsal bone

CASE REPORT

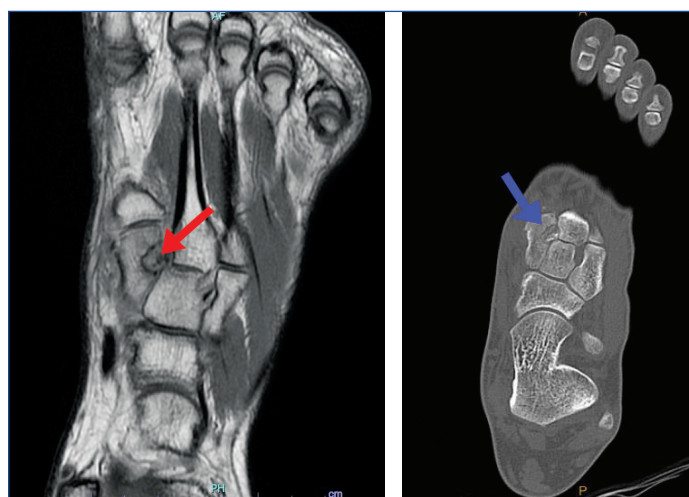A 23-year-old male patient was referred with a nine month history of non specific pain in his left midfoot region. His pain was of a gradual onset, worsen at night and following any physical activity. He initially responded well to the use of NSAIDs. The patient's medical history was unremarkable. He had no history of smoking, and neurovascular assessment was within normal limits. His surgical history included a bunionectomy of his left first metatarsophalangeal joint 24 months prior.

Upon his initial presentation to a podiatrist, he was diagnosed with a stress fracture of the medial cuneiform. He was subsequently treated with rest including a period of non weight bearing in a controlled ankle motion walking boot for six weeks followed by the application of a bone stimulator daily for two months in the region. Following failed conservative care, Magnetic Resonance Imaging (MRI) was undertaken, which reported marked bone marrow oedema of the entire medial cuneiform with a well corticated lesion within the lateral margin of the medial cuneiform- reported to be a ganglion cyst or geode [Table/Fig-1].

After a period of 36 weeks with minimal reduction in symptoms, the patient presented for a review with a podiatric surgeon. Based on the patient's history including the MRI findings and failed management, the patient was referred for a Computed Tomography (CT). The CT reported a well-circumscribed lesion at the lateral cortex of the medial cuneiform (9x8x8 mm) demonstrating a radiolucent halo and central sclerotic dot like foci which was indicative of an osteoid osteoma [Table/Fig-2]. The patient initially responded to the use of NSAIDs however conservative care failed to resolve his symptoms and surgical excision eventuated.

Following induction of the general anaesthesia, the lower extremity was draped, swabbed with betadine solution, the limbs draped accordingly and antibiotic prophylaxis (tab. cephazolin 2g) was instituted preoperatively. Preoperative analgesia (anterior ankle nerve block) of 8 mL of 0.75% ropivacaine hydrochloride solution was performed on the supine patient. Haemostasis was achieved using a mid-calf tourniquet inflated to 270 mmHg. The surgical site was exposed via a dorsal linear incision extending just beyond the margins of the medial cuneiform/intermediate cuneiform joints [Table/Fig-3].

Care was taken to protect the superficial neurovascular structures if encountered (dorsal branch of the great saphenous vein, medial dorsal cutaneous nerve, deep peroneal nerve and dorsalis pedis). Blunt dissection (using an unloaded scalpel handle and Raytec



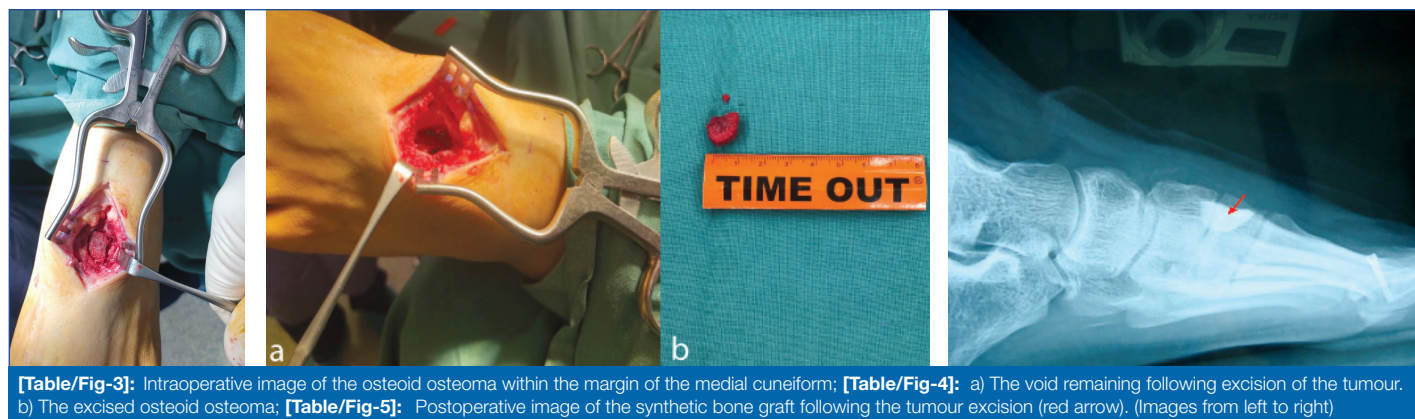
[Table/Fig-1]: Initial T1 weighted MRI imaging identifying the lesion however not identifying the benign tumour (red arrow). **[Table/Fig-2]:** A well circumscribed lesion at the lateral cortex of the medial cuneiform (measuring 9x8x8 mm). (Images from left to right)

gauze) was performed to gently move any subcutaneous fat and neurovascular structures from the surgical area. The extensor retinaculum was incised following sharp dissection of the underlying capsule, which exposed the affected region. The osteoid osteoma was identified, isolated from the surrounding medial cuneiform using a freer elevator and consequently excised [Table/Fig-4a,b].

Following the resection of the osteoid osteoma, an injectable synthetic bone substitute (Kasios-FixEx) was then used to fill the void. Care was taken not to break the lateral cortex of the medial cuneiform and not allow the synthetic bone substitute to occupy the surrounding joints.

The wound underwent layered closure using 3-0 Vicryl for capsular closure and 4-0 Monocryl for skin closure. A final local anaesthetic dorsal ankle block was administered using 9 mL of 0.75% ropivacaine hydrochloride combined with 1 mL/4 mg dexamethasone sodium phosphate solution. The foot was dressed with a multilayered compression technique and the patient was discharged in a postoperative sandal.

Postoperative imaging showed successful removal of the tumour and a stable in-situ bone graft was noted [Table/Fig-5]. Postoperative histopathology of the excised bone reported a relatively circumscribed area comprised of interanastomosing trabeculae of woven bone rimmed by prominent osteoblasts. The intertrabecular stroma showed



[Table/Fig-3]: Intraoperative image of the osteoid osteoma within the margin of the medial cuneiform; **[Table/Fig-4]:** a) The void remaining following excision of the tumour. b) The excised osteoid osteoma; **[Table/Fig-5]:** Postoperative image of the synthetic bone graft following the tumour excision (red arrow). (Images from left to right)

fibrovascular tissue, haemorrhage, hemosiderin laden macrophages and osteoclast type multinucleated giant cells. All the features were consistent with an osteoid osteoma.

Postoperative review of the patient was performed at one, two, four and 12 weeks following the osteoid osteoma excision. At 12 weeks, the patient reported a 'very much better' level of improvement on a Global Rating of Change scale [1].

DISCUSSION

Osteoid osteoma is a benign osteoblastic tumour constituting 10-20% of all benign tumours [2,3]. It is most commonly reported in long tubular bones (femur/tibia), and to a lesser extent in the mid-tibia diaphysis, phalanges and the vertebrae (some parts of the vertebrae are more common than other areas) [4]. Osteoid osteomas are rarely seen in the foot accounting for approximately 4% of all cases [2]. There have been reports involving the talus and calcaneus, although the cuneiform bones/joints are rarely involved [2,3]. Other rare locations reported include the skull, scapula, ribs, mandible and patella [4].

Similar to some other locations in the body, such as the cervical spine, the diagnosis of an osteoid osteoma in the foot can prove difficult due to the small size of the lesion and the complex anatomy of the surrounding regions. The lesion can be misdiagnosed as the nidus of the tumour may be covered up by a fibrovascular zone, reactive sclerosis or surrounding oedema [4,5]. Within the foot, radiological findings such as thickening of the cortex, bone marrow oedema and localised reactive sclerosis may delay or cause a misdiagnosis as such findings can mimic the presentation of a stress reaction of fracture [6].

Clinically, reported osteoid osteomas in the foot and ankle identify clinical symptoms similar to that which was noted in this case study. Long standing pain which was more severe during resting at night, pain unrelated to physical activity, reduction in pain following the use of NSAIDs, pain aggravated by physical activity, mild localised swelling and localised tenderness [7,8].

Typical radiographic appearance of an osteoid osteoma includes a small vascular nidus with a variable amount of peripheral sclerotic bone reaction [9]. The majority of osteoid osteomas that present in the foot are of the subperiosteal subtype meaning they exhibit minimal periosteal reaction [10]. As a result, they can be more difficult to detect causing a delay in treatment. Similar diagnostic difficulties have been reported in other cases involving the talus, distal phalanx of a middle finger as well as those in difficult juxtaarticular positions [11-13]. Histologically, the vascular nidus appears as a well-defined area consisting of interlacing, irregular bone trabeculae of varying mineralisation surrounded by osteoblasts [4].

A thin slice CT scan can effectively identify the anatomic location of the vascular nidus and surrounding bone marrow oedema without masking the features of the tumour which may occur on an MRI [14]. The poor sensitivity for diagnosing an osteoid osteoma with an MRI was apparent with this patient with initial MRI reporting the tumour to be a geode or a ganglion cyst.

Initial treatment of an osteoid osteoma typically consists of a combination of medical management and activity modification (e.g., rest and reduced weight bearing). Medical management, in particular, long term use of NSAIDs can allow for a dramatic decrease in symptoms and resolution of the disease [10,14]. However, the long-term use of NSAIDs can be inadequate and subsequent gastrointestinal complications can occur [15]. Although long term use of NSAIDs has been associated with a high incidence of side-effects, the use of a selective Cyclooxygenase (COX-2) inhibitor as a treatment alternative has successfully managed pain associated with osteoid osteomas with a reduced risk of gastrointestinal effects [16].

Several percutaneous techniques have been used for the treatment of osteoid osteomas, including trephination, ethanol injection, laser photocoagulation, and radiofrequency ablation [17]. Treatment response using these percutaneous techniques range from 83% to 92% and is comparable to reported open techniques [15,17]. Open surgical excision compared to percutaneous treatments shows little to no difference in complications or recurrence rates. For the patient, surgical excision was performed in accordance with literature due to failed reduction in symptoms with conservative care and the osteoma located within 15 mm to neurovascular structures [15].

CONCLUSION(S)

The diagnosis of an osteoid osteoma in the foot can prove difficult even with current diagnostic techniques. In this case study, the patient was misdiagnosed for nine months before receiving the appropriate care (excision of the osteoid osteoma with insertion of an in-situ bone graft). If symptomatic, an excision of an osteoid osteoma and bone graft insertion may be an effective treatment for reducing pain associated with the pathology.

REFERENCES

- [1] Kamper SJ, Maher CG, Mackay G. Global rating of change scales: A review of strengths and weaknesses and considerations for design. *J Man Manip Ther.* 2009;17(3):163-70.
- [2] Gürkan V, Orhun H, Bülbül M, Kayahan S. Osteoid osteoma of the cuboid bone: A rare cause of foot pain. *Acta Orthop Traumatol Turc.* 2011;45(1):66-69.
- [3] Moon DG, Nam KW, Hyun CL, Seo KB. Osteoid osteoma of the third metatarsal bone: A case report. *The Journal of Medicine and Life Science.* 2018;15(1):27-30.
- [4] Chai JW, Hong SH, Choi JY, Koh YH, Lee JW, Choi JA, et al. Radiologic diagnosis of osteoid osteoma: From simple to challenging findings. *Radiographics.* 2010;30(3):737-49.
- [5] Kong J, Xiao H, Liu T, Yan W, Qian M, Wen Song D, et al. The valuation of using FDG PET-CT in detecting osteoid osteoma of the cervical spine. *Clinical Spine Surgery.* 2015;28(2):67-73.
- [6] Mandell JC, Khurana B, Smith SE. Stress fractures of the foot and ankle, part 2: site-specific etiology, imaging, and treatment, and differential diagnosis. *Skeletal Radiology.* 2017;46(9):1165-86.
- [7] He H, Xu H, Lu H, Dang Y, Huang W, Zhang Q. A misdiagnosed case of osteoid osteoma of the talus: A case report and literature review. *BMC Musculoskeletal Disorders.* 2017;18(1):01-05.
- [8] Banerjee D, Eriksson K, Morris H. Arthroscopically treated intraarticular osteoid osteoma in the ankle—a report of 3 cases. *Acta Orthop.* 2005;76(5):721-24.
- [9] Dookie AL, Joseph RM. Osteoid osteoma. *StatPearls.* 2019; Nov 22.

- [10] Kitsoulis P, Mantellos G, Vlychou M. Osteoid osteoma. *Acta Orthop Belg.* 2006;72(2):119.
- [11] Andalib A, Sajadie-Khajouei S. Osteoid osteoma of distal phalanx: A rare disorder and review of literature. *J Res Med Sci.* 2013;18(3):264.
- [12] Shankman S, Desai P, Beltran J. Subperiosteal osteoid osteoma: Radiographic and pathologic manifestations. *Skeletal Radiology.* 1997;26(8):457-62.
- [13] Franceschi F, Marinozzi A, Papalia R, Longo UG, Gualdi G, Denaro E. Intra- and juxta-articular osteoid osteoma: A diagnostic challenge. *Arch Orthop Trauma Surg.* 2006;126(10):660-67.
- [14] Xarchas KC, Kyriakopoulos G, Manthas S, Oikonomou L. Hallux osteoid osteoma: A case report and literature review. *The Open Orthopaedics Journal.* 2017;11:1066-72.
- [15] Angelini A, Trovarelli G, Bertr T, Maraldi M, Haddad BI, Piraino I, et al. Treatment of osteoid osteomas of the foot: A review of 100 cases. *Clinical Research on Foot & Ankle.* 2014;2(4):01-07.
- [16] Carpintero-Benitez P, Aguirre MA, Serrano JA, Lluch M. Effect of rofecoxib on pain caused by osteoid osteoma. *Orthopedics.* 2004;27(11):1188-91.
- [17] Boscainos PJ, Cousins GR, Kulshreshtha R, Oliver TB, Papagelopoulos PJ. Osteoid osteoma. *Orthopedics.* 2013;36(10):792-800.

PARTICULARS OF CONTRIBUTORS:

1. Registrar, Australasian College of Podiatric Surgery, New South Wales, Australia.
2. Doctor, Department of Physiotherapy, Podiatry, Prosthetics, La Trobe University, Melbourne, Victoria, Australia.
3. Doctor, Australasian College of Podiatric Surgery, New South Wales, Australia.

NAME, ADDRESS, E-MAIL ID OF THE CORRESPONDING AUTHOR:

Dr. Abdelsalam Kak,
Shop 14/42B, Stockton Avenue Moorebank Shopping
Village Moorebank NSW-2170, Sydney, NSW, Australia.
E-mail: abdel.kak@gmail.com

PLAGIARISM CHECKING METHODS: [\[Jain H et al.\]](#)

- Plagiarism X-checker: Jan 22, 2021
- Manual Googling: May 18, 2021
- iThenticate Software: Jun 04, 2021 (13%)

ETYMOLOGY: Author Origin**AUTHOR DECLARATION:**

- Financial or Other Competing Interests: None
- Was informed consent obtained from the subjects involved in the study? Yes
- For any images presented appropriate consent has been obtained from the subjects. Yes

Date of Submission: **Jan 21, 2021**Date of Peer Review: **Apr 22, 2021**Date of Acceptance: **May 21, 2021**Date of Publishing: **Oct 01, 2021**