

Incidence of Inca Bones among Dry Human Skull Bones: A Study in the Medical Colleges of a District in Southern India

ANUSHA DONAPUDI¹, BORRA VIJAYANIRMALA²

ABSTRACT

Introduction: The occipital bone in the human skull consists of two parts -supraoccipital and interparietal part. Sometimes the interparietal portion of the occipital bone remains separated from the supraoccipital part by a transverse suture, resulting in the occurrence of inca bone. Sometimes in man, interparietal bone is seen as a separate bone, as a variant.

Aim: To study the incidence of inca bone and its variations in dry human skull bones.

Materials and Methods: The present osteological study was done on 230 dry human skulls taken by convenient sampling method, of both the sex and of all the age groups during one year period from August 2018 to August 2019. The skull bones were collected from Anatomy and Forensic medicine

departments of five medical colleges, both government and private medical colleges, in Krishna district, Andhra Pradesh, Southern India. Inferential statistics in terms of simple percentages were used.

Results: Among the 230 skull bones, 6 (2.6%) skulls were seen with inca bones. Out of these six skulls with interparietal bone, two skulls showed complete undivided inca bone. Incidence of inca bone was higher in male (3.4%) skull bones when compared to female (1.2%) skulls.

Conclusions: This inca bone incidence varies among different population. The knowledge about these inca bones would be useful to Clinicians, Radiologists and Neurosurgeons during their case management, besides the Forensic experts during their medicolegal case examinations.

Keywords: Interparietal bone, Occipital bone, Osteological study

INTRODUCTION

The occipital bone in the human skull consists of two parts: supraoccipital and interparietal part. Sometimes the interparietal portion of the occipital bone remains separated from the supraoccipital part by a transverse suture, resulting in the occurrence of inca bone. This was first described as non-wormian epactal or interparietal bone by Saint-Hilaire in 1823 [1]. It was labelled as Os inca by Schudi T and Uber JJ [2]. This inca bone was also known as Inca Os interparietal or Goethe's ossicles. These ossicles were named as inca bone because the member of inca tribe royal family had a crown like configuration on their head [3]. So, these inca bones were first observed in the mummies of Inca civilisation and in the skulls of contemporary indigenous people of Southern Andes.

These inca bones variation was originally seen in the South American and Latin American skulls, it does occurs in the people of other geographical regions of the world. According to Hanihara T and Ishida H large number of variations was seen in these inca bones [4]. As started by Keith A, a single separate inca bone in man was a rare anomaly. In primates and carnivores, it fuses with the occipital bone. Sometimes in man, the interparietal bone is seen as a separate bone, as a variant [5]. According to Deol MS and Truslove JM in 1957, who studied the inca bones formation in mice, concluded that it was controlled genetically [6]. The variations in inca bones in human population has been reported by several investigators because of its importance in medico-legal examination by forensic experts. Purkait R and Chandra H had suggested nomenclature of Inca variants on the basis of ossification centres and described its importance as corroborative evidence for identification of the deceased in medicolegal cases [7]. The knowledge on inca bone is also essential to clinicians because this may lead to complications during some procedures like burr hole surgeries [8]. So, this study was aimed to investigate the incidence of inca bone and its variations in human skull bones which might give the importance of inca bone

during surgeries for clinicians, forensic experts in their medicolegal examinations and also the anthropologists for their studies.

MATERIALS AND METHODS

The present osteological study was done on 230 dry human skulls during one year period from August 2018 to August 2019. The study sample bones were taken according to convenient sampling method. Prior permission was taken from concerned Institutional Head of the Departments to conduct the study in their colleges. The skulls were collected from Anatomy and Forensic Medicine departments of five medical colleges (Dr. PSIMS & RF, Nri Medical College, Guntur Medical college, Siddartha Medical College, Ashram Medical College), both government and private medical colleges, in and around Krishna district, Andhra Pradesh, Southern India. Fifty skulls were selected from each medical college and after fulfilling exclusion criteria, 230 skulls were included in the study.

Inclusion criteria: The skulls of both the sexes which were normal without any signs of fracture were included in the study. Characteristics like forehead shape, glabella, supraorbital rim, zygoma, mandible, chin size and shape were considered to differentiate between male and female skulls [9]. Skulls of all the ages were included in the study.

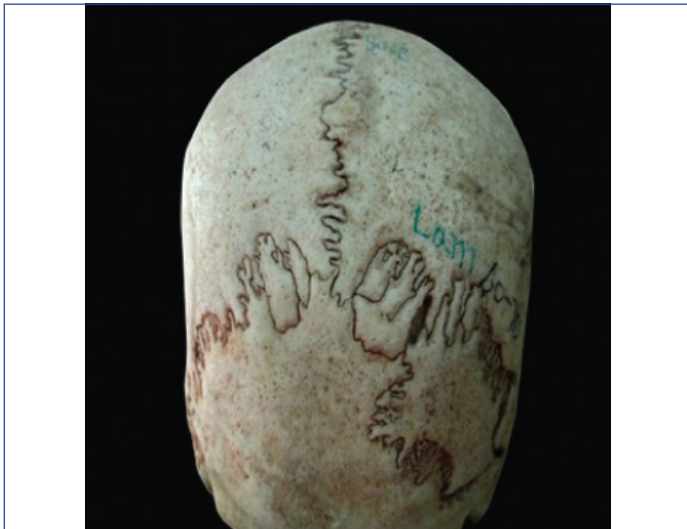Exclusion criteria: Skulls with pathological deformities and antemortem or postmortem injuries were excluded from the study. The skull bones were macroscopically examined for the presence of inca bones. The number of fragments of os inca was also noted. The skulls were examined for sexual dimorphism for inca bone variation. The photographs were taken for the skull bones with os inca variations.

STATISTICAL ANALYSIS


The data obtained was tabulated. Inferential statistics in terms of simple percentages were used.

RESULTS

Among the 230 skull bones, 145 skulls were male skull bones and 85 were female skull bones. Out of the 230 skull bones examined, 6 (2.6%) skulls were seen with inca bones. Among these six skulls with inca bones five variations were noted. One skull was with incomplete lateral asymmetric inca bone [Table/Fig-1], one skull with incomplete median inca bone [Table/Fig-2], one skull with asymmetric tripartite inca bone [Table/Fig-3], one skull with complete tripartite inca bone [Table/Fig-4] and two skulls showed complete undivided inca bone [Table/Fig-5,6].



[Table/Fig-1]: Incomplete lateral asymmetric inca bone.

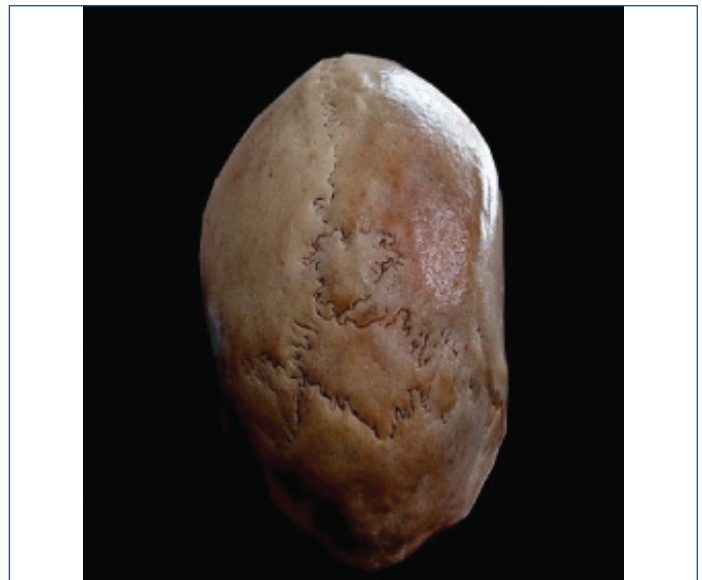

[Table/Fig-2]: Incomplete median inca bone.

In this study, incidence of inca bone variation was higher in male (3.4%) skull bones when compared to female (1.2%) skulls [Table/Fig-7].

DISCUSSION

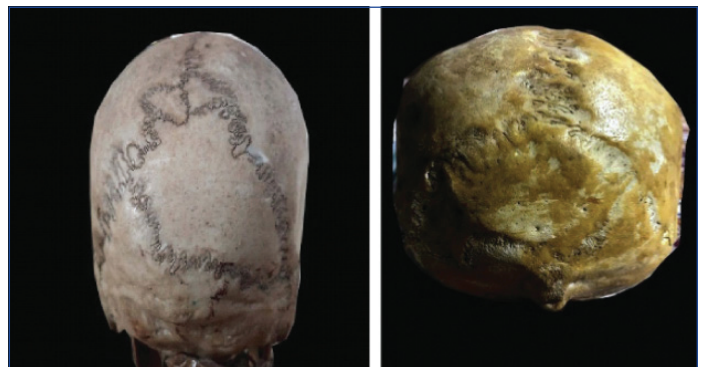The inca bones may occur because of partial or complete failure of fusion of the ossification centres of the squamous part of the occipital bone. Failure of fusion between primary and secondary centers of ossification of occipital bone leads to the formation of interparietal bone. Literature available on this inca bones suggests that occurrence of inca bone is rare [10]. Based on various studies, the incidence of the inca bones was found to be 15% in Nigerians [11], 2.4% in Indians [12]. Among modern population, the incidence of inca bone is highest among the marginal isolates, who retained their early ancestral traits [13]. As an evidence of regional continuity inca bone is characteristic of East-Asians. Such occurrence of inca bone has evolutionary, paleoanthropological, morphological and medicolegal importance. In Marathe R et al., study done in Central India, gross incidence of os incae was found to be 1.315%. This



[Table/Fig-3]: Asymmetric tripartite inca bone.



[Table/Fig-4]: Complete tripartite inca bone.



[Table/Fig-5]: Complete undivided inca bone.

Type of inca bone	No. of fragments	N (%)
1. Complete undivided inca bone (os inca totum)	1	2 (33.33%)
2. Incomplete lateral asymmetric inca bone (os inca laterale)	1	1 (16.67%)
3. Incomplete median asymmetric inca bone (os inca centrale)	1	1 (16.67%)
4. Asymmetric tripartite inca bone	3	1 (16.67%)
5. Complete tripartite inca bone os inca (tripartitum)	3	1 (16.67%)
Total {6 (2.6%) out of 230 skull}		

[Table/Fig-6]: Distribution of variations of inca bones in the present study.

Gender	No. of skulls examined	Incidence of inca bones
Male	145	5 (3.4%)
Female	85	1 (1.2%)
Total	230	6 (2.6%)

[Table/Fig-7]: Sexual dimorphism and Gross incidence (%) frequency of skull bones.

study revealed the gross incidence of inca bone in South Indian population as 13.33% which was high when compared to North Indians and also found to be associated with cranial deformities like metopic suture and asymmetrical frontal sinuse [10]. In present study, the incidence of inca bone was 2.6% which was similar to Pal GP et al., study on the ossification of membranous part of the squamous occipital bone in man [14] and Kumud D study in Amritsar, almost near to the incidence of inca bone in other studies [15] like Saxena SK et al., study (2.5%) on Interparietal bones in Nigerian skulls [11], Yucel F et al., study (2.8%) of interparietal bone in man [16]. Results of present study and other studies is tabulated in [Table/Fig-8] [10-12,14-19].

S.no.	Study on Inca bones	No. of skulls studied	Incidence of inca bones
1	Srivastava HC [18] (1977)	620	0.8%
2	Singh PJ et al., [12] (1979)	500	1.6%
3	Pal GP et al., [14] (1984)	348	2.6%
4	Saxena SK et al., [11] (1986)	40	2.5%
5	Yucel F et al., [16] (1998)	540	2.8%
6	Marathe RR et al., [10] (2010)	380	1.31%
7	Kumud D [15] (2011)	150	2.66%
8	Nirmale VP [19] (2012)	148	4.05%
9	Walulkar S et al., [17] (2013)	175	2.86%
10	Present study (2019)	230	2.6%

[Table/Fig-8]: Incidence of inca bones among various studies [10-12,14-19].

In present study, the incidence of inca bone variation was higher in male (3.4%) skull bones when compared to female (1.2%) skulls. This finding regarding sexual dimorphism in incidence of inca bone variations was similar to study findings of Carolineberry A and Berry RJ on Epigenetic variation in human cranium (Male: 4.6 % and Female: 2.9%) [20] and Marathe R et al., study on interparietal bones in neurocranium of human skulls in Central India (male: 1.428% and female: 1.176 %) [10]; whereas in the Nirmale VP study there is no sexual difference in the incidence of inca bones [19].

So, this study finding suggests that incidence of inca bone is considerably important and it has to be taken into account during clinical procedures like surgeries, medicolegal cases examinations and anthropological surveys. This inca bone also shows sexual dimorphism which can help the forensic experts for identifying the skulls.

Limitation(s)

Age variation was not taken into consideration.

CONCLUSION(S)

In present study, the incidence of inca bone was found to be 2.6% and the incidence of inca bone variation was higher in males (3.4%) skull bones. This inca bone incidence varies among different population with sexual dimorphism. Inca bones can give rise to false appearance of skull bone fractures in Roentgenogram. So, the knowledge about these inca bones would be useful to Clinicians, Radiologists and Neurosurgeons. Being rare in occurrence and due to its association with other cranial deformities, the presence of inca bone can be used as a tool for identifying an individual in forensic studies. Besides forensic experts during medicolegal case examinations, this inca bone knowledge could also be useful to anatomical and anthropological experts in their studies.

Acknowledgements

The author immensely thank the Institutional Heads of Anatomy and Forensic Medicine departments of other medical colleges for permitting to do the study.

REFERENCES

- [1] Hilaire S. GE Reports and considerations of novaux comparative osteology regarding animals. Mem. Paris Museum of Natural History. 1823; 10:165.
- [2] Schudi T, Uber JJ. Die Ureinwohner V on Peru. Arch Anat Physiol Wiss Med. 1844;98-109.
- [3] Srivastava HC. Ossification of the membranous portion of the squamous part of the occipital bone in man. J Anat. 1992;180:219-24.
- [4] Hanihara T, Ishida H. Os Inca: Variation in frequency in major human population groups. J Anat. 2001;198:137-52.
- [5] Keith A. Human Embryology and Morphology. 6th Ed., London, Edward Arnold and Co. 1948; 223-224.
- [6] Deol MS, Truslove GM. Genetical studies on the skeleton of the mouse XX. Maternal physiology and variation in the skeleton of C57BL mice. J Genetics. 1957;55(2):288-312.
- [7] Purkait R, Chandra H. The identity of Inca, medicolegal importance and suggested nomenclature of variants. J Anat Soc India. 1989;38(3):162-71.
- [8] Jadav J, Gonsai V, Nirvan A. Study of Interparietal (Inca) bone in dry human skulls. BJKines-NJBAS. 2015;7(2).
- [9] Avelar LET, Cardoso MA, Bordoni LS, Avelar LM, de Miranda Avelar JV. Aging and sexual differences of human skull. Plast Reconstr Surg Glob Open. 2017;5:e1297.
- [10] Marathe R, Yogesh A, Pandit S, Joshi M, Trivedi G. Inca -interparietal bones in neurocranium of human skulls in central India. J Neurosci Rural Pract. 2010;1(1):14-18.
- [11] Saxena SK, Chowdhary DS, Jain SP. Interpretable bones in Nigerian skulls. J Anat. 1986;144:235-37.
- [12] Singh PJ, Gupta CD, Arora AK. Incidence of interparietal bones in adult skulls of Agra region. Anat Anz. 1979;145(5):528-31.
- [13] Ossenberg NS. The influence of artificial cranial deformation on discontinuous morphological traits. Am J Phys Anthropol. 1970;33(3):375-72.
- [14] Pal GP, Tamankar BP, Routal RV, Bhagat SS. The ossification of the membranous part of the squamous occipital bone in man. J Anat. 1984;138:259-66.
- [15] Kumud D. Os Incae morphometric, clinical and medicolegal perspectives. J Anat Soc India. 2011;60(2):218-23.
- [16] Yucel F, Egilmez H, Akgun Z. A study on the interparietal bone in Man Tr. J of Medical Sciences. 1998;28:505-09.
- [17] Walulkar S, Walulkar M, Sheersagar DK. Study of Inca bone in Vidarbha region of Maharashtra. PJMS. 2013;3(1):19-23.
- [18] Srivastava HC. Development of the ossification centers in the squamous portion of the occipital bone in man. J Anat. 1977;124:643-49.
- [19] Nirmale VP. Variation of frequency of Os Incae in human skull. Indian Journal of Biomedical Science. 2012;28:05-09.
- [20] Carolineberry A, Berry RJ. Epigenetic variation in the human cranium. J Anat. 1967;101:361-79.

PARTICULARS OF CONTRIBUTORS:

1. Assistant Professor, Department of Anatomy, Dr. Pinnamaneni Sidhartha Institute of Medical Sciences and Research Foundation, Vijayawada, Andhra Pradesh, India.
2. Assistant Professor, Department of Anatomy, Guntur Medical College, Guntur, Andhra Pradesh, India.

NAME, ADDRESS, E-MAIL ID OF THE CORRESPONDING AUTHOR:

Dr. Anusha Donapudi,
Vijaya Vihar 1, A10, Pinnamaneni Sidhartha, Doctors quarters, Chinnaavutapally,
Vijayawada, Andhra Pradesh, India.
E-mail: donepudi.anusha@gmail.com

PLAGIARISM CHECKING METHODS: [Jan H et al.]

- Plagiarism X-checker: Mar 07, 2020
- Manual Googling: Apr 23, 2020
- iThenticate Software: May 22, 2020 (14%)

ETYMOLOGY: Author Origin

AUTHOR DECLARATION:

- Financial or Other Competing Interests: None
- Was Ethics Committee Approval obtained for this study? Yes
- Was informed consent obtained from the subjects involved in the study? No
- For any images presented appropriate consent has been obtained from the subjects. No

Date of Submission: **Mar 02, 2020**

Date of Peer Review: **Mar 24, 2020**

Date of Acceptance: **Apr 27, 2020**

Date of Publishing: **Jul 01, 2020**