

Comparison of Carotid Artery Intima-media Thickness and Resistive Index by Ultrasound and Colour Doppler in Pre-hypertensives and Stage One Hypertensives

SUBHA VENKATACHALAM¹, UMAMAGESWARI AMIRTHALINGAM², ELAMPARIDHI PADMANABAN³, KULASEKARAN NADHAMUNI⁴, BALACHANDIRAN GOPALARATHNAM⁵, NAGARAJAN KINATHANKARAIYAN⁶

ABSTRACT

Introduction: Pre-hypertension and stage one hypertension remains major public health problem in both developed and developing countries. It primarily affects elastic arteries, hence common carotid artery Intima-Media Thickness (IMT) and Resistive Index (RI) considered an early predictor of cerebrovascular and cardiovascular complications.

Aim: This study was aimed to assess common carotid artery IMT and Resistive Index in pre-hypertensives and stage one hypertensive patients and to compare the findings between both groups.

Materials and Methods: The study design was hospital based cross sectional study and was conducted in Sri Manakula Vinayagar Medical College and Hospital, Pondicherry. Forty non diabetic patients in the age group of 25-65 years were examined for carotid artery Doppler. The patients were divided into prehypertensives and stage I hypertensives. Bilateral common carotid artery IMT and RI were evaluated.

Results: Among the 40 patients studied, 24 patients were prehypertensives and 16 were stage I hypertensives, 70% were females and 30% were males. Palpitation was the commonest presenting symptom. Mean Systolic blood pressure was 128.25 ± 4.66 in prehypertensives and 141.25 ± 6.44 in stage I hypertensives. The mean IMT in both prehypertensives and stage I hypertensives was 0.06 ± 0.01 on either side. Mean Resistive Index in prehypertensives was 0.73 ± 0.08 on either side; while that in stage I hypertensives was 0.72 ± 0.13 on right and 0.71 ± 0.11 on left. However, no rise in IMT was observed with increasing age in both the groups. On comparison both the groups showed no significant difference in IMT and RI.

Conclusion: To conclude, both the prehypertensives and stage I hypertensives show similar pattern of IMT and RI of the common carotid artery.

Keywords: Palpitation, Pourcelot index, Vascular resistance

INTRODUCTION

Development of atherosclerosis in vascular system occurs by various mechanisms, among which hypertension is an important and independent risk factor [1]. More than ninety-five percentages of hypertensive patients in the community are of essential, whereas only a small percentage has an identifiable cause which is known as secondary hypertension. The various systemic changes can be assessed by the atherosclerotic changes that take place in the carotid artery [2]. It increases the risk of stroke, coronary artery disease and peripheral arterial disease by two-three folds with risk being proportional to the severity of hypertension [3].

Increase in IMT of an artery has been used as a surrogate marker of subclinical atherosclerosis and early detection of vascular events [3]. B-mode ultrasound of carotid arteries is a non-invasive, safe, inexpensive, sensitive, valid and reproducible method of directly assessing IMT [4]. The intima-media complex is made up of various elements like the endothelial cells, connective tissue and smooth muscle. This complex is measuring sonographically as the IMT [5].

The velocity of blood flowing via the carotid artery can be determined by colour Doppler [6]. There are multiple ways to increase the accuracy of the results, few of which are Doppler angle, sample volume box and colour gain [7].

According to Pourcelot RI is a haemodynamic parameter, which is determined by Doppler Sonography basically reflecting the vascular resistance which in turn depends on distensibility of the vessel [8].

The present study aimed to evaluate the common carotid artery IMT and RI by Ultrasound and Colour Doppler in prehypertensives and stage one hypertensive patients and to compare the findings between prehypertensives and stage one hypertensives.

MATERIALS AND METHODS

The study design was hospital based cross sectional study and was conducted in department of Radio-Diagnosis at Sri Manakula Vinayagar Medical College and Hospital, Puducherry. The study was approved by the institute ethics committee. The duration of study was six months. Stage I hypertensive and prehypertensive subjects in the age group of 25 to 60 years were included. Those with history of Diabetes mellitus and hyperlipidemia were excluded from the study.

The subjects were divided as follows: Prehypertensives: Systolic Blood pressure: 120-139 mmHg or Diastolic Blood pressure: 80-89 mmHg; Stage I hypertensives: Systolic Blood pressure: 140-159 mmHg or Diastolic Blood pressure: 90-99 mmHg [9].

After obtaining informed consent, ultrasonography and doppler was performed using GE-voluson-S6 scanner with 7.5-10 MHz linear array transducer.

IMT defined as the distance between leading edge of the lumen-intima echo and leading edge of the media-adventitia echo is measured 1.5 cm proximal to its bifurcation. Then pulsed-Doppler carried out in Common Carotid Artery (CCA) 1.5 cm proximal to its bifurcation with maximum Doppler angle of 60°. The maximum systolic and minimum diastolic flow rates were determined and RI was calculated automatically in a cycle by means of in-built software.

These IMT measurements and RI done in bilateral CCA, 1.5 cm proximal to its bifurcation.

STATISTICAL ANALYSIS

Data was entered into Microsoft excel datasheet and Epi _ info version 7.2.1.0 and was analysed using SPSS 24.0 version software. Microsoft word and Excel have been used to generate graphs, tables etc.,

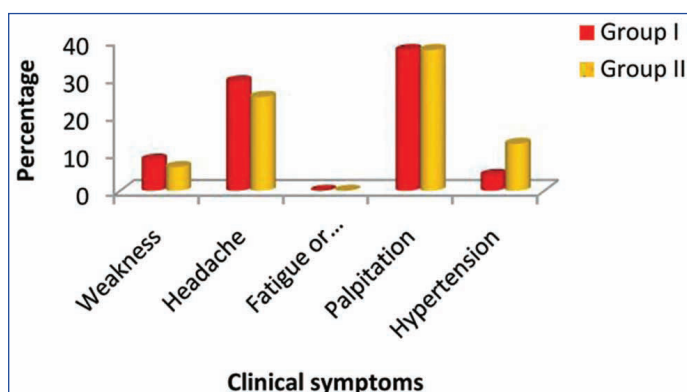
Statistical comparisons were performed between prehypertensives and stage I hypertensives in terms of percentage. Chi-square test has been used to find the significance between gender distribution and symptoms distribution of two groups of patients studied. Student t-test has been used to find the significance of Blood Pressure parameters and IMT and RI between two groups.

RESULTS

Among the 40 patients studied 24 patients were prehypertensives and 16 were stage I hypertensive patients. Out of total, 70% were females and 30% were males [Table/Fig-1]. Palpitation was the commonest presenting symptom [Table/Fig-2]. Mean Systolic blood pressure was 128.25 ± 4.66 in prehypertensives and 141.25 ± 6.44 in stage I hypertensives [Table/Fig-3].

Gender	Pre-hypertensives	Stage I hypertensives	Total
Female	18 (75%)	10 (62.5%)	28 (70%)
Male	6 (25%)	6 (37.5%)	12 (30%)
Total	24 (100%)	16 (100%)	40 (100%)

[Table/Fig-1]: Shows Gender distribution of Pre-hypertensives and Stage one hypertensives of patients studied.



[Table/Fig-2]: Clinical symptoms distribution in two groups of patients studied (Group I-Pre-hypertensives) (Group-II-Stage-I hypertensives)

	Pre-hypertensives	Stage-I hypertensives	Total	p-value
SBP (mm Hg)	128.25 ± 4.66	141.25 ± 6.44	133.45 ± 8.39	<0.001**
DBP (mm Hg)	83.58 ± 3.12	91.38 ± 4.11	86.70 ± 5.21	<0.001**

[Table/Fig-3]: Blood pressure comparison in Pre-hypertensives and Stage-I hypertensives of patients studied.

SBP: Systolic blood pressure; DBP: Diastolic blood pressure

The mean IMT in both prehypertensives and stage I hypertensives was 0.06 ± 0.01 on either side. However, no rise in IMT was observed with increasing age in both the groups [Table/Fig-4].

IMT	Pre-hypertensives	Stage-I hypertensives	Total	p-value
• Right	0.06 ± 0.01	0.06 ± 0.01	0.06 ± 0.01	0.761
• Left	0.06 ± 0.01	0.06 ± 0.01	0.06 ± 0.01	0.863

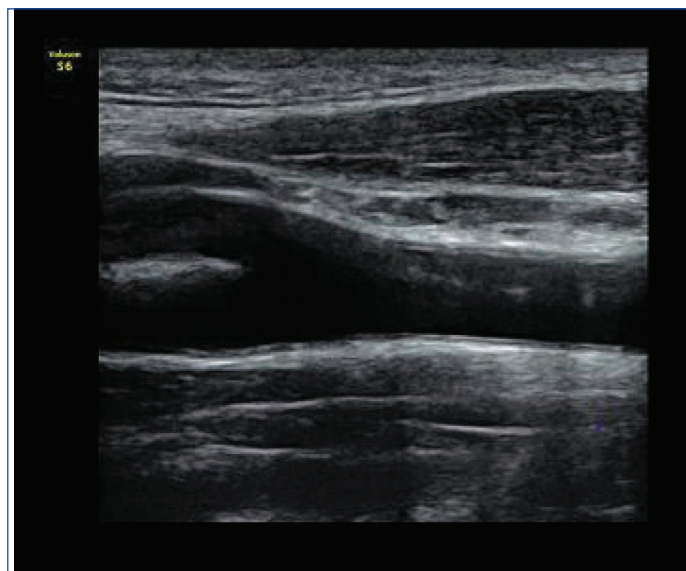
[Table/Fig-4]: Comparison of Intima-Media thickness (IMT) in Pre-hypertensives and Stage-I hypertensives of patients studied.

Mean RI in prehypertensives was 0.73 ± 0.08 on either side; while that in stage I hypertensives was 0.72 ± 0.13 on right and 0.71 ± 0.11 on left [Table/Fig-5].

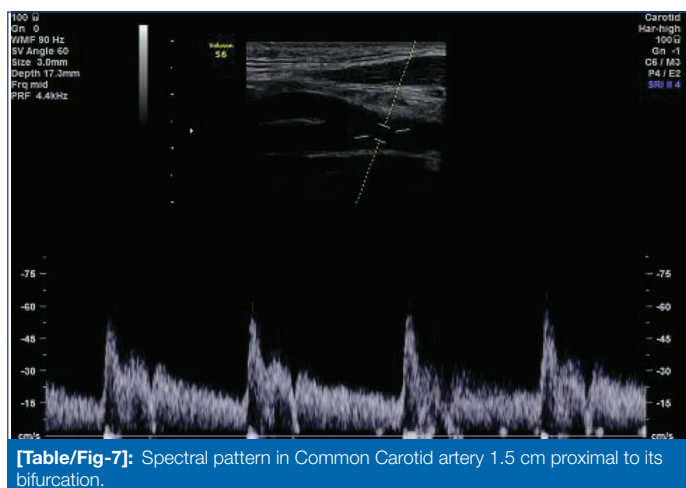
On comparison both the groups showed no significant difference in IMT and RI [Table/Fig-6,7].

RI	Pre-hypertensives	Stage-I hypertensives	Total	p-value
• Right	0.73 ± 0.08	0.72 ± 0.13	0.72 ± 0.10	0.750
• Left	0.73 ± 0.08	0.71 ± 0.11	0.72 ± 0.09	0.502

[Table/Fig-5]: Comparison of Resistive Index (RI) in Pre-hypertensives and Stage-I hypertensives of studied patients.



[Table/Fig-6]: Measurement of Intima-Media thickness in Common Carotid artery 1.5 cm proximal to its bifurcation.



[Table/Fig-7]: Spectral pattern in Common Carotid artery 1.5 cm proximal to its bifurcation.

DISCUSSION

The present study demonstrates CCA-IMT and RI in prehypertensives and stage I hypertensives show similar pattern in common carotid artery. So, on comparison both the groups showed no significant difference in IMT and RI. This study was aimed to focus on an early diagnosis and treatment, prevention of complication which occurs in cerebrovascular and cardiovascular system in prehypertensives and stage one hypertensives.

Lankarani KB et al., reported IMT is affected by age and hypertension, smoking, diabetes mellitus, body mass index, triglyceride level. The contrast in the present study was IMT was not affected by prehypertension and Stage one hypertension. This might be due to variation in duration of pre-hypertension and stage one hypertension at time of presentation by patient to hospital [10].

In a study done by Liu B et al., 55.9% of Chinese adults were hypertensives, out of which 66.9% were males and 41.1% were females. Where as, the present study showed that the prevalence of pre-hypertension was 60%, including 75% in female 25% in men. Hence, detecting and preventing pre-hypertension is important to prevent future cardiovascular and cerebrovascular diseases [11].

The results of this study are in line with those of the Mackinnon AD et al., study in which Internal Carotid Artery-IMT more surrogate

measure of vascular risk than the more commonly used common carotid artery-IMT and IMT progression was greatest at the internal carotid artery followed by bifurcation and then common carotid artery and concluded, changes in IMT of internal carotid artery better correlates with vascular system changes rather than the common carotid artery IMT [12].

The present results indicate IMT and resistive index was non-significant in 55-65 years when compared to less than 55 years age. These are similar to the findings of another study by Su T-C et al., in which young subjects IMT was lower in women than in men; however gender differences in IMT became non significant in older subjects [13,14].

LIMITATION

The main limitation of the study was the total number of patients relatively small, so a large total number of patients would be recommended. The second limitation was that the study period was short duration. So, study over long period of time would be recommended.

The third limitation was that the Blood Pressure measurements were performed from patients medical records which have resulted in inevitable inter observer variation affecting the reliability of the measurements.

The fourth limitation was IMT measurement done only in Common Carotid Artery. So suggested internal carotid artery IMT measurement along with common carotid artery should be recommended which will better evaluate progression of vascular risk than more commonly used common carotid artery IMT.

The last limitation of the present study was that medical treatment administered to hypertension was not taken into account.

CONCLUSION

The common carotid artery of the Prehypertensives and stage I hypertensives showed similar pattern of IMT and resistivity index, which indicates that the subtle changes in hypertension does not affect the aforementioned parameters. However considering the limitations of the present study a detailed evaluation with a larger sample size may be needed.

ACKNOWLEDGEMENTS:

Epidemiology unit of Community Medicine and Participants in this study for their valuable contributions.

REFERENCES

- [1] Tamhane TM, Katarla M, Kachewar SG, Lakhkar DL. Ultrasonographic evaluation of carotid artery atherosclerosis in normotensive and hypertensive individuals. *Scholars Journal of Applied Medical Sciences*. 2016;4(9C):3374-79.
- [2] Sharma P, Lohani B, Chataut SP. Ultrasonographic evaluation of carotid intima-media thickness in hypertensive and normotensive individuals. *Nepal Med Coll J*. 2009;11(2):133-35.
- [3] Kumar M, Agarwal PK, Gupta M, Verma VK, Kumar S, Kumar G, et al. Comparison of carotid intima media thickness between hypertensive patients and control group. A study from rural tertiary care hospital in central India. *Journal of Medical Science and Clinical Research*. 2017;5(8):26407-11.
- [4] Zureik M, Temmar M, Adamopoulos C, Bureau JM, Courbon D, Thomas F, et al. Carotid plaques, but not common carotid intima media thickness, are independently associated with aortic stiffness. *Journal of Hypertension*. 2002;20:85-93.
- [5] Yunusa K, Oluseyi H, Haruna, Shehu A. Sonographic measurement of common carotid artery intima media thickness among healthy adults in Jos, Nigeria. *J Harmoniz Res Med and Hlth Sci*. 2015;2(4):156-62.
- [6] Tagueisir S, Gameraaddin MB, Bablker MS, Gareeballah A, Abdelmaboud S, Sallh S. Doppler sonographic assessment of carotid arteries in sudanese stroke patients. *Brain Circulation*. 2017;3(2):114-20.
- [7] Tahmasebpour HR, Buckley AR, Cooperberg PL, Fix CH. Sonographic examination of the carotid arteries. *Radio Graphics*. 2005;25(6):1561-75.
- [8] Frauchiger B, Schmid HP, Roedel C, Moosmann P, Staub D. Comparison of Carotid Arterial Resistive Indices with Intima -Media Thickness as Sonographic markers of Atherosclerosis. *Stroke*. 2001;32:836-41.
- [9] The seventh report of the Joint National Committee on Prevention, Detection, Evaluation and Treatment of High Blood Pressure. *JAMA*. 2003;289:2560-71.
- [10] Lankarani KB, Ghaffarpassand F, Mahmoodi M, Dehghankhalili M, Honarvar B, Lotfi M, et al. Predictors of common carotid artery intima-media thickness and atherosclerosis in a sample of Iranian general population. *Shiraz E-Med J*. 2015;16(5):e27906.
- [11] Liu B, Dong X, Xiao Y, Mao X, Pan W, Un D, et al. Variability of metabolic risk factors associated with prehypertension in males and females: a cross sectional study in China. *Arch Med Sci*. 2018;14,4:766-72.
- [12] Mackinnon AD, Dunne PJ, Sitzler M, Buehler A, Kegl S, Markus HS, et al. Rates and Determinants of site specific progression of carotid Artery Intima Media Thickness. *Stroke*. 2004;35:2150-54.
- [13] Chen Su T, Chien KL, Jeng JS, Chen MF, Ching Hsu H, Ling Torng P, et al. Age and gender Associated Determinants of carotid Intima Media Thickness: A Community based study. *J Atheroscler Thromb*. 2012;19:872-80.
- [14] Howard G, Sharrett AR, Heiss G, Evans GW, Chambless LE, Riley WA, Burke GL. Carotid intimal medial thickness distribution in general populations as evaluated by B-mode ultrasound. ARIC investigators. *Stroke*. 1993;24:1297-304.

PARTICULARS OF CONTRIBUTORS:

1. Post Graduate Resident, Department of Radiodiagnosis, Sri Manakula Vinayagar Medical College and Hospital, Madagadipet, Puducherry, India.
2. Associate Professor, Department of Radiodiagnosis, Sri Manakula Vinayagar Medical College and Hospital, Madagadipet, Puducherry, India.
3. Senior Resident, Department of Radiodiagnosis, Sri Manakula Vinayagar Medical College and Hospital, Madagadipet, Puducherry, India.
4. Professor and Head, Department of Radiodiagnosis, Sri Manakula Vinayagar Medical College and Hospital, Madagadipet, Puducherry, India.
5. Associate Professor, Department of Radiodiagnosis, Sri Manakula Vinayagar Medical College and Hospital, Madagadipet, Puducherry, India.
6. Professor and Head, Department of General Medicine, Sri Manakula Vinayagar Medical College and Hospital, Madagadipet, Puducherry, India.

NAME, ADDRESS, E-MAIL ID OF THE CORRESPONDING AUTHOR:

Dr. Umamageswari Amirthalingam,
26B,VAI GAI Street, Vasanth Nagar, Muthialpet, Puducherry-605005, India.
E-mail: dr_amirthauma@yahoo.co.in

FINANCIAL OR OTHER COMPETING INTERESTS: None.

Date of Submission: **Oct 30, 2018**

Date of Peer Review: **Nov 29, 2018**

Date of Acceptance: **Dec 29, 2018**

Date of Publishing: **Jan 01, 2019**