

Computed Tomography-Guided Core Needle Biopsy of The Thoracic Lesions: A One Year Observational Study

PRADEEP S GOUDAR, ASHWIN S PATIL, VIRUPAXI V HATTIHOLI, ADARSH SANIKOP

ABSTRACT

Introduction: The evaluation and diagnosis of the thoracic lesions by conventional methods leads to increased morbidity. Computed tomography (CT)-guided core biopsy is minimally invasive, accurate for needle puncture localization with less post-procedural complications.

Aim: The aim was to evaluate the safety, diagnostic accuracy, and the complications of CT-guided core needle biopsy of thoracic lesions.

Materials and Methods: All the 60 patients with varied diagnosis of thoracic lesions underwent CT-guided core needle biopsy of the thoraces to procure tissue. The tissue samples were analyzed histopathologically for diagnosing benign and malignant lesions. Patients underwent preliminary investigations and the lung biopsy was performed by automated Cook's biopsy gun with an 18-gauge needle of length 15 cm and a throw of 2 cm. The

vitals were monitored and postprocedural CT of the thorax was performed to identify any complications.

Results: Thoracic lesions were predominantly observed in men (40), with most of the patients in the age-group of 51–60 years. Among the 60 patients with thoracic lesions, 59 had malignant lesions, whereas one patient had benign lesion. Most of the lesions were located in the lung parenchyma (52). Adenocarcinoma was the most frequent (44) type of malignant lesion followed by squamous cell carcinoma (7). Thoracic lesions were predominantly in the right upper lobe (15). However, minimal pneumothorax was observed as a postprocedural complication in three patients. The sensitivity and specificity of the procedure were 100%.

Conclusion: CT-guided core needle biopsy is a safe and effective method with high sensitivity and specificity. It is a highly accurate technique in the diagnosis and evaluation of benign and malignant thoracic lesions.

Keywords: Benign, Carcinoma, CT guided-core needle biopsy, Histopathology, Malignant, Sensitivity, Thoracic lesions

INTRODUCTION

Thoracic lesions, both benign and malignant, are the lesions of the lung, pleura, mediastinum, and vertebrae. The diagnosis of these peripheral lung lesions is demanding and requires minimally invasive procedures to prevent intraprocedural complications [1]. Due to lower yield of flexible bronchoscopy and sputum cytology, computed tomography (CT)-guided interventional procedure is most preferred in the evaluation of the thoracic mass lesions [2,3]. Thoracic interventions such as CT-guided core needle biopsy can be conducted quickly with less morbidity [4]. CT scan is the best guiding modality in viewing the thoracic anatomy and allows percutaneous access. Localization and guiding in the puncture of the intrapulmonary and mediastinal lesions is made easy by CT-guided core needle biopsy [4,5].

Indications of CT-guided core needle biopsy include a new or enlarging solitary nodule or mass on the chest radiograph

which is not amenable to diagnosis by bronchoscopy and CT shows it is unlikely to be accessible by bronchoscopy. The other indications include multiple nodules in a patient not known to have a malignancy or who has had prolonged remission and persistent infiltrates either single or multiple for which no diagnosis has been made by laboratory tests and a hilar mass following negative bronchoscopy [4,6-9].

Determination of an optimal cutaneous entry point in order to avoid transgression of a pleural fissure or puncture of large vessels, bronchi, esophagus, and other structures [4,5]. Postprocedural complications, such as pneumothorax and pulmonary hemorrhage, can be easily identified during the CT procedure [5]. Magnetic resonance imaging and ultrasonography possess limitations such as improper images due to respiratory motions and inability to visualize the intrapulmonary and bone lesions. Large lesions can be detected using ultrasonography, however, smaller lesions

and those around the mediastinum and hilar region require CT for access and identification. The CT-guided core needle biopsy does not possess these limitations, and circumvents exploratory surgery for staging with lesser trauma, hence generating improved images [5,10-13].

Core needle biopsies are less susceptible to false-negative and false-positive outcomes when compared to fine needle aspiration cytology. It helps in detecting the histological and architectural information, which is important in subtyping the malignancies, immunohistochemistry, and receptor analysis [10]. New radiological technologies, such as the automated spring-loaded biopsy gun and coaxial needle systems produce multiple large core samples with a single puncture. These techniques are devoid of the postprocedural complications [10,14]. Therefore, the present study aimed to evaluate the efficacy of minimally invasive CT-guided core needle biopsy in diagnosing the type of thoracic lesion. The rate and type of complications involved in the procedure were also determined.

MATERIALS AND METHODS

A one year (Jan–Dec 2015) observational study was conducted at the Department of Radiology, Jawaharlal Nehru Medical College including 60 patients aged 18 years or more with thoracic lesions referred for CT-guided core biopsy. Patients with coagulation abnormalities, high risk of pneumothorax, hemothorax and other related complications, and pregnant women were excluded from the study. Before the commencement of study, ethical clearance was obtained from the Institutional Ethical Committee. After explaining the purpose of the study, written informed consent was obtained from all the patients before data collection. Data were recorded in a predesigned and pretested proforma.

Study intervention: Patients underwent preliminary investigations, including activated partial prothrombin time, prothrombin time, international normalized ratio, bleeding time, and clotting time. At the beginning of the procedure, patients were positioned on the CT gantry. To delineate the thoracic lesion and to locate the site of needle puncture, immediate pre-procedural topogram along with CT of the chest, from the neck base till the domes of the diaphragm, were performed. The percutaneous access site was determined and marked with a marker. The local area was cleaned with povidone iodine and surgical spirit.

Computed tomography-guided transthoracic lung mediastinal biopsy: The lung biopsy was performed by automated Cook's biopsy gun with an 18-gauge needle of length 15 cm and a throw of 2 cm. Under aseptic conditions, the biopsy needle was introduced into the percutaneous site until it entered the lesion. The obtained biopsy samples were added in 10% formalin solution each

and were processed for histopathological examinations. At the site of intervention, immediate postprocedural compression was done with a gauge dressing for five minutes to cease bleeding. The vitals were monitored, and oral analgesics were administered. Postprocedural CT of the thorax was performed to identify any complications, such as pneumothorax and hemothorax.

STATISTICAL ANALYSIS

The data were coded and entered in Microsoft excel worksheet and analyzed using SPSS 20. The categorical data were expressed as rates, ratios, proportions, and percentages and continuous data were expressed as mean±standard deviation. The accuracy of CT-guided biopsy was expressed as sensitivity.

RESULTS

The thoracic lesions were predominantly observed in men (40) than in women (20). The age group of the patients ranged from 19-83 years. Most of (24) the patients were in the age-group of 51-60 years. Lesions were majorly located in the lung parenchyma (52) in most of the patients followed by the mediastinum (8). Most of the thoracic lesions in the elderly patients were localized in the lung parenchyma (48), whereas mediastinum (6) was the most common site of lesion in young patients [Table/Fig-1].

Parameter	n (%)	
Gender	Male	40 (66.66)
	Female	20 (33.34)
Age (years)	11 – 20	1 (1.66)
	21 – 30	5 (8.33)
	31 – 40	1 (1.66)
	41 – 50	2 (3.33)
	51 – 60	24 (40)
	61 – 70	19 (31.66)
	>70	8 (13.33)
Site of lesion	Lung parenchyma	52 (86.67)
	Mediastinum	8 (13.33)

[Table/Fig-1]: Demographic and clinical characteristics of the sample.

Evaluation of the thoracic lesions by computed tomography-guided core needle biopsy: The CT evaluation of thoracic lesions revealed 59 malignant lesions and one benign lesion. The histopathological reports of the tissue samples obtained after the CT-guided core biopsy were in sync with the findings of the CT evaluation. Malignant lesions in most (53) of the patients were of primary origin; however, some (6) of the patients had secondary malignant lesions [Table/Fig-1].

Among the malignant thoracic lesions, adenocarcinoma was the most frequent (44) type of the malignant lesion, followed by squamous cell carcinoma (7). The incidence of malignant lesions was more in the elderly patients (50). Malignant lesions were observed majorly (39) in men, followed by women (20) [Table/Fig-2].

Parameter	n (%)	
Histopathological report	Benign	1 (1.67)
	Malignant	59 (98.33)
Malignant lesion	Primary	53 (89.83)
	Secondary	6 (10.17)
Type of malignant lesion	Adenocarcinoma	44 (74.58)
	Squamous cell carcinoma	7 (11.86)
	Lymphoma	5 (8.47)
	Small round cell carcinoma	1 (1.69)
	Malignant thymoma	1 (1.69)
	Seminoma	1 (1.69)
Lobe affected	Right upper lobe	15 (28.85)
	Right middle lobe	5 (9.62)
	Right lower lobe	14 (26.92)
	Left upper lobe	4 (7.69)
	Left lower lobe	14 (26.92)

[Table/Fig-2]: Histopathological characteristics of the samples.

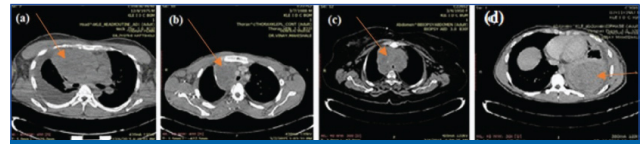
The parenchymal thoracic lesions were predominantly located in the right upper lobe (15) followed by right lower lobe (14) and left lower lobe (14) [Table/Fig-2].

The different signs of malignancy, as observed on CT are shown in [Table/Fig-3]. Irregular borders of the cells were observed in most (30) of the patients. The different types of malignant thoracic lesions and their locations are shown in [Table/Fig-4,5].

Postprocedural complications: The postprocedural complications were not observed in the majority (57) of the patients. However, post CT scans revealed pneumothorax in three patients [Table/Fig-6]. The patients were monitored until they were hemodynamically stable, after which CT was performed.

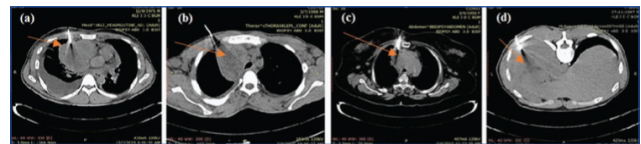
Imaging signs	N (%)
Irregular borders	30 (50.85)
Lymphadenopathy	9 (15.25)
Pleural effusion	6 (10.17)
Metastases	5 (8.47)
Necrosis	6 (10.17)
Thick walled cavity	2 (3.39)
Vascular invasion	1 (1.69)

[Table/Fig-3]: Imaging signs of malignancy.



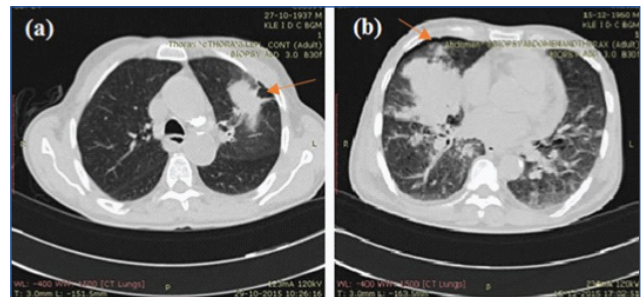
[Table/Fig-4]: Axial plain computed tomography images.

a) 62-year-old male with a right upper lobe mass lesion with pleural effusion [moderately differentiated adenocarcinoma]; b) 60-year-old female with large anterior mediastinal mass lesion [malignant thymoma]; c) 27-year-old male with a mass in the anterior mediastinum [lymphoma]; d) 60-year-old female with a large mass in the left lower lobe [small round-cell tumor] *Parenthesis indicates diagnosis upon histopathological confirmation.



[Table/Fig-5]: Axial computed tomography images with biopsy needle within the mass

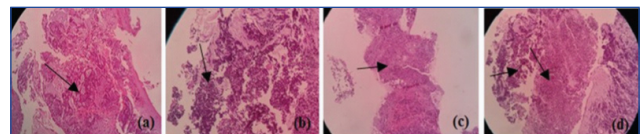
a) Moderately differentiated adenocarcinoma; b) malignant thymoma; c) lymphoma; d) small round-cell tumor



[Table/Fig-6]: CT axial lung window showing minimal pneumothorax; a) Poorly differentiated adenocarcinoma; b) moderately differentiated adenocarcinoma.

Spontaneous resolution of pneumothorax was observed during the CT and the patients were discharged later.

Sensitivity and predictive value of CT-guided core needle biopsy in diagnosing the presence of thoracic lesion and classifying as benign or malignant was 100%. The CT findings were in conjunction with the histopathology reports [Table/Fig-7].



[Table/Fig-7]: Histopathology images at 100x magnification.

a) Adenocarcinoma lung; b) Lymphoma lung (c) Malignant thymoma lung; (d) Small round-cell tumor lung

DISCUSSION

In the present study, the CT-guided core needle biopsy was efficient and safe in determining the benign and malignant thoracic lesions. A higher incidence of thoracic lesions was observed in men. It was similar to the study conducted by

Rangaswamy et al., in which 60 men and 23 women were reported with thoracic lesions[1]. In the current study, the most common age-group was 51-60 years, which was similar to the age-group of patients in a study performed by Saha et al., [15] Similarly, Shah et al., reported a high incidence of thoracic lesions in men and with a peak incidence in the age group of 50-70 years [16].

In the present study, thoracic lesions were predominantly located in the lung parenchyma, Saha et al., evaluated the efficacy of CT-guided fine needle aspiration cytology in thoracic mass lesions. They observed 54 cases of parenchymal tumors and three cases of lesions in the anterior mediastinum [13]. Rangaswamy et al. reported most of the lesions in the lung parenchyma, whereas in only four cases mediastinal thoracic lesions were reported [1]. However, in a study by Bakhshayeshkaram et al., majority (78) of the thoracic lesions were located in the mediastinum, whereas lesions in the chest wall were observed in 41 cases [17].

In the present study, according to the CT-guided core biopsy evaluation, majority of the lesions were malignant, which was confirmed by the histopathological reports. CT-guided evaluation of the lesions is useful in differentiating the benign and malignant lesions and aids in implementing therapeutic measures in treating the lesion. It is the most accurate and sensitive way of diagnosing malignancy [13,18-19]. In the study conducted by Saha et al., of the 57 cases with thoracic lesions, 54 were malignant and three were benign. In a study by Rangaswamy et al., out of 70 cases, malignant and benign lesions accounted for 47 and 23 cases, respectively [1]. Arslan et al. reported 259 malignant pulmonary lesions of the 316 patients who underwent CT-guided trans-thoracic fine needle aspiration [20]. In a study by Uskul et al., malignancy was observed in 122 of the 134 cases with pulmonary lesions [21].

The histological types and signs of malignancy and the precise location of the pulmonary lesion were also determined by CT-guided core biopsy. Adenocarcinoma was the most common type of malignancy in the cases. The right upper lobe was affected in most of the cases in the present study. Irregular borders of the pulmonary cells were the main sign of malignancy in these cases. Some studies [21, 22] reported adenocarcinoma as the main histopathological type of malignancy, whereas few other studies[1, 15] reported squamous cell carcinoma followed by adenocarcinoma as the major histopathological type. Similar to the findings of the present study, Bakhshayeshkaram et al. reported majority (182) of the lesions in the right upper lobe [17]. Uskul et al. also reported 76 cases of right lung lesions with the majority (52) of them located in the right upper lobe [21].

Although, CT-guided core needle biopsy was safe in most of the patients, complications including pneumothorax were observed in few patients. However, the sensitivity and specificity of the procedure was 100% in the present study. False-positive diagnosis was not detected for malignancy. In a

study by Uskul et al., the sensitivity and specificity of detecting malignancy by CT-guided transthoracic fine needle aspiration (TFNA) was 84% and 100%, respectively [22]. Arslan et al. reported 88% and 100% sensitivity and specificity, respectively, in CT guided TFNA [21]. The findings of the present study are comparable with the other studies in the literature [19,20].

Early diagnosis of thoracic lesions, especially in bronchogenic carcinoma, is required for better prognosis and can be achieved by CT-guided core needle biopsy. Percutaneous CT-guided biopsy is a relatively simple and minimally invasive procedure, which has better patient acceptance, low morbidity, and negligible mortality rate [23,24]. In all the patients, the verification of CT guided cytological findings was confirmed by histopathological examinations. Adequate tissue sample, required for histopathological studies, can be accurately procured by this method. Moreover, this procedure is safe, rapid, and accurate, which aids in examining the small thoracic mass lesions and deep mediastinal nodes without affecting adjacent blood vessels and cardiac structures [25,26]. According to literature, this procedure is an accurate and sensitive technique in detecting malignancy of the lungs [27,28].

LIMITATION

Cross-sectional single-center study design of the present study is a limitation of the study. Further studies in large samples are required to validate the findings and generalize it to other population of patients.

CONCLUSION

CT-guided core needle biopsy is a safe, rapid, effective, and reliable method with high sensitivity and specificity. The technique aids in meticulous subclassification of the lesions and detection of benign non-neoplastic lesions based on cytomorphology. Although complications occur, they are rare and easily manageable. Therefore, it is a highly accurate technique in the diagnosis and evaluation of benign and malignant thoracic lesions.

ACKNOWLEDGEMENT

Authors kindly acknowledge all the patients for participation in the study.

REFERENCES

- [1] Rangaswamy M, Zacharia TT, Krishnamurthy J, Chennakeshavaiah G, Sunila, Vimala MG. Study of computed tomography-guided fine needle aspiration cytology of thoracic lesions. *J Cytol.* 2012;29(1):30-34.
- [2] Khosla R, McLean AW, Smith JA. Ultrasound-guided versus computed tomography-scan guided biopsy of pleural-based lung lesions. *Lung India.* 2016;33(5):487-92.
- [3] Rivera MP, Mehta AC, Wahidi MM. Establishing the diagnosis of lung cancer: Diagnosis and management of lung cancer: American College of Chest Physicians evidence-based clinical practice guidelines. *Chest.* 2013;143(5 Suppl):e142S-e165S.
- [4] Ghaye B, Dondelinger R. Imaging guided thoracic interventions. *Eur Respir J.* 2001 Mar;17(3):507-28.

- [5] Thulkar S. Image guided biopsy procedures. *Indian Journal of Medical and Paediatric Oncology*. 2007;28(2):5.
- [6] Nnhire A, Charig M, Clelland C, Gleeson F, Miller R, Moss H et al. Guidelines for radiologically guided lung biopsy. *Thorax*. 2003;58(11): 920-36.
- [7] Shaham D. Semi-invasive and invasive procedures for the diagnosis and staging of lung cancer. *Raidol Clin North Am*. 2000;38:525-34.
- [8] Bungay HK, Pal CR, Davies CWH. An evaluation of CT as an aid to diagnosis in patients undergoing bronchoscopy for suspected bronchial carcinoma. *Clin Radiol*. 2000; 55:554-60.
- [9] Caruthers DM, Connor S, Howie AJ. Percutaneous image-guided biopsy of lung nodules in the assessment of disease activity in Wegener's granulomatosis. *Rheumatology*. 2000;39:776-82.
- [10] Klein JS, Zarka MA. Transthoracic needle biopsy. *Radiologic Clinics of North America*. 2000;38(2):235-66.
- [11] Yang P-C. Ultrasound-guided transthoracic biopsy of the chest. *Radiologic Clinics of North America*. 2000;38(2):323-43.
- [12] Singh JP, Garg L, Setia V. Computed tomography (CT) guided transthoracic needle aspiration cytology in difficult thoracic mass lesions-not approachable by USG. *Indian J Radiol Imaging*. 2004;14(4):395.
- [13] Begum SN, Ekram AR, Uddin D, Islam QT, Bhaduri J. Diagnostic accuracy of ultrasound versus computed tomographic guided fine needle aspiration cytology. *Anwer Khan Modern Medical College Journal*. 2010;1(1):9-14.
- [14] Suresh P. A study of yield of ct-guided interventions (core needle biopsy and fine needle aspiration cytology) in thoracic lesions and the complications faced during the interventions. *Journal of Evidence Based Medicine and Healthcare*. 2017;49(4): 3002-07.
- [15] Saha A, Kumar K, Choudhuri MK. Computed tomography-guided fine needle aspiration cytology of thoracic mass lesions: A study of 57 cases. *J Cytol*. 2009;26(2):55.
- [16] Shah S, Shukla K, Patel P. Role of fine needle aspiration cytology in diagnosis of lung tumours -a study of 100 cases. *Indian J Pathol Microbiol*. 2007;50(1):56-58.
- [17] Bakhshayeshkaram M, Graill P, Zahirifard S. CT guided biopsy of thoracic lesions. *European Respiratory Journal*. 2011;38(Suppl 55):p3664.
- [18] Mullan CP, Kelly BE, Ellis PK, Hughes S, Anderson N, McCluggage WG. CT-guided fine-needle aspiration of lung nodules: effect on outcome of using coaxial technique and immediate cytological evaluation. *Ulster Med J*. 2004;73(1):32-36.
- [19] Ko JP, Shepard JO, Drucker EA, Aquino SL, Sharma A, Sabloff B, et al. Factors influencing pneumothorax rate at lung biopsy: are dwell time and angle of pleural puncture contributing factors? *Radiology*. 2001;218(2):491-96.
- [20] Arslan S, Yilmaz A, Bayramgürler B, Uzman Ö, Ünver E, Akkaya E. CT-guided transthoracic fine needle aspiration of pulmonary lesions: accuracy and complications in 294 patients. *Medical Science Monitor*. 2002;8(7):CR493-97.
- [21] Uskül B, Türker H, Gökçe M, Kant A, Arslan S, Turan FE. CT-guided transthoracic fine needle aspiration of pulmonary lesions: accuracy and complications in 134 cases. *Tuberk Toraks*. 2009;57(2):177-85.
- [22] Carazzai EH, Andreosi M, Gonzalez FM, Gonzalez SdQU, Tornin OdS, Rossi MDA. Percutaneous computed tomography-guided biopsy of the lung: data from a hospital. *Radiologia Brasileira*. 2006;39(4):277-282.
- [23] Halloush RA, Khasawneh FA, Saleh HA, Soubani AO, Piskorowski TJ, Al-Abbadi MA. Fine needle aspiration cytology of lung lesions: a clinicopathological and cytopathological review of 150 cases with emphasis on the relation between the number of passes and the incidence of pneumothorax. *Cytopathology*. 2007;18(1):44-51.
- [24] Priola AM, Priola SM, Cataldi A, Errico L, Di Franco M, Campisi P. Accuracy of CT-guided transthoracic needle biopsy of lung lesions: factors affecting diagnostic yield. *Radiol Med*. 2007;112:1142-59.
- [25] Hasanovic A, Rekhman N, Sigel CS, Moreira AL. Advances in fine needle aspiration cytology for the diagnosis of pulmonary carcinoma. *Pathology Research International*. Vol. 2011, Article ID 897292, 7 pages, 2011.
- [26] Sing JP, Garg L, Setia V. Compared tomography (CT) guided transthoracic needle aspiration cytology in difficult thoracic mass lesions - not approachable by USG. *Indian J Radiol Imaging*. 2004;14:395-400.
- [27] Wallace MJ, Krishnamurthy S, Broemeling LD, Gupta S, Ahrar K, Morello FA Jr, et al. CT-guided percutaneous fine-needle aspiration biopsy of small (≤ 1 -cm) pulmonary lesions. *Radiology*. 2002;225(3):823-28.
- [28] Priola AM, Priola SM, Cataldi A, Di Franco M, Pazè F, Marci V, et al. Diagnostic accuracy and complication rate of CT-guided fine needle aspiration biopsy of lung lesions: a study based on the experience of the cytopathologist. *Acta Radiol*. 2010;51(5):527-33.

AUTHOR(S):

1. Dr. Pradeep S Goudar
2. Dr. Ashwin S Patil
3. Dr. Virupaxi V Hattiholi
4. Dr. Adarsh Sanikop

PARTICULARS OF CONTRIBUTORS:

1. Assistant Professor, Department of Radiology, Jawaharlal Nehru Medical College, Nehru Nagar KLE University, Belagavi, Karnataka, India.
2. Professor and Head, Department of Radiology, Jawaharlal Nehru Medical College, Nehru Nagar KLE University, Belagavi, Karnataka, India.
3. Professor, Department of Radiology, Jawaharlal Nehru Medical College, Nehru Nagar KLE University, Belagavi, Karnataka, India.

4. Assistant Professor, Department of Radiology, Jawaharlal Nehru Medical College, Nehru Nagar KLE University, Belagavi, Karnataka, India

NAME, ADDRESS, E-MAIL ID OF THE CORRESPONDING AUTHOR:

Dr. Virupaxi V Hattiholi,
KLE University, Belagavi, Karnataka, India.
E-mail: dochattiholi@yahoo.co.in

FINANCIAL OR OTHER COMPETING INTERESTS:

None.

Date of Publishing: Oct 01, 2018