

# Aberrant Right Posterior Sectoral Duct Draining in Cystic Duct - An Interesting Intraoperative Challenge

ANIRUDDHA BHOSALE, AKHILESHWAR SINGH

## ABSTRACT

Misinterpretation of intraoperative biliary anatomy is the most common cause of biliary injuries during laparoscopic cholecystectomy. These potentially avoidable injuries may lead to considerable morbidities in the form of biliary leaks, sepsis, jaundice or cirrhosis. Clear knowledge of biliary anatomy and strict adherence to the principles of surgery can avoid most of these injuries. Many variations in bile duct anatomy are seen but the most important from an operative view point are those pertaining to the cystic duct

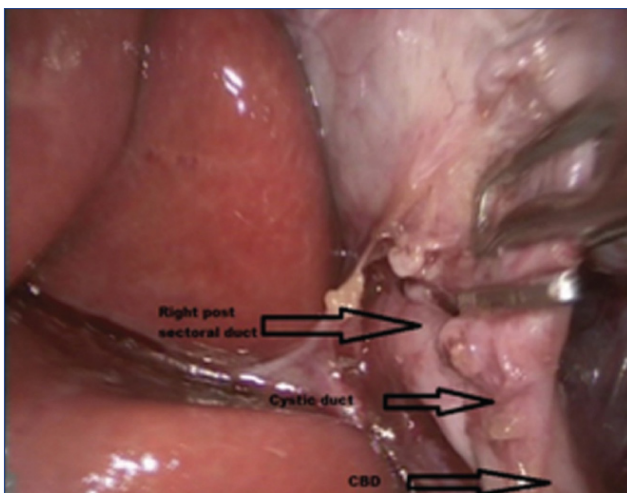
and right sectoral ducts. Right posterior sectoral ducts draining into cystic duct are potentially dangerous and very rare. The reported incidence of this anomaly is less than 2.9%. We report a similar case from our department, where during laparoscopic cholecystectomy an aberrant right posterior sectoral duct was encountered draining into cystic duct just distal to the neck of gallbladder. Cholecystectomy was completed laparoscopically with no post-operative complications.

**Keywords:** Biliary anomalies, Biliary injury, Cholecystectomy, Laparoscopy

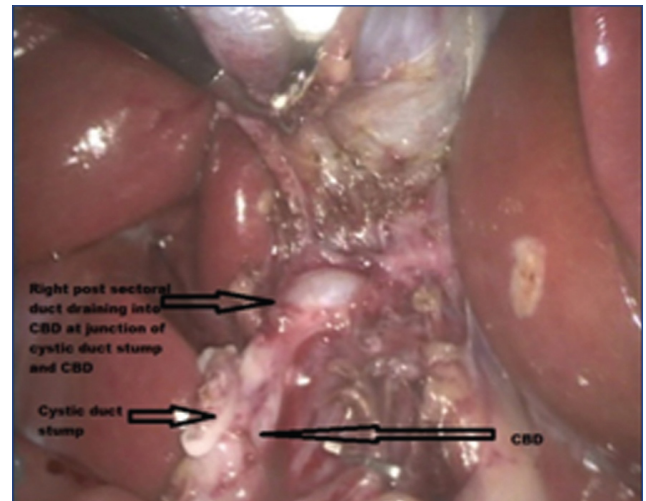
## CASE REPORT

A 41-year-old female with no other co-morbidities was admitted at our department with symptoms of dyspepsia and biliary colic since four months. Her abdominal sonography showed 18 mm gallbladder calculus, normal common bile duct and liver. Her liver function tests were within normal limits. Patient was posted for laparoscopic cholecystectomy. Intraoperatively, during dissection of cystic duct at Calot's triangle, an aberrant duct was observed entering the cystic duct just distal to gallbladder neck. On posterior dissection

it was found to originate from inferior liver surface near gallbladder fossa [Table/Fig-1]. Critical view of safety was established. It was found to be aberrant right posterior sectoral duct draining into cystic duct. After careful blunt dissection, clips were applied above the junction of cystic duct and right aberrant sectoral duct. Gallbladder with tiny cystic duct stump was divided above the clip, preserving the junction of aberrant duct and distal cystic duct draining into common bile duct. No intraoperative bile leak was present. Cholecystectomy was completed laparoscopically [Table/Fig-2]. Patient recovered



**[Table/Fig-1]:** Right posterior sectoral duct entering cystic duct just distal to gallbladder neck. Cystic duct is clipped above junction.



**[Table/Fig-2]:** After division of cystic duct. No bile leak or obstruction. Intact junction between distal cystic duct with right posterior sectoral duct, draining into common bile duct.

well post operatively and was discharged on post operative Day three. On follow up, patient was asymptomatic, her liver function tests and abdominal sonography were normal.

## DISCUSSION

Congenital anomalies of the biliary tree are seen in about 19-39% of individuals [1]. Bile duct anomalies are broadly classified into two- a) aberrant ducts b) accessory ducts. Aberrant ducts are normal ducts with abnormal course or drainage. Most common variations are: trifurcation of the common hepatic duct; right anterior sectoral duct draining into left hepatic duct; right posterior duct draining into right anterior duct, left or common hepatic duct, common bile duct, cystic duct; the insertion of the cystic duct into the right hepatic duct.

Accessory duct is separate channel in addition to the normal draining ducts, like duct of Luschka [2]. Accessory duct may drain a segment of liver into the common hepatic duct, cystic duct or gallbladder.

Anomalous right posterior sectoral duct occurs in around 2-7% of patients [1]. This anomalous duct can drain into common hepatic duct, gallbladder neck, cystic duct or left hepatic duct, potentially exposing it to the risk of injury during laparoscopic as well as open cholecystectomy. Right posterior sectoral duct provides the drainage for hepatic segments six and seven. Low insertion of the right posterior sectoral bile duct into the cystic duct is very rare with reported incidence less than 2.9%. Peunte SG et al., reported this anomaly in one of 4264 patients while Kullman E et al., found in 2.9% of 513 patients [1,3]. This duct can be mistaken for cystic duct and clipped during surgery leading to obstruction of biliary drainage [4]. Alternatively, this duct can be divided leading to biliary leak. Sectoral duct injuries may lead to significant post operative morbidity [5].

Bile duct injuries occur in both laparoscopic and open cholecystectomies with incidence ranging from 0.06-2% [6,7]. Biliary injuries are mainly due visual misperception during dissection rather than the presence of the anatomical variation [8]. These biliary injuries can present as biliary leak or duct stenosis/obstruction. Accidental injury causing bile leak may lead to bilioma, biliary peritonitis and sepsis. While accidental ligation of these ducts leads to obstruction and may give rise to jaundice, cholangitis, atrophy of liver segment and cirrhosis. Clinical outcome of these cases depends on severity of leak/obstruction and symptoms. Many of these cases can be managed with conservative measures. However, cases with significant symptoms may need surgical treatment which may range up to hepaticojejunostomy or partial liver resection. Morbidity associated with these complications and their management can be very high.

Prevention of these complications can be achieved with accurate information of anatomy and strict adherence

with surgical principles. Preoperative Magnetic Resonance Cholangiopancreatography (MRCP) and pre or intra operative cholangiography can give detailed anatomical information of biliary tree [9]. However, these investigations are not routinely used. Benefits of routine use of intraoperative cholangiography are debatable [10]. Moreover, these biliary leaks may not be visible on endoscopic retrograde cholangiogram.

Surgical principles to avoid biliary injuries include obtaining critical view of safety of cystic duct and artery before ligating or dividing any structure near Calot's triangle [11,12]. It includes: a) Avoiding dissection below the Rouviere's sulcus; b) Clearing of fibro fatty tissue in hepatocystic triangle; c) Identification of only two structures in Calot's triangle, one artery and one duct; d) Circumferential dissection of cystic duct and gallbladder neck; e) Completely dissecting lower part of gallbladder from liver bed. Surgeons should always keep these points in mind while performing cholecystectomy to avoid iatrogenic biliary injuries.

## CONCLUSION

Laparoscopic cholecystectomy is one of the common operative procedures in surgical practice. Yet biliary injuries remain a challenge for surgeons. It is a well established fact that most injuries occur not because of aberrant anatomy but are due to visual misinterpretation. Hence, to avoid such injuries the most important factors are good understanding of biliary anatomy and strictly following the operative principles of surgery. Aberrant sectoral duct injuries have been mentioned in literature and can be associated with significant post operative morbidity. These injuries can be prevented by following simple common measures. Such cases help surgeons to avoid these injuries. A famous saying in surgical practice applies to these cases 'don't see what u believe, but believe what you see'.

## REFERENCES

- [1] Puente SG, Bannura GC. Radiological anatomy of the biliary tract: variations and congenital abnormalities. *World J Surg.* 1983;7(2):271-76.
- [2] Doumenc B, Boutros M, Dégremont R, Bouras AF. Biliary leakage from gallbladder bed after cholecystectomy: Luschka duct or hepaticocholecystic duct? *Morphologie.* 2016;100(328):36-40.
- [3] Kullman E, Borch K, Lindström E, Svanvik J, Anderberg B. Value of routine intraoperative cholangiography in detecting aberrant bile ducts and bile duct injuries during laparoscopic cholecystectomy. *Br J Surg.* 1996;83(2):171-75.
- [4] Babel N, Sakpal S, Paragi P, Wellen J, Feldman S, Chamberlain R. Iatrogenic bile duct injury associated with anomalies of the right hepatic sectoral ducts: a misunderstood and underappreciated problem. *HPB Surg.* 2009. Pp:153269.
- [5] Othman B, Houli N. Management of sectoral bile duct injury during laparoscopic cholecystectomy-experience from a tertiary centre. *HPB* 18. 2016. Pp:e499.
- [6] Fullum TM, Downing SR, Ortega G, Chang DC, Oyetunji TA, Van Kirk K, et al. Is laparoscopy a risk factor for bile duct injury during cholecystectomy? *JLS.* 2013;17(3):365-70.

- [7] Pekolj J, Alvarez FA, Palavecino M, Sánchez Clariá R, Mazza O, et al. Intraoperative management and repair of bile duct injuries sustained during 10,123 laparoscopic cholecystectomies in a high-volume referral center. *J Am Coll Surg.* 2013;216(5):894-901.
- [8] Wojcicki M, Patkowski W, Chmurowicz T, Bialek A, Wiechowska-Kozłowska A, Stankiewicz R, et al. Isolated right posterior bile duct injury following cholecystectomy: Report of two cases. *World J Gastroenterol.* 2013; 19(36): 6118-21.
- [9] Snow H, Chowdhury A, Bui H. Management of an injured accessory hepatic duct during laparoscopic cholecystectomy: The importance of operative cholangiography. *J Case Rep Images Surg.* 2015;1:01-04.
- [10] Ford JA, Soop M, Du J, Loveday BP, Rodgers M. Systematic review of intraoperative cholangiography in cholecystectomy. *Br J Surg.* 2012;99(2):160-67.
- [11] Onder H, Ozdemir MS, Tekba G, Ekici F, Gümü H, Bilici A. 3-T MRI of the biliary tract variations. *Surg Radiol Anat.* 2013;35(2):161-67.
- [12] Strasberg SM, Brunt LM. Rationale and use of the critical view of safety in laparoscopic cholecystectomy. *J Am Coll Surg.* 2010;211(1):132-38.

**AUTHOR(S):**

1. Dr. Aniruddha Bhosale
2. Dr. Akhileshwar Singh

**PARTICULARS OF CONTRIBUTORS:**

1. Junior Consultant, Department of General Surgery, Sahyadri Speciality Hospital, Pune, Maharashtra, India.
2. Resident Trainee, Department of General Surgery, Sahyadri Speciality Hospital, Pune, Maharashtra, India.

**NAME, ADDRESS, E-MAIL ID OF THE CORRESPONDING AUTHOR:**

Dr. Aniruddha Bhosale,  
Flat No.-16, Takshak Appartment, Nagala Park, Kolhapur,  
Maharashtra-416003, India.  
E-mail: aniruddhabhosale@rediffmail.com

**FINANCIAL OR OTHER COMPETING INTERESTS:**

None.

Date of Publishing: Jul 01, 2018