

# Transnasal Endoscopic-assisted Conventional Adenoidectomy: A Study of 45 Cases

LAKSHMI ANANTH, PRADEEP HOSAMANI

## ABSTRACT

**Introduction:** Adenoidectomy is one of the most common surgery performed in children. Conventional curettage adenoidectomy has the advantage of being low cost and continues to be a commonly used method especially in developing countries. In this paper, we study conventional curettage adenoidectomy performed under endoscopic guidance with additional endoscopic removal of remnant tissue.

**Aim:** To study the efficacy of transnasal total endoscopic-guided adenoidectomy using conventional instruments.

**Materials and Methods:** This prospective study was conducted in the Department of Otorhinolaryngology at BGS Global Hospital, Bengaluru, India over a period of three years from January 2012 to December 2014. Total 45 children in the age range of 4 to 15 years with

adenoid hypertrophy who underwent endoscopic-guided adenoidectomy during the study period were included in the study. Preoperative assessment was done by clinical scoring and nasal endoscopic grading. About 76% cases had Grade IV adenoids and 24% Grade III.

Conventional curettage of adenoids was done under transnasal endoscopic visualisation with additional endoscopic removal of remnant tissue. Near total or total removal was achieved in all cases.

**Results:** Symptom scoring and nasal endoscopy done 6 months postoperatively show no adenoid remnant in 13.3% cases, Grade I in 80%, and Grade II in 6.66%. 16±1.5 minutes was the mean time taken for the surgery.

**Conclusion:** The addition of endoscopic visualisation appears to greatly improve the outcomes of conventional curettage adenoidectomy without major complications.

**Keywords:** Adenoids, Endoscopes, Nasal obstruction, Transnasal endoscopic surgery

## INTRODUCTION

Adenoid hypertrophy is a common condition in children causing symptoms such as nasal obstruction, nasal discharge, mouth breathing, snoring, sleep apnoea and other sleep related breathing disorders besides contributing to rhinosinusitis, recurrent otitis media and otitis media with effusion [1]. Adenoidectomy is among the most commonly performed surgical procedures in the paediatric population [2].

Conventional curettage adenoidectomy was first described in 1885 [3]. Many newer methods and techniques have since been described and include the use of suction diathermy [4], electrocautery [5], microdebrider [6], laser [7], coblation [7] and endoscopes [8]. Each method has advantages and disadvantages in terms of outcome, complications, operative time and cost.

Conventional curettage adenoidectomy has the advantage of being low cost and continues to be a commonly used

method especially in developing countries. However, it is a blind procedure that frequently results in complications and incomplete removal [9]. The advent of endoscopes has greatly improved nasal and sinus surgery by allowing the procedures to be performed under direct visualisation. In this paper, we study conventional curettage adenoidectomy performed under endoscopic guidance with additional endoscopic removal of remnant tissue. In this study the endoscope was used throughout the procedure, unlike in many other series, where endoscope was used only to visualise the remnant of adenoid tissue, hence named it total endoscopic-guided adenoidectomy

## MATERIALS AND METHODS

This study was performed prospectively in the Department of Otorhinolaryngology at BGS Global Hospital, Bengaluru, India over a period of three years from January 2012 to December 2014. This study was approved by the ethics committee

of BGS Global Hospital. Written informed consents were obtained from the parents of all the patients. All the cases performed during the study period were considered for the study.

A total of 45 children between the age of 4 to 15 years were included. Their symptoms included snoring, recurrent nasal obstruction, recurrent nasal discharge, mouth breathing, earache and decreased hearing. Patients undergoing adenoidectomy with myringotomy with/without grommet insertion were included in the study. Patients undergoing adenoidectomy along with tonsillectomy (so as to overcome the bias of time taken, complications which is unrelated to adenoidectomy), septoplasty, FESS and turbinate surgery were excluded. Patients with cleft palate, submucous cleft and/or previous cleft palate surgery, septal deviation and nasal polyps were excluded from the study group. Cases with bleeding or coagulation disorders were excluded as were cases with missed follow-up.

Thorough preoperative assessment was done in the form of history, clinical examination, radiograph of nasopharynx, tympanometry in cases with middle ear effusion and lab investigations for operative procedure. A preoperative symptom score was calculated using the subjective variables mouth breathing, nasal obstruction and nasal discharge and snoring [10]. The total symptom score ranged from 0-12 [11] [Table/Fig-1].

Symptoms	Absent	Occasionally Present	Frequently Present	Constantly Present
Mouth Breathing	0	1	2	3
Nasal Obstruction	0	1	2	3
Nasal Discharge	0	1	2	3
Mouth Breathing	0	1	2	3

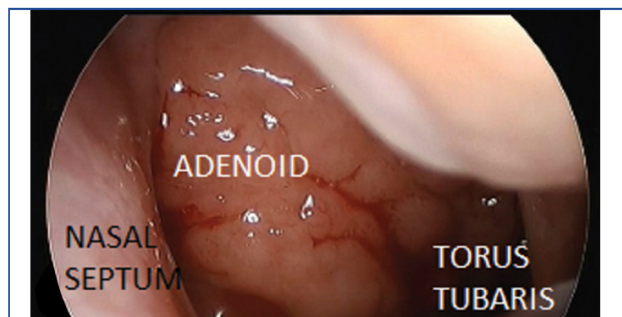
[Table/Fig-1]: Symptom Scoring.

### Operative Technique

All cases were done under general anaesthesia with orotracheal intubation. The patient was put in recumbent neutral position and the head stabilised with a ring support. The nasal cavities were packed with patties soaked in normal saline with 1:10000 adrenaline for 10 minutes to shrink the nasal mucosa.

Boyle Davis mouth gag with tongue blade was applied. A 4 mm or 2.7 mm 00 nasal endoscope with attached camera system was inserted transnasally to the nasopharynx [Table/Fig-2] and grading of adenoid tissue was done using the grading scale described by Parikh S et al., [12] [Table/Fig-3].

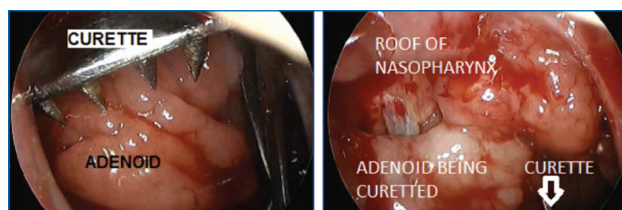
Keeping the nasopharynx under vision, an adenoid curette was applied transorally to reach the upper limit of the adenoid



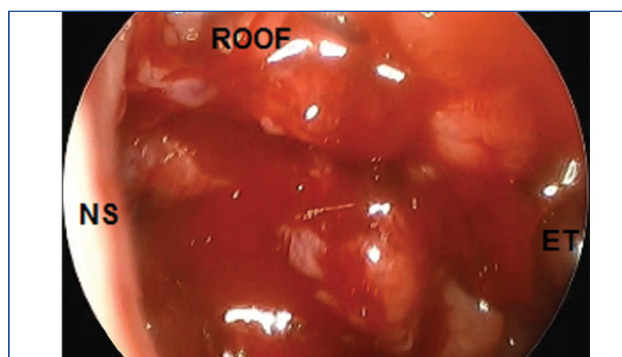
[Table/Fig-2]: Showing Grade III adenoids.

Grades	Anatomic structures in contact with adenoid tissue seen on nasal endoscopy
Grade I	None
Grade II	Torus tubaris
Grade III	Torus tubaris and vomer
Grade IV	Torus tubaris, vomer and soft palate (at rest)

[Table/Fig-3]: Grading of adenoid hypertrophy.



[Table/Fig-4]: Showing application of curette under endoscopic visualisation. [Table/Fig-5]: Showing curettage being done under endoscopic visualisation.



[Table/Fig-6]: Showing nasopharynx following curettage.

tissue and curettage done [Table/Fig-4,5]. Curettage was repeated two to three times as necessary with intermittent saline-soaked gauze pack application in the nasopharynx for haemostasis.

The nasopharynx was re-assessed for completeness of the surgery. Any remnant tissue was removed using straight or upturned Blakesley forceps inserted transnasally. Total or near-total (upto grade I or <25%) removal was the goal of the surgery [Table/Fig-6]. Haemostasis was achieved by packing the nasopharynx and the use of bipolar electrocautery under endoscopic guidance in some cases. The patients were discharged after 24 hours with an oral antibiotic and

decongestant nasal drops. They were followed up weekly for two weeks and then after one, three and six months. At the sixth month follow-up visit, patients were assessed by both symptom scoring and nasal endoscopy.

## STATISTICAL ANALYSIS

All the data assembled was presented as mean±standard deviation. Results were analyzed using SPSS version 23.0 software with the help of Student-'t'-test. The p-value <0.05 was considered as statistically significant.

## RESULTS

Of the 45 patients included in the study, 24 (53%) were male and 21 (47%) were female. Their age ranged from 4 to 15 years with a mean of 8.16 years.

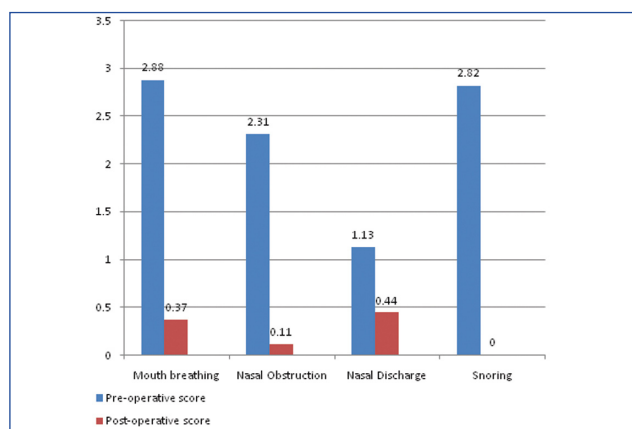
In the preoperative symptom scoring, mouth breathing had an average score of 2.88 (ranging from 2 to 3), nasal obstruction had a mean score of 2.31 (ranging from 1 to 3), nasal discharge 1.13 (ranging from 0 to 3) while snoring had an average score of 2.82 (ranging from 0 to 3).

On preoperative endoscopy, 34 cases (76%) showed Grade IV adenoids, 11 cases (24%) had Grade III, while no case showed Grade I or Grade II adenoid hypertrophy.

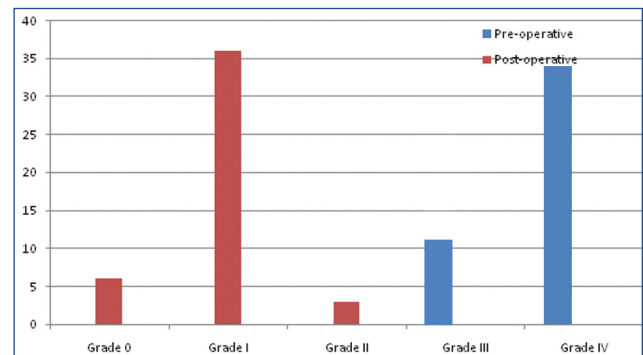
Patients with Grade IV adenoids had a mean symptom score of 9.67 while those with Grade III adenoids had a mean score of 7.45.

Postoperatively, nasal endoscopy showed no remnant adenoid tissue in 6 (13.3%) cases, Grade I adenoids in 36 (80%) patients (near total refers to this percentage, which was less than 25% of tissue and were termed as Grade I adenoid), Grade II in 3 (6.66%) patients. The postoperative symptom score for mouth breathing was 0.37 (ranging from 0 to 1), nasal obstruction a mean score of 0.11 (ranging from 0 to 1) and nasal discharge 0.44 (ranging from 0 to 1) [Table/Fig-7,8]. There were no cases of snoring postoperatively, hence the score was zero. The improvement in post-operative symptom score was statistically significant ( $p < 0.05$ ).

The time taken for surgery ranged from 10 minutes to 20



[Table/Fig-7]: Preoperative and postoperative symptom scoring.



[Table/Fig-8]: Preoperative and postoperative grading of Adenoids.

minutes with a mean of  $16 \pm 1.5$  minutes (10 unilateral and four bilateral VTIs done, time does not include VTI). Time was calculated from after intubation until complete haemostasis was achieved and handed over to the anaesthesiologist.

## DISCUSSION

Adenoidectomy is a commonly performed surgery at most centres. Conventional curettage adenoidectomy is a low cost procedure that does not require special or expensive equipment and can easily be performed even in centres without advanced operation theatre setups. But it is a blind procedure where neither the tip of the curette nor the tissue being curetted out is under direct visualisation. Cannon CR et al., [13] and Saxby and Chappel [14] endoscopically demonstrated that substantial amounts of adenoid tissue are left behind following conventional curettage adenoidectomy. Zaina V, stated that several studies suggested conventional curettage adenoidectomy resulted in the retention of up to 34.3% of the total preoperative adenoid tissue volume [15]. The visual constraints of the procedure can also lead to injury to surrounding structures in the nasopharynx [9].

Many methods have been tried over time to overcome this problem. Laryngeal mirrors were used for indirect visualisation of the adenoids during adenoidectomy by Pearl and Manoukian [16]. The advent of nasal endoscopes greatly improved visualisation in nasal and sinus surgery. But along with endoscopes there have also been advances in instrumentation in the form of microdebriders and laser. These have been employed in adenoid surgery over the past few years, each with its own merits and shortcomings. However, almost all of these procedures require special and often expensive equipment that are not universally available at all centres.

Several studies report the use of endoscopes to improve visualisation in adenoidectomy. Kamel RA and Ishak EA, described transnasal endoscopic adenoidectomy in adults using endoscopic instruments [17]. Becker SP et al., reported using endoscopic adenoidectomy in the treatment of adolescents with serous otitis media and large adenoids covering the eustachian tube orifice [18]. Schaffer SR and Wong GH presented their series of transoral endoscopic

adenoidectomy and observed that the procedure involved a short learning curve [19].

Endoscopic visualisation also aids complete engagement of the adenoid tissue particularly in the superomedial part of choana and helps more complete curettage. Initial engagement of the superior most part of adenoid tissue under endoscopic guidance can remove most of it. Any remnant was removed using straight or 450 Blakesley forceps. Yaman H et al., recommended inspection of adenoid remnant after conventional curettage and removal of remnant adenoid tissue under endoscopic guidance, which saved time compared to transnasal endoscopic method [1]. But, we recommend using the zero degree endoscope from the beginning of the surgery where the diagnosis is confirmed, adenoid size assessed and the curette engaged under vision.

Total (where complete adenoid tissue was removed and where pharyngobasilar fascia was seen) or near total (where some adenoid tissue remains and was not obstructing the choana) adenoidectomy was achieved in all cases. Nasal endoscopy done six months after the procedure showed no remnant adenoid tissue in 6 (13.3%) cases, Grade I adenoids in 36 (80%) patients and Grade II in 3 (6.66%), giving a success rate of 93.3% where we defined success as total or near total removal with Grade I or less remnant adenoid tissue. Over a two year follow-up period, none of the patients required revision surgery.

The time taken for surgery ranged from 10 minutes to 20 minutes with a mean of  $16 \pm 1.5$  minutes. This is comparable to a meta analysis done by Yang L et al., [20], where the operative time was 8.5 to 17.38 minutes in the conventional group and 5.25 to 11.82 minutes in the endoscopic adenoidectomy group, where the endoscopic group underwent powered adenoidectomy. It was observed that curettage itself under endoscopic visualisation did not take much more time than conventional curettage adenoidectomy. But removal of tags especially the more laterally placed tissue took more time. Though, Huang HM et al., reported that in patients with large adenoid tissue volume this technique requires more time than conventional surgery [21], we had 76% of Grade IV adenoids indicating large adenoid tissue volume, but the time taken was comparable.

The complications we encountered were nasal crusting in nine cases initially, which resolved in a week on using normal saline nasal sprays. We had to use bipolar coagulation per operatively in three cases for haemostasis.

## LIMITATION

Our study has some limitations like longer period of follow-up could evaluate the long term efficacy of the procedure. The study sample is relatively small, a study with larger series with larger cohort is recommended.

## CONCLUSION

Transnasal endoscopic adenoidectomy has the advantage of direct visualisation of the surgical field throughout the procedure, which in turn avoid complications encountered in conventional curettage adenoidectomy. Moreover, this technique ensures near complete removal of adenoid tissue reducing the recurrence rates, which may not be achieved with conventional adenoidectomy. It does not add to the cost of the procedure as endoscopes are available in majority of centres performing nasal surgeries. We recommend transnasal endoscopic adenoidectomy should be performed instead of conventional adenoidectomy in all patients for better results and to avoid complications.

## REFERENCES

- [1] Yaman H, Memis M, Ilhan E. Comparison of transoral/transnasal endoscopic-guided adenoidectomy with endoscopic nasopharyngeal inspection at the end of curettage adenoidectomy. *Indian J Otolaryngol Head Neck Surg.* 2015;67(2):124-27.
- [2] Fabio Pagella, Alessandro Pusateri, Georgios Giourgos and Elina Matti. Evolution of Adenoidectomy in the Endoscopic Era. In: Prof. Cornel Iancu. *Advances in Endoscopic Surgery* [Internet]. 1st Ed. InTech. 2011. Chapter 8. [Available from] <http://cdn.intechweb.org/pdfs/24327.pdf>
- [3] Thornval A, Wilhem Meyer and the adenoids. *Arch Otolaryngol.* 1969;90(3):383-86.
- [4] Walker P. Pediatric adenoidectomy under vision using suction-diathermy ablation. *Laryngoscope.* 2001;111(12):2173-77.
- [5] Elluru RG, Johnson L, Myer CM 3<sup>rd</sup>. Electrocutery adenoidectomy compared with curettage and power assisted methods. *Laryngoscope.* 2002;112(8 Pt 2 Suppl 100):23-25.
- [6] Sorin A, Bent JP, April MM, Ward RF. Complications of Microdebrider-assisted powered intracapsular tonsillectomy and adenoidectomy. *Laryngoscope.* 2004;114(2):297-300.
- [7] Özkiriş M, Karaçavuş S, Kapusuz Z, Saydam L. Comparison of two different adenoidectomy techniques with special emphasize on post operative nasal mucociliary clearance rates: coblation technique vs cold curettage. *Int J Pediatr Otorhinolaryngol.* 2013;77(3):389-93.
- [8] Shin JJ, Hartrick CJ. Pediatric endoscopic transnasal adenoid ablation. *Ann Otol Rhinol Laryngol.* 2003;112(6):511-14.
- [9] Regmi D, Mathur NN, Bhattarai M. Rigid endoscopic evaluation of conventional curettage adenoidectomy. *J Laryngol Otol.* 2011;125(1):53-58.
- [10] Madiseti S, Muppidi V, Jadi L, Prabhakar Reddy K, Batchu D. Does intranasal steroids reduce the need of adenoidectomy in adenoid hypertrophy. *J Evid Based Med Healthc.* 2017;4(47):2871-75. [Available from] [https://www.jebmh.com/data\\_pdf/Jadi%20Lingaiah%20-%203%20-%20FINAL.pdf](https://www.jebmh.com/data_pdf/Jadi%20Lingaiah%20-%203%20-%20FINAL.pdf)
- [11] Sharifkashani S, Dabirmoghaddam P, Kheirkhah M, Hosseinzadehnik R. A new clinical scoring system for adenoid hypertrophy in children. *Iran J Otorhinolaryngol.* 2015;27(78):55-61.
- [12] Parikh SR, Coronel M, Lee JJ, Brown SM. Validation of a new grading system for endoscopic examination of adenoid hypertrophy. *Otolaryngol Head Neck Surg.* 2006;135(5):684-87.
- [13] Cannon CR, Replogle WH, Schenk MP. Endoscopic-assisted adenoidectomy. *Otolaryngol Head Neck Surg.* 1999;121(6):740-74.



- [14] Saxby AJ, Chappel CA. Residual adenoid tissue post curettage: Role of nasopharyngoscopy in adenoidectomy. ANZ J Surg. 2009;79(11):809-11.
- [15] Zainea V. Conventional curettage adenoidectomy versus endoscopic assisted adenoidectomy. Maedica (Buchar). 2011;6(4):328-29.
- [16] Pearl AJ, Manoukian JJ. Adenoidectomy: Indirect visualisation of choanal adenoids. J Otolaryngol. 1994;23(3):221-24.
- [17] Kamel RH, Ishak EA. Enlarged adenoids and adenoidectomy in adults: Endoscopic approach and histopathological study. J Laryngol Otol. 1990;104(12):965-67.
- [18] Becker SP, Roberts N, Coglianese D. Endoscopic adenoidectomy or relief of serous otitis media. Laryngoscope. 1992;102(12 Pt 1):1379-84.
- [19] Schaffer SR, Wong GH. Endoscopic visualisation facilitates adenoidectomy. Otolaryngol Head Neck Surg. 2007;136(3):510.
- [20] Yang L, Shan Y, Wang S, Cai C, Zhang H. Endoscopic assisted adenoidectomy versus conventional curettage adenoidectomy: a meta-analysis of randomized controlled trials. Springer Plus. 2016;5:426.
- [21] Huang HM, Chao MC, Chen YL, Hsiao HR. A combined method of conventional and endoscopic adenoidectomy. Laryngoscope. 1998;108(7):1104-06.

**AUTHOR(S):**

1. Dr. Lakshmi Ananth
2. Dr. Pradeep Hosamani

**PARTICULARS OF CONTRIBUTORS:**

1. Associate Professor, Department of ENT, BGS Global Institute of Medical Sciences, Bengaluru, Karnataka, India.
2. Senior Consultant, Department of ENT, Apollo Hospitals, Sheshadripuram, Bengaluru, Karnataka, India.

**NAME, ADDRESS, E-MAIL ID OF THE CORRESPONDING AUTHOR:**

Dr. Pradeep Hosamani,  
G-403, Vaishnavi Rathnam Apts S.M. Road,  
Jalahalli Cross, Bengaluru-560057, Karnataka, India.  
E-mail: pradeephosamani@yahoo.com

**FINANCIAL OR OTHER COMPETING INTERESTS:**

None.

Date of Online Ahead of Print: **Feb 13, 2018**  
Date of Publishing: **Apr 15, 2018**