

Incidence, Anatomy and Clinical Significance of Carotico-clinoid Foramen and Interclinoid Osseous Bridge in Human Skulls in Gujarat Region

BINITA J PUROHIT, PRAVEEN R SINGH

ABSTRACT

Introduction: Carotico-clinoid foramen is an ossified carotico-clinoid ligament or a dural fold between anterior and middle clinoid processes situated in the middle cranial cavity. It is related to cavernous sinus, pituitary gland and sphenoidal air sinus. Interclinoid osseous bridge is the ossification of ligament or dural fold between anterior, middle and posterior clinoid processes.

Aim: To observe incidence, anatomy and clinical significance of carotico-clinoid foramen and interclinoid osseous bridge in the Gujarat region.

Materials and Methods: The present study was conducted in the Department of Anatomy, total 200 dry adult human skulls were examined to observe incidence, size, shape and various types of carotico-clinoid foramen (complete, contact, incomplete). The incidence of interclinoid osseous bridge was observed bilaterally and divided into four types.

Result: The incidence of carotico-clinoid foramen was 10.5% (21 skulls out of 200). The foramen was bilaterally present in six (3%) and unilateral in 15 (7.5%). The incidence of complete and incomplete foramen was 11 (5.5%) and 10 (5%), respectively. The mean of maximum dimensions of carotico-clinoid foramen was 5.432 ± 1.043 mm on right side and 5.623 ± 0.651 mm on left side. The Type II interclinoid osseous bridge was found in four (2%) skulls. Type I bridge suggests carotico-clinoid foramen itself, while Type III and Type IV bridges were not found in the current study.

Conclusion: The study of carotico-clinoid foramen has clinical importance as its presence can cause compression of internal carotid artery which may result into insufficient blood supply to brain. Further, the presence of this foramen and interclinoid osseous bridge can complicate neurosurgery in this region. Therefore, the detailed anatomical knowledge is very important for clinicians to increase success rate in the regional surgery.

Keywords: Internal carotid artery, Lesser wing of sphenoid, Middle cranial cavity

INTRODUCTION

Lesser wing of sphenoid is an important bony structure which has been most often used landmark in neurosurgery. The projecting medial ends are called anterior clinoid processes which are connected to middle clinoid processes by the carotico-clinoid ligament or by a dural fold extending between these two processes. Occasionally, ossification of the ligament or dural fold results in formation of carotico-clinoid foramen [1]. Thus, carotico-clinoid foramen is one of the inconstant foramen situated in the base of the cranial cavity. There are the other ligaments which connect certain parts of sphenoid bone which occasionally ossify. The pterygospinous ligament (between the spine of sphenoid and the upper part of the lateral pterygoid plate) and interclinoid ligament (between

the anterior, middle and posterior clinoid processes) are the examples which sometimes get ossified [2].

Internal carotid artery is the artery of 'anterior circulation' supplying majority of forebrain. The artery is divided into 3 parts-petrous part, cavernous part and intracranial part. After traversing through cavernous sinus it curves up medial to anterior clinoid process. Finally, the artery emerges through dural roof of cavernous sinus [1]. The clinoidal segment of artery is situated in the collar of dural lining of cavernous sinus where it is completely encased by connective tissue. Here, the artery is situated between proximal and distal dural rings. The proximal (lower) ring is formed by medial extension of dura mater from lower surface of anterior clinoid process and distal (upper) ring is formed by medial extension of dura mater from

upper surface of anterior clinoid process [2].

Anterior clinoid process is usually removed in order to approach cavernous sinus and related structures in neurosurgery. The presence of carotico-clinoid foramen and interclinoid osseous bridge create obstacles while approaching anterior clinoid process in the regional neurosurgery and increases the risks, especially if aneurysm of internal carotid artery is present. Further, the high incidence of these structures has been reported in the subjects with hormonal disturbance, idiots, criminals and epileptics [3]. Therefore, detailed anatomical knowledge of the carotico-clinoid foramen and interclinoid osseous bridge are requisite to obtain successful results while operating this region for various clinical conditions.

MATERIALS AND METHODS

This observational study was conducted in the Department of Anatomy at Pramukhswami Medical College and other medical colleges of Gujarat region from May 2013 to August 2016, after obtaining permission from the institutional Human Research Ethics Committee.

The study included 200 intact dry adult human skulls. The skulls having crack or fracture lines in the region of orbit were excluded from the study. The anterior, middle and posterior clinoid processes were examined to note the presence of carotico-clinoid foramen and interclinoid osseous bridge. Three types of connection between anterior and middle clinoid processes were observed and divided according to classification of Keyes [4]:

- i) Complete type-If complete foramen is present without having break.
- ii) Contact type-If suture is there between anterior and middle clinoid processes.
- iii) Incomplete type-If spicules of bone extended between anterior and middle clinoid process without any contact.

Measurement of the foramen was taken along the maximum diameter, which is the transverse diameter. The complete type of foramina was measured along transverse diameter. The incomplete foramina were measured by passing ruler between the tips anterior and middle clinoid process.

The incidence of interclinoid osseous bridge was observed too bilaterally and divided into four types according to classification proposed by Archana R et al., [5].

Type I: Bridge present between anterior and middle clinoid process (carotico-clinoid foramen);

Type II: Bridge between anterior, middle and posterior clinoid process;

Type III: Bridge between anterior and posterior clinoid process;

Type IV: Bridge between middle and posterior clinoid process.

STATISTICAL ANALYSIS

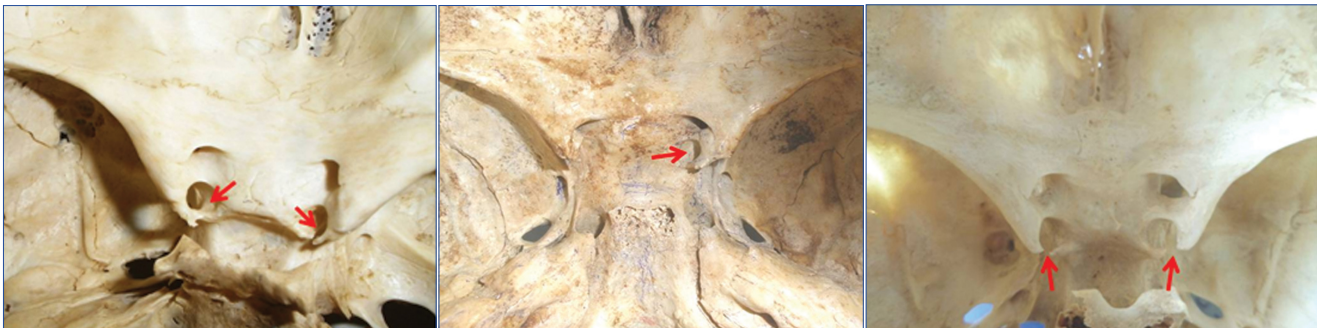
Mean and standard deviation of diameter (maximum dimension) were calculated for the carotico-clinoid foramen using SPSS version 14.0. The incidence of carotico-clinoid foramen and interclinoid osseous bridge were calculated too.

RESULTS

Out of 200 skulls, the carotico-clinoid foramen was present in 21 (10.5%) skulls. The foramen was present in 12 (6%) skulls on right side, 16 (8%) skulls on left side. It was present unilaterally in 15 (7.5%) and the bilateral presence was noted in 6 (3%) skulls. The incidence of complete, contact and incomplete carotico-clinoid foramen is shown in the [Table/Fig-1]. It is noteworthy that the 'contact' type of foramen was not found in the current study. Bilateral presence of the complete foremen [Table/Fig-2] and unilateral presence [Table/Fig-3]. Bilateral incomplete carotico-clinoid foramen [Table/Fig-4]. The mean maximum dimensions

Type	Complete	Contact	Incomplete	Total (n=200)	
Unilateral	Right	4 (2%)	0	2 (1%)	6 (3%)
	Left	5 (2.5%)	0	4 (2%)	9 (4.5%)
Bilateral	2 (1%)	0	4 (2%)	6 (3%)	
Total (n=200)	11 (5.5%)	0	10 (5%)	21 (10.5%)	

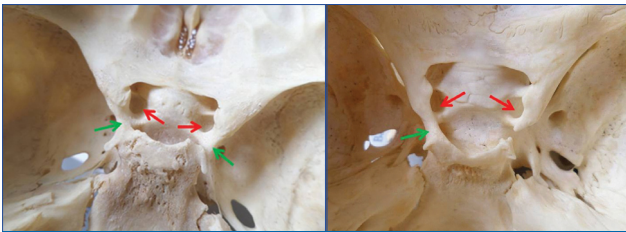
[Table/Fig-1]: Incidence of complete, contact and incomplete types of carotico-clinoid foramen.



[Table/Fig-2]: Shows bilateral presence of carotico-clinoid foramen (red arrows). **[Table/Fig-3]:** Shows unilateral (right side) presence of carotico-clinoid foramen (red arrow). **[Table/Fig-4]:** Shows bilateral presence of incomplete carotico-clinoid foramen.

of this foramen were 5.432 ± 1.043 mm on right side and 5.623 ± 0.651 mm on left side.

Interclinoid osseous bridge was found in four (2%) skulls (unilateral in three skulls and bilateral in one skull). Here, Type II bridge was found connecting anterior, middle and posterior clinoid processes in all these four skulls. Type I bridge suggests presence of carotico-clinoid foramen, which has separate narration in the present study. Type III and Type IV bridges were not found in the skulls observed in the current study. Bilateral presence of interclinoid osseous bridge with bilateral complete carotico-clinoid foramen [Table/Fig-5] and unilateral (left sided) interclinoid osseous bridge with bilateral complete foramen are shown in [Table/Fig-6].



[Table/Fig-5]: Shows bilateral complete carotico-clinoid foramen (red arrows) with bilateral interclinoid osseous bridge (green arrows).
[Table/Fig-6]: Shows presence of bilateral complete carotico-clinoid foramen (red arrows) with unilateral interclinoid osseous bridge (green arrow).

DISCUSSION

Ossification in human body is a normal age dependent physiological process. Hochstetter F et al., and Kier EL stated that an osseous carotico-clinoid foramen and interclinoid osseous bridge are developmental anomalies and showed the existence of the same structures in fetal and infant skulls [6,7]. Thus, ossification of interclinoid ligament is not age dependent and results because of complex embryology of sphenoid bone which has 14 centres of ossification. Ossification of ligamentous structures can be possible reason for compression of neighbouring structures. Sometimes, they produce complications while performing regional surgery [2].

The word 'clinoid' is derived from the Greek word 'cline' which means a bed and the meaning of 'oid' is inclined. The anterior and posterior clinoid processes form four corners of sella turcica. Here sella turcica can be resembled as 'bed' [8]. "Clinoid space" is a small triangular area on the superior surface of cavernous sinus with thin underlying dura mater which becomes evident after removal of anterior clinoid process. The dimensions of the space vary according to size of anterior clinoid process. The space is located lateral to emergence of internal carotid artery from the cavernous sinus. The important fact is that an interclinoid osseous bridge can be possible reason for formation of complete bony ring around clinoid segment which

Study	Population/Region	Number of Skulls	Carotico-clinoid Foramen			Interclinoid Osseous Bridge
			Unilateral	Bilateral	Total	
Erturk M et al., [3]	Turkish population	171	41 (23.98%)	20 (11.69%)	61 (35.67%)	14 (8.18%)
Keyes JEL [4]	Caucasian American population	2187	-	-	27.46%	8.68%
Archana R et al., [5]	Indian population	250	23 (9.2%)	7 (2.8%)	30 (12%)	55 (22%)
Azaredo RA et al., [9]	Portuguese population	270	6 (2.22%)	11 (4.05%)	17 (6.27%)	9 (3.04%)
Inoue T et al., [10]	-	50	11 (22%)	7 (14%)	18 (36%)	2 (4%)
Cireli E et al., [11]	Turkish population	50	3 (6%)	-	3 (6%)	1 (2%)
Deda H et al., [12]	Turkish population	88	6 (6.82%)	7 (7.95%)	13 (14.77%)	4 (4.54%)
Gurun R et al., [13]	Turkish population	198	16 (8.08%)	11 (5.55%)	27 (13.63%)	2 (1.01%)
Lee HY et al., [14]	Korean population	73	15.7%	1.4%	17.1%	-
Desai SB et al., [15]	North inferior Karnataka region	223	53 (23.74%)	30 (13.45%)	83 (37.19%)	-
Shaikh S et al., [16]	Aurangabad district	100	10 (10%)	14 (14%)	24 (24%)	-
Aggarwal B et al., [17]	-	70	-	-	15.72%	-
Freire A et al., [18]	Brazilian population	80	8.5%	2.5%	6.25%	-
Kanjija D et al., [19]	Gujarat region	200	11 (6.5%)	18 (9%)	29 (14.5%)	15 (7.5%)
Kolagi S et al., [20]	Indian population	-	-	-	-	9 (8.04%)
Kapur E et al., [21]	-	200	9.25%	7.5%	16.75%	6.75%
Magadum A et al., [22]	South India region	50	3 (6%)	-	3 (6%)	-
Archana BJ et al., [23]	South India region	50	1 (2%)	1 (2%)	2 (4%)	-
Bansode S et al., [24]	South India region	35	2 (5.75%)	5 (14.2%)	7 (20%)	-
Present Study	Gujarat region	200	15 (7.5%)	6 (3%)	21 (10.5%)	4 (2%)

[Table/Fig-7]: Comparison of incidence of carotico-clinoid foramen and interclinoid osseous bridge with various researchers [3-5,9-24].

affect the course of internal carotid artery [3].

The incidence of carotico-clinoid foramen and interclinoid osseous bridge has been studied by various researchers in different populations [3-5,9-24] [Table/Fig-7].

Out of 50 fresh autopsy bodies studied by Ozdogmus O et al., they found complete ossification of carotico-clinoid ligament in 27 sides and the incomplete one was observed in 55 sides of skull of autopsy case [2]. Bilateral complete ossification of interclinoid ligament was found in three male autopsy cases.

The presence of carotico-clinoid foramen can produce compression, stretching or tightening of internal carotid artery which give rise to headache and other neuronal symptoms due to insufficient blood supply to brain [2,5,20]. The removal of anterior clinoid process is an important step of neurosurgery while approaching cavernous sinus for the management of proximal Internal carotid artery aneurysms. On the infero-medial aspect of anterior clinoid process, clinoid segment of internal carotid artery is situated. On the lateral wall of cavernous sinus, the oculomotor, trochlear, abducent and ophthalmic division of trigeminal nerve travel within a dural fold just below and lateral to anterior clinoid process. Among these four clinoid segment of internal carotid artery and Oculomotor nerve can be damaged during removal of anterior clinoid process [2,5,17,20]. Sometimes, anterior clinoid process can be pneumatized or the bone marrow may be having varying density. Therefore, the anterior clinoid process should be carefully drilled without injuring internal carotid artery and optic nerve. It is prerequisite that anterior clinoid process should be evaluated with computed tomography prior to regional surgery [3,5,17,20].

CONCLUSION

From the above discussion, it can be concluded that the incidence of carotico-clinoid foramen in dry skulls of Gujarat region was 10.5%, while the incidence of interclinoid osseous bridge was 2%. However, the incidence of carotico-clinoid foramen and interclinoid osseous bridge varies in different populations and regions of the world. The presence of carotico-clinoid foramen and interclinoid osseous bridge can interfere with the removal of anterior clinoid process which is the critical step in the regional surgery. Further, the presence of this foramen can be possible reason for compression, tightening or stretching of internal carotid artery which can be responsible for headache and neuronal symptoms. Therefore, detailed anatomical knowledge regarding carotico-clinoid foramen is required for neurosurgeons while approaching the region for surgical procedures.

ACKNOWLEDGEMENTS

I am very grateful to the Professor and Head of Department of Pramukhswami Medical College, Karamsad; Government Medical College, Surat; Government Medical College, Vadodara;

BJ Medical College, Ahmedabad; Sumandeep Medical College, Vadodara; Government Dental College, Ahmedabad and DDIT Dental College, Nadiad for allowing me to avail the facilities of the respective departments. I am also thankful to the staff members of respective departments for helping me in my project.

REFERENCES

- [1] Standring S. Gray's Anatomy, The Anatomical Basis of Clinical Practice. Intracranial region. 40th edition, Churchill Livingstone Elsevier, London 2008. Pp:424-26, 610.
- [2] Ozdoğan O, Saka E, Tulay C, Gürdal E, Uzun I, Cavdar S. The anatomy of the carotico-clinoid foramen and its relation with the internal carotid artery. *Surg Radiol Anat.* 2003;25(3-4):241-46.
- [3] Erturk M, Kayalioglu G, Govsa F. Anatomy of the clinoid region with special emphasis on the carotico-clinoid foramen and interclinoid osseous bridge in a recent Turkish population. *Neurosurg Rev.* 2004;27(1):22-26.
- [4] Keyes JEL. Observations on four thousand optic foramina in human skulls of known origin. *Arch Ophthalmol.* 1935;13:538-68.
- [5] Archana R, Anita R, Chopra J, Manik P, Diwan R. Incidence of osseous interclinoid bars in Indian population. *Surg Radiol Anat.* 2010;32(4):383-87.
- [6] Hochstetter F. About the interclinoid taenia, the commissura alicochlearis and the supracochlear cartilage of the human primordial cranium. *Gegenbaurs Morph Jahrb.* 1940;84:220-43. [Translate from Google].
- [7] Kier EL. Embryology of the normal optic canal and its anomalies. An anatomic and roentgenographic study. *Invest Radiol.* 1966;1:346-62.
- [8] Singla RK, Dehiyan A, Sharma RK, Agnihotri G. Bilateral carotico-clinoid foramen: A case report. *IJMDS.* 2015;4(1):637-40.
- [9] Azeredo RA, Liberti EA, Watanabe IS. Anatomical variations of the clinoid process of the human sphenoid bone. *Arq Cent Estud Curso Odontol Univ Fed Minas Gerais.* 1988;25-26:9-11.
- [10] Inoue T, Rhoton AL, Theele D, Barry ME. Surgical approaches to the cavernous sinus: a microsurgical study. *Neurosurgery.* 1990;26:903-32.
- [11] Cireli E, Ustun EE, Yurtseven M, Pala S. Fossa sella turcica varyasyonlarının değerlendirilmesi I. Morfolojik ve antropolojik kriterlere göre. *Ege Tıp Dergisi.* 1990;29:364-67.
- [12] Deda H, Tekdemir I, Arinci K, Gokalp HZ. Microanatomy of sinus cavernosus, bone structures and variations. *Ankara Tıp Mecmuası.* 1997;139:361-65. [Translate from Google].
- [13] Gurun R, Magden O, Ertem AD. Foramen carotico-clinoideum. *Cerrahpasa Tıp Dergisi.* 1976;25:685-91.
- [14] Lee HY, Chung IH, Choi BY. Anterior clinoid process and optic strut in Koreans. *Yonsei Med J.* 1997;38:151-54.
- [15] Desai SD, Sreepadma S. Study of carotico clinoid foramen in dry adult human skulls of North Inferior Karnataka. *NJBMS.* 2010;1(2):60-64.
- [16] Shaikh S, Ukey R, Kawale D, Diwan C. Study of carotico-clinoid foramen in dry human skull of Aurangabad District. *Int J Basic Med Sci.* 2013;5(3):148-54.
- [17] Aggrawal B, Gupta M, Kumar H. Ossified carotico-clinoid ligament of sphenoid bone. *Bombay Hosp J.* 2011;53(4):743-46.
- [18] Freire A, Rossi A, Prado F, Carlos F, Ferreira P Botacin R. Carotico-clinoid foramen in human skulls. incidence, morphometry and its clinical implications. *Int J Morphol.* 2011;29(2):427-31.
- [19] Kanjiya D, Tandell M, Patel S, Nayak T, Sutaria L, Pensi LA. Incidence of ossified interclinoid bars in dry human skull of Gujarat. *Int J Biomed Adv Res.* 2012;3(12):75-85.
- [20] Kolagi S, Herur A, Patil G, Rairam GB. Complete sella turcica bridges prevalence and dimensions, *J Anat Soc India.* 2011;60(1)22-25.

- [21] Kapur E, Mehic A. Anatomical variations and morphometric study of the optic strut and the anterior clinoid process. *Bosn J Basic Med Sci.* 2012;12(2):88-93.
- [22] Magadam A, Jevoor P, Dixit D, Shirol V. A study of caroticoclinoid foramen in the South Indian skulls: Incidence, morphometry and its clinical correlations. *BIOMIRROR, An Open Access Journal.* 2012;3(5):1-3.
- [23] Archana BJ, Shivaleela C, Kumar GV, Pradeep P, Lakshmi Prabha S. An osteological study of incidence, morphometry and clinical correlations of carotico-clinoid foramen in dried adult human skulls. *RJPBCS.* 2013;4(3):347-52.
- [24] Bansode S, Devadas P, Vinila BH. Study of incidence of the carotico-clinoid foramen in the south Indian dry adult skulls: A cross sectional study. *International Journal of Anatomy and Research.* 2017;5(3.1):4051-55.

AUTHOR(S):

1. Dr. Binita J Purohit
2. Dr. Praveen R Singh

PARTICULARS OF CONTRIBUTORS:

1. Assistant Professor, Department of Anatomy, Pramukhswami Medical College, Karamsad, Anand, Gujarat, India.
2. Professor and Head, Department of Anatomy, Pramukhswami Medical College, Karamsad, Anand, Gujarat, India.

NAME, ADDRESS, E-MAIL ID OF THE CORRESPONDING AUTHOR:

Dr. Binita J Purohit,
Assistant Professor, Department of Anatomy,
Pramukhswami Medical College, Karamsad,
Anand-388325, Gujarat, India.
E-mail: purohitbinita@gmail.com

FINANCIAL OR OTHER COMPETING INTERESTS:

None.

Date of Publishing: **Apr 15, 2018**