

Carotid Body Tumour: A Rare Case Report

SATISH PATIL, PARTH VAISHNAV, VEERESH HANCHINAL, IRANNA HITTALAMANI

ABSTRACT

Carotid Body Tumour (CBT) is a uncommon tumour which arises from a chemoreceptor tissue, which is present at the bifurcation of common carotid arteries. Not many case

reports have been reported for carotid body tumours. We report an unusual case of a large carotid paraganglioma in a 31-year-old female. This neck swelling was present, for several years before admission, but was smaller in size.

Keywords: Bifurcation, Chemoreceptor, Glomus tumour, Paraganglioma

CASE REPORT

A 31-year-old female patient presented with a slowly progressive swelling since 3 years which was painless in nature on left aspect of neck to the Department of Radiology. She did not have any history of fever, palpitations or any other significant symptoms. Patient did not have history of hypertension or diabetes. On general examination, patient was febrile, her BP and pulse rate was within normal limits. On local examination, a firm, non-tender swelling with noted and palpable bruit was noted in the anterior triangle of the left side of neck. The lesion was mobile from sideward but had restricted vertical movement. The overlying skin showed mild increased in temperature as compared to other side.

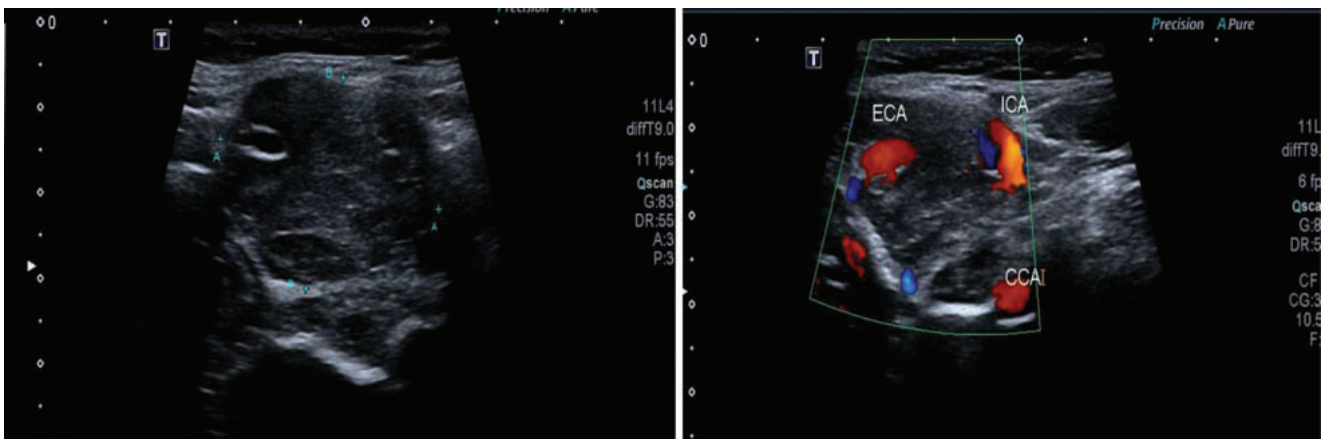
Ultrasound examination showed a well-defined, oval shaped iso to hypo-echoic solid mass lesion measuring approximately

2 x 3.5 x 3 cm sized (AP X TR X SI) at the bifurcation of left common carotid artery causing splaying of internal and external carotid arteries. Few small oval anechoic areas were noted in the lesion. No evidence of calcification was noted within [Table/Fig-1].

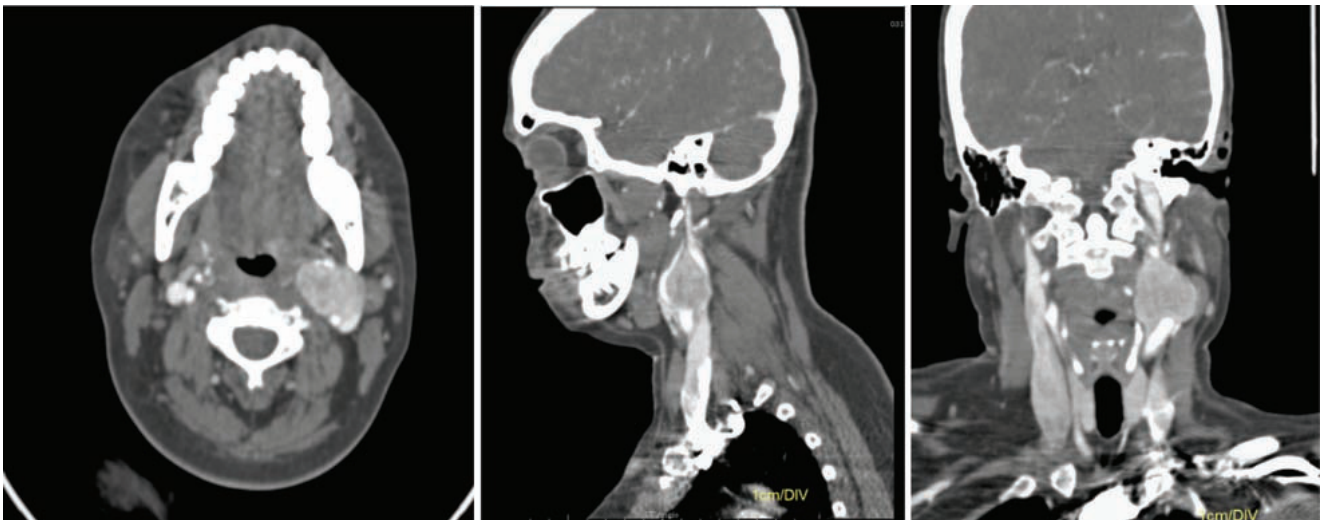
On color Doppler study, the lesion showed prominent vascularity with suspicious feeding arteries arising from the left external carotid artery [Table/Fig-2].

On NECT scans, a well-defined rounded iso to hypodense mass lesion measuring about 2.2 x 3.3 x 3.1 cm sized (AP X TR X SI) was noted in the left carotid space which was showing intense enhancement on contrast administration with few non enhancing areas within - suggested possibility of necrosis.

The lesion was noted to cause splaying of the internal carotid artery and external carotid artery, probably arising at the level of



[Table/Fig-1]: Well-defined oval shaped iso to hypo-echoic solid mass lesion at the bifurcation of left common carotid artery causing splaying of internal and external carotid arteries with few small oval anechoic areas within. **[Table/Fig-2]:** On color Doppler study, the lesion showed prominent vascularity with suspicious feeding arteries arising from the left external carotid artery.



[Table/Fig-3,4,5]: Contrast enhanced CT in axial, sagittal and coronal planes respectively shows, well-defined rounded iso to hypodense mass lesion in the left carotid space which was showing intense enhancement on contrast administration with few non-enhancing necrotic areas causing splaying of the internal carotid artery and external carotid artery, probably arising at the level of carotid bulb.

carotid bulb [Table/Fig-3-5]. Anteriorly the lesion was abutting the left submandibular gland with well-maintained fat plane, posteriorly it was abutting and compressing the left internal jugular vein, superiorly the lesion was extending upto C2 vertebral body level, inferiorly the lesion was extending upto C5 vertebral body level involving the carotid bulb, laterally the lesion was abutting the left sternocleidomastoid muscle and medially extending upto left pyriform sinus.

On 3D volumetric reconstruction of CT-angiography showed vascular mass lesion at the bifurcation of left common carotid artery which was causing splaying of external and internal carotid arteries [Table/Fig-6,7]. Few feeding vessels were also noted from the external carotid artery, typical feature of carotid body tumour.

Major differential diagnoses for this lesion were vagal schwannoma, vagal neurofibroma, lymph nodal mass or carotid body ectasia. Vagal schwannoma and vagal neurofibroma usually tends to displace both vessels rather than causing

their splaying. Lymph nodal mass if hypervascular may also mimic carotid body tumour. Carotid bulb ectasia can be easily differentiated by using contrast enhanced and angiography studies.

The treatment of choice is surgical excision. If the tumour is large or has higher risk of complications, radiotherapy may be considered.

DISCUSSION

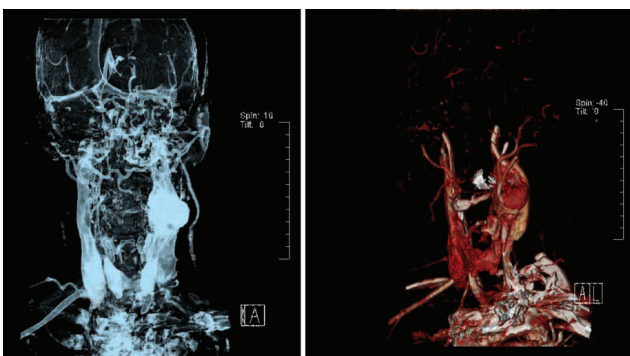
Carotid chemodectomas rare tumours and relatively asymptomatic tumours. They are slow growing and benign tumours. In head and neck regions, carotid body tumours are most common paragangliomas found [1]. Kohn first used the term paraganglion to describe the carotid body [1].

Carotid body tumours only account for 0.5% of all body tumours [2].

CBT originate from glomus bodies also called as paraganglia which is present at carotid bifurcation. These are derived from primitive neural crest consisting of chemoreceptor cells [3,4].

CBTs account for more than 50% of head and neck paragangliomas [5]. About 10% of the cases are bilateral and there is familial incidence of 30% [2]. Only 3% of all extra adrenal paragangliomas occur in the head and neck region while 85% may be in the abdomen [6].

The clinical presentation of CBT is slow growing mass which may be pulsatile in neck region with or without symptoms of vagal or hypoglossal neuropathy [1,7,8]. Glomus cells migrate along the distribution of branchial mesoderm and are found at specific sites along the course of aorta and carotid arteries [9].



[Table/Fig-6,7]: 3D volumetric reconstruction of CT Angiography shows vascular mass lesion at the bifurcation of left common carotid artery causing splaying of external and internal carotid arteries.

In the initial stages CBT is a slow growing mass which may be just palpable in the anterior triangle of the neck. Later, the tumour tends to grow around external and internal carotid arteries without significant compression. Functional i.e., catecholamine secreting carotid body paragangliomas are rare and can produce paroxysmal hypertension mimicking pheochromocytoma [10].

On ultrasonography demonstration of a solid and well-defined hypoechoic to iso echogenic vascular mass lesion which is located at the carotid bifurcation splaying the internal and external carotid arteries is characteristic finding for the diagnosis. High resolution sonography depicts accurately the location and shape of the tumour and its relation to the neck vessels. CDFI demonstrates intratumoural feeding vessels which show low resistance arterial flow pattern on pulse wave Doppler [10].

On CT strong homogeneously enhancing solid mass lesion adjoining the carotid vessels is seen. A typical sign of carotid body tumours is large feeding vessels. The tumour is best demonstrated on dynamic CT and spiral CT angiography [11].

CONCLUSION

We hereby present a rare case report of CBT in a middle aged woman presenting as slow growing asymptomatic pulsatile mass in neck and demonstrating all typical features of paraganglioma on ultrasound and CT-scan. Surgical excision was advised to our case to avoid involvement of glossopharyngeal, hypoglossal, vagal or recurrent laryngeal

nerve and prevent the invasion of carotid vessels to avoid the risk of stenosis, occlusion or rupture.

REFERENCES

- [1] Goffredo C, Antignani PL, Gervasi F, Ricottini E. Update in carotid chemodectoma. Renaissance Medical Publishing. 2009;2(2).
- [2] Naik SM, Shenoy AM, Nanjundappa, Halkud R, Chavan P, Sidappa K, et al. Paragangliomas of the carotid body: current management protocols and review of literature. Indian J Surg Oncol. 2013;4(3):305-12.
- [3] Shamblin WR, ReMine WH, Sheps SG, Harrison EG Jr. Carotid body tumor (chemodectoma). Clinicopathologic analysis of ninety cases. Am J Surg. 1971;122:732-39.
- [4] Dimakakos PB, Kotsis TE. Carotid body paraganglioma: Review and surgical management. Eur J Plast Surg. 2001;24:58-65.
- [5] Rao AB, Koeller KK, Adair CF. From the archives of the AFIP. Paragangliomas of the head and neck: radiologic-pathologic correlation Armed Forces Institute of Pathology. Radiographics. 1999;19:1605-32.
- [6] Patel SR, Winchester DJ, Benjamin RS. A 15-year experience with chemotherapy of patients with paraganglioma. Cancer. 1995;76:1476-80.
- [7] Patetsios P, Gable DR, Garrett WV, Lamont JP, Kuhn JA, Shutze WP, et al. Management of carotid body paragangliomas and review of a 30-year experience. Ann Vasc Surg. 2002;16(3):331-38.
- [8] Van der Mey AG, Jansen JC, van Baalen JM. Management of carotid body tumors. Otolaryngol Clin North Am. 2001;34(5):907-24.
- [9] Nguyen RP, Shah LM, Quigley EP, Harnsberger HR, Wiggins RH. Carotid body detection on CT angiography. Am J Neuroradiol. 2011;32(6):1096-99.
- [10] Dhiman DS, Sharma YP, Sarin NK. US and CT in carotid body tumor. Indian J Radiol Imaging. 2000;10:39-40.

AUTHOR(S):

1. Dr. Satish Patil
2. Dr. Parth Vaishnav
3. Dr. Veeresh Hanchinal
4. Dr. Iranna Hittalamani

PARTICULARS OF CONTRIBUTORS:

1. Assistant Professor, Department of Radiology, Shri B.M. Patil Medical College, Bijapur, Karnataka, India.
2. Junior Resident, Department of Radiology, Shri B.M. Patil Medical College, Bijapur, Karnataka, India.
3. Assistant Professor, Department of Radiology, Shri B.M. Patil Medical College, Bijapur, Karnataka, India.

4. Junior Resident, Department of Radiology, Shri B.M. Patil Medical College, Bijapur, Karnataka, India.

NAME, ADDRESS, E-MAIL ID OF THE CORRESPONDING AUTHOR:

Dr. Parth Vaishnav,
Junior Resident, Department of Radiology, Shri B.M. Patil Medical College, BLDE University, Solapur Road, Bijapur-586103, Karnataka, India.
E-mail: vaishnavparth007@gmail.com

FINANCIAL OR OTHER COMPETING INTERESTS:

None.

Date of Publishing: Jul 01, 2017