

CT Evaluation of Large Bowel Wall Lesions

DEVIDAS B DAHIPHALE, PUSHAN KUMAR SHARMA, ABHANG APTE, ASMITA SURYAWANSHI, RAJ DEORE, SAURABH CHOUDHARI

ABSTRACT

Introduction: Clinical diagnosis and management of large bowel disease is made difficult by the non-specific nature of symptoms and a significant overlap in the presentation of different pathologic processes affecting it. Computed Tomography (CT) is being increasingly used for the diagnostic evaluation of large bowel lesions.

Aim: Present study describes the role of Multidetector CT in evaluation of suspected large bowel lesions in patients referred to the Radiology Department.

Materials and Methods: In this observational study, data was collected from patients of suspected large bowel lesions referred to MGM Hospital and Research Institute, Aurangabad. Total 30 patients were enrolled during November 2014 to November 2016. Patients presenting with the symptoms related to altered bowel habits/abdomen, positive large bowel wall findings on plain CT, large bowel lesions detected on ultrasound, history of trauma undergoing CT-scan with large bowel wall thickening on USG/CT were included. All patients were followed up to therapeutic/biopsy/operative diagnosis. Histopathological reports helped in the retrospective confirmation of the provisional diagnosis on Multidetector CT.

Results: Overall most of the cases (benign + malignant) were reported in the age group of 41-60 years (53.3%). Bleeding per rectum and weight loss was the most common presentation (23.5%) amongst malignant lesions. Loose stool and vomiting (30.8%) was the most common presentation amongst all the benign lesions. The most common location for malignant lesions was rectum (52.9%) and for benign lesions was the long segment extending from transverse to sigmoid colon (23.1%). Malignant lesions showed heterogeneous mixed attenuation (100%), marked thickening (88.2%) and asymmetric thickening (88.2%). Benign lesions showed homogenous attenuation (92.3%), mild thickening (84.6%) and symmetrical thickening (92.3%). Focal thickening was seen in most of the malignant lesions (76.5%) and none presented with diffuse thickening. Both focal and diffuse thickening were seen in benign lesions (38.5%) followed by segmental involvement (23.1%). All of the benign lesions were associated with peripheral fat stranding. Amongst the malignant lesions, 70.6% showed presence of surrounding fat stranding.

Conclusion: From the study results, it can be stated that MDCT has a high predictive value in the diagnosis and differentiation of benign and malignant lesions of the large bowel.

Keywords: Attenuation, Fat stranding, Focal and diffuse thickening

INTRODUCTION

The differential diagnosis for thickening of the large bowel wall includes conditions like neoplasia, inflammation, infection or ischaemia [1]. In the earlier period, standard barium studies of the gastrointestinal tract were done for the detection of bowel wall thickening. However, the advent of CT has made it possible to demonstrate the true extra-luminal extent of pathology and it has been highly valued in the evaluation of bowel wall thickening [2]. Macari and Balthazar [3] have suggested that careful analysis of CT parameters like degree of involvement,

extent and symmetry of thickening; pattern of attenuation and enhancement; and associated findings avoid most pitfalls as well as provide a diagnosis of primary intestinal lesions, or offer a pertinent differential diagnosis. It has been also reported that study and differentiation of CT patterns, along with the analysis of geographic and morphologic features of bowel wall, can help in narrowing down the diagnostic possibilities, especially in the differentiation of benign neoplasm from malignant neoplasm [4].

MATERIALS AND METHODS

In this observational study, data was collected from patients of suspected large bowel lesions who were referred to MGM Hospital and Research Institute, Aurangabad, Maharashtra, India. A total of 30 patients were included in the study. Study was done for a period of two years from November 2014 to November 2016. Approval of the study protocol was taken from the Institutional Ethics Committee of the Institute prior to commencement of the study. Informed consent was taken from each participant prior to enrolment in the study.

Inclusion criteria: (a) Patients presenting with symptoms related to altered bowel habits/abdomen, (b) Patients with positive large bowel wall findings on plain CT, (c) Patients with large bowel lesions detected on ultrasound and (d) Patients with history of trauma undergoing CT scan with large bowel wall thickening on USG/CT were also included in the study.

Exclusion criteria: Patients with deranged renal function, pregnant females and those not willing to give consent were excluded from the study.

Follow-up: All the patients were followed-up to therapeutic/ biopsy/ operative diagnosis. Histopathological reports helped in the retrospective confirmation of the provisional diagnosis on MDCT.

CT protocol for bowel imaging: A 16 slice TOSHIBA AQUILLION CT scanner was used for this study. Each patient was given orally administered colon-cleaning preparation 12 hours prior to CT examination and ingested 1-1.5 L of water/ oral contrast shortly before scanning with or without rectal contrast (SOS). Degree of distension of bowel was assessed by standard CT scout imaging. The criterion for acceptability of image was visualisation of all colonic segments in a well distended state.

Contrast-enhanced MDCT scans were obtained from the diaphragmatic dome to the anal verge with the patient in the supine position after intravenous injection of 80-100 ml non ionic iodinated contrast agent (iopromide 350, omnipaque 350, iopamidol 35-370 or vizipaq 320) was administered at 3 mL/sec. Arterial phase CT acquisitions (start delay: 25-35 seconds) and portal venous phase CT acquisitions (start delay: 50- 70 seconds) were done with a 5 mm section width. Reconstruction of the images with 1 mm sections was done. All CT data were transferred to an Apple Osirix workstation for evaluation. Reconstruction was not only done in coronal and

sagittal planes but also in the axial plane. The technique of reconstruction implemented on all workstations for immediate availability of the needed views. With modern MDCT technique, the "in-plane" and "through-plane" resolution is the same, leading to isotropic voxel resolution in the volume, which makes reconstruction in all planes possible without loss of information.

STATISTICAL ANALYSIS

Data was entered into Microsoft excel datasheet and was analyzed using SPSS 22 version software. Categorical data was represented in the form of frequencies and proportions. Chi-square was used as test of significance.

RESULTS

Most of the malignant cases were found in age group 51-60 years (35.3%) and 41-50 years (29.4%), none of the cases were reported in early age group of 10-20 years. Most of the benign cases were reported in age group of 21-30 years (30.8%). There were equal proportion of benign cases i.e. 23.1% each from age groups of 10 - 20 years and 41 - 50 years. Overall most of the cases (benign + malignant) were reported in age group of 41-60 years (53.3%). Among the 17 malignant cases, 10 were males and 7 were females whereas, among the 13 benign cases 8 were males and 5 were females.

Bleeding per rectum and weight loss was the most common presentation (23.5%) amongst malignant lesions. Loose stool and vomiting (30.8%) was the most common presentation amongst all the benign lesions [Table/Fig-1].

	Pain	PR Bleed	Constipation	Weight loss	Vomiting	Loose stools
Malignancy (n=17)	17.6%	23.5%	17.6%	23.5%	17.6%	--
Benign (Inflammatory/ Infective) (n=13)	23.1%	7.7%	--	7.7%	30.8%	30.8%

[Table/Fig-1]: Clinical features in patients with large bowel lesions.

Amongst all the malignant lesions the most common location was of rectum (52.9%) followed by combined location of sigmoid colon and rectum (29.4%). Amongst all the benign lesions most common involved location was that of long segment extending from transverse to sigmoid colon (23.1%) [Table/Fig-2].

	Ascending Colon	Descending Colon	Rectum	A*	B*	C*	D*	E*	F*
Malignancy (n=17)	11.8%	5.9%	52.9%	0	0	29.4%	0	0	0
Benign (n=13)	0	0	15.4%	15.4%	23.1%	0	15.4%	15.4%	15.4%
Total (n=30)	6.7%	3.3%	36.7%	6.7%	10.0%	16.7%	6.7%	6.7%	6.7%

[Table/Fig-2]: Location of the large bowel lesion.

*Caecum - 1, ascending colon - 2, transverse colon - 3, descending colon - 4, sigmoid colon - 5, rectum - 6, anal canal - 7.
A = 1, 2, 3. B = 3, 4, 5. C = 5, 6. D = 2, 3. E = 3, 4. F = 1, 2.

Histopathology Finding		Homogenous Attenuation	Heterogeneous Stratified Attenuation	Heterogeneous Mixed Attenuation	Total
Malignancy	Count	0	0	17	17
	Percentage	0.0%	0.0%	100.0%	100.0%
Benign	Count	12	1	0	13
	Percentage	92.3%	7.7%	0.0%	100.0%
Total	Count	12	1	17	30
	Percentage	40.0%	3.3%	56.7%	100.0%

[Table/Fig-3]: Attenuation on MDCT of the large bowel lesions.

The p-value < 0.05 was significant for difference in malignant and benign lesions with respect to attenuation. All of the malignant lesions showed heterogeneous mixed attenuation. Most of the benign lesions showed homogenous attenuation (92.3%) [Table/Fig-3].

The p-value < 0.05 was significant for difference in malignant and benign lesions with respect to mild or marked thickening. Marked thickening was seen in most of malignant lesions (88.2%). Mild thickening was seen in most of benign lesions (84.6%) [Table/Fig-4].

		Mild Thickening	Marked Thickening	Total
Malignancy	Count	2	15	17
	Percentage	11.8%	88.2%	100.0%
Benign	Count	11	2	13
	Percentage	84.6%	15.4%	100.0%
Total	Count	13	17	30
	Percentage	43.3%	56.7%	100.0%

[Table/Fig-4]: Degree of bowel wall thickening on MDCT in large bowel lesions.

The p-value < 0.05 was significant for difference in malignant and benign lesions with respect to symmetry of thickening. Most of the malignant lesions were associated with asymmetric thickening (88.2%). Amongst benign lesion most common CT finding was that of symmetrical thickening (92.3%) [Table/Fig-5].

The p-value < 0.05 was significant for difference in malignant and benign lesions with respect to extent of thickening. Focal

		Symmetric	Asymmetric	Total
Malignancy	Count	2	15	17
	Percentage	11.8%	88.2%	100.0%
Benign	Count	12	1	13
	Percentage	92.3%	7.7%	100.0%
Total	Count	14	16	30
	Percentage	46.7%	53.3%	100.0%

[Table/Fig-5]: Symmetric of the large bowel thickening on MDCT.

thickening was seen in most of the malignant lesions (76.5%) and none presented with diffuse thickening. Both focal and diffuse thickening were seen in benign lesions (38.5%) followed by segmental involvement (23.1%) [Table/Fig-6].

Enlarged lymph nodes were seen in both benign (76.9%) and malignant (70.6%) lesions, which was not significant (p-value = 0.697) [Table/Fig-7].

		Focal Thickening	Segmental Thickening	Diffuse Thickening	Total
Malignancy	Count	13	4	0	17
	Percentage	76.5%	23.5%	0.0%	100.0%
Benign	Count	5	3	5	13
	Percentage	38.5%	23.1%	38.5%	100.0%
Total	Count	18	7	5	30
	Percentage	60.0%	23.3%	16.7%	100.0%

[Table/Fig-6]: Extent of thickening of the large bowel on MDCT.

		Present	Absent	Total
Malignancy	Count	12	5	17
	Percentage	70.6%	29.4%	100.0%
Benign	Count	10	3	13
	Percentage	76.9%	23.1%	100.0%
Total	Count	22	8	30
	Percentage	73.3%	26.7%	100.0%

[Table/Fig-7]: Lymph node involvement in large bowel wall lesions.

The p-value < 0.05 was significant for difference in malignant and benign lesions with respect to fat stranding. All of the benign lesions were associated with peripheral fat stranding. Amongst the entire malignant lesions, 70.6% showed presence of surrounding fat stranding which was not seen in 29.4% of the lesions [Table/Fig-8].

Amongst malignant lesions the most common infiltration of adjacent viscera was that of cervix (11.8%) followed by bladder (5.9%). No invasion was noticed in 82.4% cases.

		Present	Absent	Total
Malignancy	Count	12	5	17
	Percentage	70.6%	29.4%	100.0%
Benign	Count	13	0	13
	Percentage	100.0%	0.0%	100.0%
Total	Count	25	5	30
	Percentage	83.3%	16.7%	100.0%

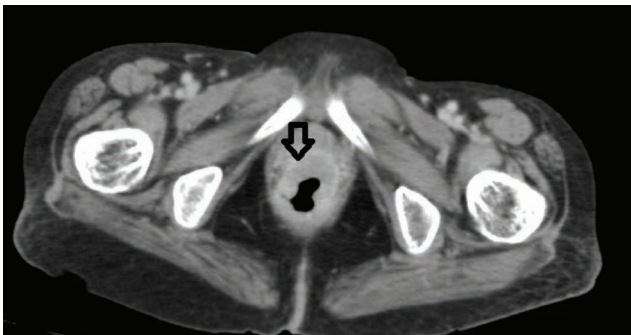
[Table/Fig-8]: Fat stranding observed in large bowel lesions.

Most common site of metastasis in malignant lesions was that of liver (17.6%) followed by lung (11.8%) and bone (5.9%). There were no metastases seen in 64.7% cases.

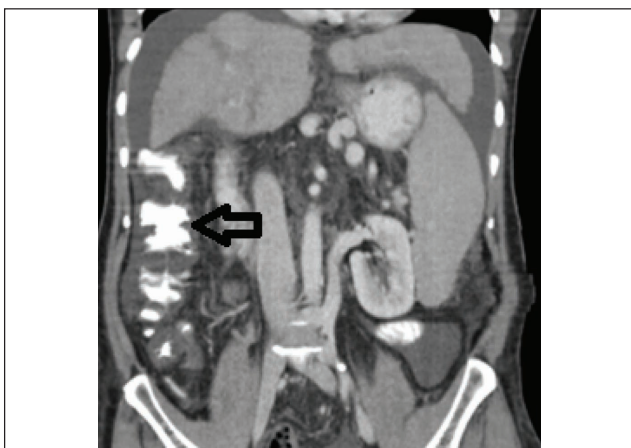Obstruction was present in 17.6% of the malignant and 15.4% of benign lesions, it was absent in most of both the benign and malignant cases.

[Table/Fig-9,10] are among the images of large bowel wall lesions on MDCT from our study.

On overall analysis for diagnosis of large bowel pathologies, MDCT had a sensitivity of 100%, specificity of 92.0%, and positive predictive value of 94.4% and a negative predictive value of 100%.



[Table/Fig-9]: CECT axial Image showing malignant mass in rectum confirmed on histopathology.



[Table/Fig-10]: CECT coronal image showing oedematous bowel wall thickening of ascending colon up to hepatic flexure.

DISCUSSION

As per the observations of our study, amongst all the malignant lesions the most common location was of rectum (52.9%) followed by combined location of sigmoid colon and rectum (29.4%). Bhatt CJ et al., study [5] done recently in Gujarat state of India also reported that the most common malignant lesion involving large bowel was adenocarcinoma and recto-sigmoid region was the most frequent site of involvement noted in 64% patients.

In our study of MDCT in large bowel lesions, out of the total 13 benign cases, 12 cases (92.3%) had homogenous attenuation and 1 case (7.7%) had heterogeneous stratified attenuation. Of the 17 malignant cases, all (100%) had heterogeneous mixed attenuation on CT. This is in agreement with studies done by Balthazar EJ et al., [6] and Roccasalva et al., [7] who have told that homogenous attenuation is a feature of benign disease (inflammatory/infective) and heterogeneous attenuation is a feature of malignancy. In our study, most of the malignant lesions were associated with asymmetric thickening (88.2%), while amongst benign lesions, most common CT finding was that of symmetrical thickening (92.3%). Karpagam B et al., reviewed imaging spectrum of large intestinal lesions and concluded that in their series, lesions of focal asymmetric wall thickening were malignant [8]. Desai RK et al., studied CT evaluation of bowel wall thickening and suggested that signs which can be useful for differentiation of malignant from benign lesions of gastrointestinal tract wall thickening were symmetry of thickening with symmetric thickening common in benign and asymmetric thickening or focal wall thickening common in malignant lesions [2]. Wittenberg J et al., have also reported similar observations in relation to CT findings in benign and malignant disease [4]. Horton KM et al., have reported that primary adenocarcinoma on CT evaluation presents as a soft tissue mass which is discrete or may present as thickening of colonic wall which is focal and asymmetric [9].

Bhatt CJ et al., studied 100 cases of large bowel lesions with MDCT and concluded that MDCT proved to be "the imaging modality of choice" for bowel lesion [5]. With the ever increasing use of MDCT in the initial diagnostic workup of gastrointestinal symptoms, colon cancer is being identified first by the radiologists. Moreover, MDCT is not only being used for primary identification of pathology but also for the preoperative evaluation of staging and the identification of recurrence of tumour [9,10].

LIMITATION

This was an observational and hospital based study design. Also the sample size was small and maybe non representative.

CONCLUSION

From the study results, it can be stated that MDCT has a high predictive value in the diagnosis and differentiation of benign and malignant lesions of the large bowel. Nature of bowel wall thickening (focal, segmental, diffuse), degree and symmetry of bowel wall thickening, pattern of the attenuation and fat stranding are among the important parameters which help in diagnosis and differentiation of benign and malignant lesions of the large bowel.

REFERENCES

- [1] Fernandes T, Oliveira MI, Castro R, Araújo B, Viamonte B, Cunha R. Bowel wall thickening at CT: simplifying the diagnosis. *Insights into Imaging*. 2014;5(2):195-208.
- [2] Desai RK, Tagliabue JR, Wegryn SA, Einstein DM. CT evaluation of wall thickening in the alimentary tract. *Radiographics*. 1991;11:771-83.
- [3] Macari M, Balthazar EJ. CT of bowel wall thickening: significance and pitfalls of interpretation. *AJR Am J Roentgenol*. 2001; 176:1105-16.
- [4] Wittenberg J, Mukesh G, Harisinghani, Jhaveri K, Varghese J, Mueller PR. Algorithmic approach to CT diagnosis of the abnormal bowel wall. *RadioGraphics*. 2002;22(5):1093-07.
- [5] Bhatt CJ, Patel LN, Baraiya M, Patel KK, Vaishnav KU, Shah DS. Multidetector computed tomography in large bowel lesions—a study of 100 cases. *The Indian Journal of Surgery*. 2011;73(5):352-58.
- [6] Balthazar EJ. CT of the gastrointestinal tract: principles and interpretation. *AJR Am J Roentgenol*. 1991;156(1):23-32.
- [7] Roccasalva F, Piccoli M, Palmucci S, Mauro LA, Cappello G, Ettorre GC. The wall enhancement of bowel diseases observed on MDCT and MRI: a pictorial essay. Poster presented at: European Congress of Radiology. 2013 March 7-11, Vienna, Austria.
- [8] Karpagam B, Indira D, Kumar PM, Karthikeyan D. Imaging spectrum of large intestinal lesions: a pictorial essay. *Sch J App Med Sci*. 2015;3(3C):1238-51.
- [9] Horton KM, Abrams RA, Fishman EK. Spiral CT of colon cancer: imaging features and role in management. *Radiographics*. 2000; 20(2):419-30.
- [10] Boyd SK, Cameron-Morrison JD, Hobson JJ, Saenz R. CT imaging of large bowel wall thickening. *J Am Osteopath Coll Radiol*. 2016;5(2):14-22.

AUTHOR(S):

1. Dr. Devidas B Dahiphale
2. Dr. Pushan Kumar Sharma
3. Dr. Abhang Apte
4. Dr. Asmita Suryawanshi
5. Dr. Raj Deore
6. Dr. Saurabh Choudhari

PARTICULARS OF CONTRIBUTORS:

1. Associate Professor, Department of Radiology, MGM Medical College, Aurangabad, Maharashtra, India.
2. Junior Resident, Department of Radiology, MGM Medical College, Aurangabad, Maharashtra, India.
3. Associate Professor, Department of Radiology, MGM Medical College, Aurangabad, Maharashtra, India.
4. Assistant Professor, Department of Radiology, MGM Medical College, Aurangabad, Maharashtra, India.

5. Junior Resident, Department of Radiology, MGM Medical College, Aurangabad, Maharashtra, India.
6. Junior Resident, Department of Radiology, MGM Medical College, Aurangabad, Maharashtra, India.

NAME, ADDRESS, E-MAIL ID OF THE CORRESPONDING AUTHOR:

Dr. Pushan Sharma,
Junior Resident, Department of Radiology,
MGM Medical College, CIDCO,
Aurangabad-431003, Maharashtra, India.
E-mail: pushansharma@gmail.com

FINANCIAL OR OTHER COMPETING INTERESTS:

None.

Date of Publishing: Jul 01, 2017