

Cadavaric Study of Variations in Divisions of Sciatic Nerve

ZARNA PATEL, SUDARSHAN GUPTA, HIREN CHAVDA, NISHITA JETHAVA

ABSTRACT

Introduction: Sciatica is the pain caused by a compression or irritation of the Sciatic Nerve (SN) and the symptoms include nerve pain, numbness, tingling, and weakness. The clinical values are unilateral or bilateral higher break of SN that result in compression of nerve that leads to piriformis syndrome. This pressure on nerve results in paralysis of the supplied muscles and sensory disturbances.

Aim: To observe the variations in the site of divisions of SN and relation to the piriformis muscle.

Materials and Methods: This cross-sectional study was carried out after taking ethical approval from Institutional Ethical Committee (IEC) of present institute during year 2015 with duration of one and half year at Anatomy Department of GMERS Medical College, Gandhinagar

in about 30 properly embalmed cadavers (total 60 lower limb/extremities) during routine dissection.

Results: Total of 60 gluteal regions were examined for the variation in the course and division of the SN. Among them in 51 lower limbs (85%) the SN had a normal course after its exit below the piriformis and divided into tibial nerve and common peroneal nerve at the superior angle of popliteal fossa, while in nine lower limbs (15%) there were higher division site of SN observed.

Conclusion: During posterior hip operations, this high division develops in sciatica, nerve injury during deep intramuscular injections, piriformis syndrome, failed sciatic nerve block in anesthesia and injury. Lower limb surgeries and in the interpretation of sciatic neuropathy can be complicated by variation in division of SN.

Keywords: Common Peroneal nerve, Piriformis muscle, Tibial nerve

INTRODUCTION

Sciatica nerve (SN) word derived from Greek word "Ischiadicus", a widest and longest nerve of the body arising from sacral plexus [1,2]. The SN is formed in the pelvis by connecting anterior divisions of L4-S3 spinal nerve roots. It is around 2 cm wide and near the sacral plexus. Normally, it comes out from the greater sciatic foramen, passing through pelvis and enters into gluteal region by passing under piriformis as a single nerve surrounded by a single epi-neural sheath. SN split at superior angle of popliteal fossa in Tibial Nerve (TN) and Common Peroneal Nerve (CPN). It supplies hamstrings muscles, sensory supply to hip and knee joints and its branches are motor and sensory to leg and foot. Association of SN with piriformis muscle is the central interest of variation. Sometimes, SN breaks into its terminal branches where it is still in the pelvis that leave pelvis in lots of route. The nerve classified in various types accordingly to variation in the natural path in lower limb and its relations to piriformis muscle [2-8].

Sciatica is the pain caused by a compression or irritation of the

SN and symptoms include nerve pain, numbness, tingling, and weakness. The clinical values are unilateral or bilateral higher break of SN that result in compression of nerve that leads to piriformis syndrome, this pressure on nerve result in paralysis of the supplied muscles and sensory disturbances. In this condition person cannot flex the knee joint and also external version and plantar flexion of the extremity are affected [9]. So, this study was carried with objective to observe the variations in the site of divisions of SN and relation to the piriformis muscle.

MATERIALS AND METHODS

This cross-sectional study was carried out after taking ethical approval from Institutional Ethical Committee (IEC) of present institute during year 2015 for the duration of one and half year in the Anatomy Department of GMERS Medical College, Gandhinagar, Gujarat, India in about 30 properly embalmed cadavers (total 60 lower limb/extremities) during routine dissection. We included cadavers without any deformity of lower limb. During routine dissection, gluteal regions and

posterior aspect of thigh on both lower limbs has been dissected to expose the SN. Study was examined following variations in divisions of SN and its relations to piriformis muscle have been observed.

A. Divisions occur in the gluteal region.

- (i) Above Piriformis
- (ii) Beneath Piriformis
- (iii) Below Piriformis

B. Divisions occur in thigh (distance from ischial tuberosity had been measured)

Popliteal fossa, gluteal region and back side of thigh were uncovered by dissection. The gluteus maximus muscle was dissected from its origin and exposed facing its insertion. The biceps femoris muscle was uncovered and the nerve was then revealed in popliteal fossa. Information regarding exit of nerve and its relation to piriformis muscle was recorded. If division in the thigh and above the superior angle of popliteal fossa, than the distance between ischial tuberosity and point of division of SN had been measured. The level of SN division was defined by geographically with regard to the area where the break up took place. The whole path of the nerve was defined and observed for any available variations.

STATISTICAL ANALYSIS

Data was collected and entered in Microsoft Excel sheet and analysed by excel software. Categorical variables proportion and percentage will be obtained.

RESULTS

In the present study of 30 cadavers, total of 60 gluteal regions were examined for the variation in the course and division


of the SN. Among them 51 specimens (85%) the SN had a normal course after its exit below the piriformis and divided into TN and CPN at the superior angle of popliteal fossa, while in nine specimens (15%) there was different division site of SN observed.

In one of specimen, division of SN observed at just below the lower border of gluteus maximus muscle (14.5 cm below from the ischial tuberosity) on the right side and in the same cadaver the division of SN observed at the level of middle of thigh (24 cm below from the Ischial Tuberosity) on the left side [Table/Fig-1a,b].

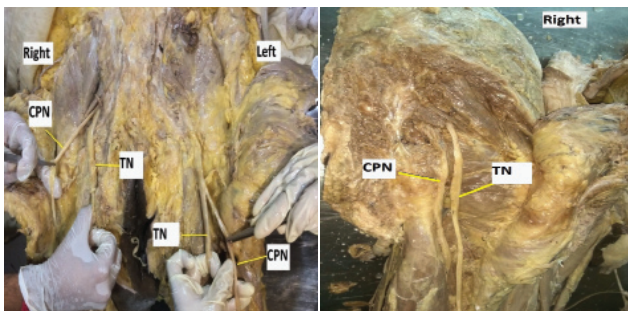
In another cadaver, division of SN observed below the lower border of gluteus maximus muscle 13.5 cm below from the ischial tuberosity on right side and 12 cm on left side [Table/Fig-2]. In another cadaver, division of SN observed in gluteal region at just below the piriformis muscle on both sides [Table/Fig-3]. In one of the cadaver, division of SN observed in gluteal region between the greater trochanter and ischial tuberosity on right side and on left side just below the piriformis [Table/Fig-4a,b]. In one of the lower extremity, division of SN occurred just deep to the piriformis muscle in which CPN passing through piriformis and TN nerve comes from below piriformis [Table/Fig-5].

DISCUSSION

The biggest branch of lumbo-sacral plexus is SN [4]. The division level is important in the respect of clinical as well as treatment purpose. In anatomical textbooks and journals, the arrangement of division of sciatic nerve on male and female were not significant, so not observed. The SN composed when sacral plexus's huge dorsal and ventral component shift descending together [10]. During posterior hip operations,



[Table/Fig-1a,b]: (a) Right Side: Division of SN at just below the lower border of gluteus maximus (14.5 cm below from the ischial tuberosity); (b) Left Side: Division of SN At the level of middle of thigh (24 cm below from the ischial tuberosity). **[Table/Fig-2]:** Division of SN just below the lower border of gluteus maximus (13.5 cm below from the ischial tuberosity) on both the side. **[Table/Fig-3]:** Division of SN just below the piriformis on both the side. (Images from left to right).



[Table/Fig-4a,b]: (a) Right side: Division of SN between the greater trochanter and ischial tuberosity; (b) Left side: Division of SN just below the piriformis. **[Table/Fig-5]:** Right side: CPN passing through piriformis and TN nerve comes from below piriformis.

this high division develops in sciatica, nerve injury during deep intramuscular injections, piriformis syndrome, failed sciatic nerve block in anesthesia and injury [11]. Different clinical picture may be seen in the compression of the undivided SN, CPN and the compression of the TN [5].

Present study observed normal course of SN in 85% and high division of SN in 15% lower limbs. Other similar studies found high division of sciatic nerve in 8.0% [1], 48.0% [5], 8.2% [9], 20.9% [12], 26.67% [13], 8.0% [14], 8.0% [15], 34.0% [16], 16.0% [17], 22.0% [18] and 27.5% [19] of cases.

Beaton & Anson classified variations of the piriformis and SN in 120 specimens in 1937, and in 240 specimens in 1938. Their classification, known as the Beaton and Anson classification, is as follows [20,21]:

Type 1: Undivided nerve below undivided muscle.

Type 2: Divisions of nerve between and below undivided muscle.

Type 3: Divisions above and below undivided muscle.

Type 4: Undivided nerve between heads.

Type 5: Divisions between and above heads.

Type 6: Undivided nerve above undivided muscle.

And for the above types different authors got results as mentioned below [Table/Fig-6].

Present study found type 1 type of variation in 98.3% cases and type 2 variations in 1.7% cases. Another type of variation was also found in present and others study is given in [Table/Fig-7].

Embryological Note [22]

After exits from the spinal cord each spinal nerve divides into dorsal and ventral rami. Musculatures of limbs are supplied by ventral rami of spinal nerves. Lower limbs are supplied by the ventral rami of L4 to S3. Muscles that developed by the dorsal muscle mass are supplied by the dorsal branches of whereas, muscles developed by the ventral mass supplied by the ventral branches of the ventral rami.

The ventral axons growing along the permissive pathways and

Name of Researcher	Type 1	Type 2	Type 3	Type 4	Type 5	Type 6
Patel S et al., [9] 86 Extremities	91.8					
Pokomy D et al., [12] 91 Cadavers	79.1	14.3	4.4	2.2		
Chiba S [16] 14 Extremities		34.0				
Pecina M [18] 130 Cadavers		6.15				
Ugrenovic S et al., [19] 100 Foetuses	96.0	2.5	1.5			Single Case
Beaton & Anson [20] 120 Cadavers	84.2	11.7	3.3	0.8		
Beaton LE et al., [21] 240 Cadavers	90.0	7.1	2.1	0.8		
Present Study 60 Extrimities	98.3					

[Table/Fig-6]: Relationship of the sciatic nerve with piriformis and variations in the high division of the sciatic nerve.

Name of Researcher	Level of division (%)	
	Before exiting pelvis	After exiting pelvis
Mallikarjun A et al., [3] 50 Cadavers	8.0	92.0
Prakash K et al., [4] 43 Cadavers	16.3	83.7
Guvencer M et al., [5] 25 Cadavers	48.0	52.0
Pokomy D et al., [12] 91 Cadavers	20.9	79.1
Ugrenovic S et al., [19] 100 Cadavers	4.0	96.0
Current Study 30 Cadavers	1.7	98.3

[Table/Fig-7]: Level of division of sciatic nerve in comparison with the previous studies.

reach to the base of the limb bud. The surged cones of these axons incompetent to drill the area of dense mesenchyme or mesenchyme containing glycosaminoglycans. The axons drive for the lower limb are so divert over the expanding pelvis anlagen.

The motor axons infuse in a specific pattern and form lumbosacral plexus, when they reached at the base of lower limb bud. This zone makes a decision making area for axons. Axons from the dorsal divisions of the plexus tend to develop into dorsal side and axons from the ventral divisions of the plexus tend to develop into ventral side of limb bud.

Many factors play a role in controlling axonal specification, migration and projection, including the Lim and Hox homeobox proteins, ephrin signaling, Et-S transcription factors and cell adhesion molecules such as Type II cadherins and nCam. In response to retinoic acid signaling from the paraxial mesoderm, the motor neurons that innervate the limb bud form in the Lateral Motor Columns (LMCs) within the neural tube. The LMC has two divisions, one is LMCm (medial) and another is LMCl (lateral), which are differentiated by the various expression of Lim homeobox proteins and deal to the ventral and dorsal limb mesenchyme, respectively. LMCm and LMCl axon travel with common pathway towards the plexus, where they halt and shift to their nearest neighbors: the remaining term and the timing of the subsequent in-growth into the limb bud are identified by signals from the limb mesenchyme such as ephrin and semaphoring 3A.

The SN carries both dorsal and ventral divisions of ventral rami of SN. Its two terminal branches (divisions) only separate its ventral components (tibial nerve) and dorsal components (common peroneal nerve). A number of molecular signaling factors are responsible for its early division.

LIMITATIONS

Sample size of specimens and variations of nerve was not studied according to gender.

CONCLUSION

Knowledge of anatomical variation of the SN is having lots of importance to orthopedic, anaesthetic and surgeons. During posterior hip operations, High division develops in sciatica, nerve injury during deep intramuscular injections in gluteal region, piriformis syndrome, failed SN block in anesthesia and injury. Lower limb surgeries and in the interpretation of sciatic neuropathy can be complicated by variation in division of SN. In this regard, variations in the course and level of division of SN serves anaesthetist during sciatic block to improve clinical results. Hence, pre-operative nerve imaging and extra operative alertness are suggested during different surgical procedures of the gluteal regions.

REFERENCES

- [1] Saritha S, Praveen Kumar M, Supriya G. Anatomical variations in the bifurcation of the sciatic nerve, a cadaveric study and its clinical implications. *Anat Physiol*. 2012;2(5):02-05.
- [2] Anbumani TL, Selvi TA, Ammal AS. Sciatic nerve and its variations: an anatomical study. *Int J Anat Res*. 2015;3(2):1121-27.
- [3] Mallikarjun A, Sangeetha V. Study on variant anatomy of sciatic nerve. *J Clin Diagn Res*. 2014;8(8):07-09.
- [4] Prakash KD, Amanrao BP, Karan K, Santosh S. Study of anatomical variations of the sciatic nerve and its importance to clinicians and anesthetist. *Int J Curr Res*. 2014;6(7):7518-21.
- [5] Guvencer M, Iyem C, Akyer P, Tetik S, Naderi S. Variation in the high division of the sciatic nerve and relationship between the sciatic nerve and the piriformis. *Turkish Neurosurgery*. 2009;19(2):139-44.
- [6] Shashtrakar R, Nakhate M, Sawant VG. Study of variation in the high division of sciatic nerve and its relationship with the Piriformis muscle. *Med Res Chron*. 2015;2(3):359-65.
- [7] Surke SB, Badaam AM. High division of sciatic nerve: A cadaveric study. *International Journal of Anatomy, Radiology and Surgery*. 2016; 5(4):18-20.
- [8] Rani P, Kalra S. A cadaveric study of normal and variant levels of division of sciatic nerve and coupled anomalies with clinical application in surgical interventions. *Int J Anat Res*. 2015;3(3):1230-36.
- [9] Patel S, Shah M, Vora R, Zalawadia A, Rathod SP. A variation in the high division of the sciatic nerve and its relation with piriformis muscle. 2011;1(2): 27-30.
- [10] Demiryurek D, Bayramoglu A, Erbil M, Aldur MM, Mustafa ES. Bilateral divided piriformis muscle together with the high division of the sciatic nerve. *Gazi Med J*. 2002;13:41-44.
- [11] Gonzalez P, Pepper M, Sullivan W, Akuthota V. Confirmation of needle placement within the piriformis of a cadaveric specimen using anatomic landmarks and fluoroscopic guidance. *Pain Physician*. 2008;11(3):327-31.
- [12] Pokomy D, Jahoda D, Veigl D, Pinskerova V, Sosna A. Topographic variations of the relationship of the sciatic nerve and the piriformis muscle and its relevance to palsy after total hip arthroplasty. *Surg Radiol Anat*. 2006;28:88-91.
- [13] Shewale AD, Karambelkar RR, Umarji BN. Study of variations in the divisions, course and termination of the sciatic nerve. *JKIMSU*. 2013; 2(1):62-68.
- [14] Adibatti M and Sangeetha V. Study on variant anatomy of sciatic nerve. *J Clin Diagn Res*. 2014;8(8):07-09.
- [15] Mengistu D, Amanuel T. Variations of sciatic nerve its exit in relation to piriformis muscle in the northern Ethiopia. *International Journal of Pharma Sciences and Research*. 2014;5(12):953-56.
- [16] Chiba S. Multiple positional relationships of nerves arising from the sacral plexus to the piriformis muscle in humans. *Kaibogaku Zasshi*. 1992;67(6):691-724.
- [17] Machado FA, Babinski MA, Brasil FB, Favorito LA, Abidu Figureiedo M, Costa MG. Anatomical variations between sciatic nerve and piriform muscle during fetal period in human. *Int J Morphol*. 2003;21(1):29-35.
- [18] Pecina M. Contribution to the etiological explanation of the piriformis syndrome. *Acta Anat (Basel)*. 1979;105:181-87.
- [19] Ugrenovic S, Jovanovic I, Krstic V, Stojanovic V, Vasovic L, Antic S, et al. The level of the sciatic nerve division and its relations to the piriform muscle. *Vojnosanit Pregl*. 2005;62(1):45-49.
- [20] Beaton LE, Anson BJ. The relation of the sciatic nerve and its subdivisions to the piriformis muscle. *Anat Rec*. 1937;70:01-05.
- [21] Beaton LE. The sciatic nerve and piriform muscle: Their interrelation a possible cause of coccygodynia. *J Bone Joint Surgery Am*. 1938;20:686-88.
- [22] Schoenwolf G, Bleyl S, Brauer P, Francis-West P. *Larsen's Human Embryology*. 4th ed. Philadelphia: Churchill Livingstone Elsevier, 2009.

AUTHOR(S):

1. Dr. Zarna Patel
2. Dr. Sudarshan Gupta
3. Dr. Hiren Chavda
4. Dr. Nishita Jethava

PARTICULARS OF CONTRIBUTORS:

1. Assistant Professor, Department of Anatomy, Gujarat Medical Education Research Society, Gandhinagar, Gujarat, India.
2. Associate Professor, Department of Anatomy, Gujarat Medical Education Research Society, Gandhinagar, Gujarat, India.
3. Assistant Professor, Department of Anatomy, Gujarat Medical Education Research Society, Gandhinagar, Gujarat, India.

4. Tutor, Department of Anatomy, Gujarat Medical Education Research Society, Gandhinagar, Gujarat, India.

NAME, ADDRESS, E-MAIL ID OF THE CORRESPONDING AUTHOR:

Dr. Zarna Patel,
Assistant Professor, Department of Anatomy,
Gujarat Medical Education Research Society Medical
College, Civil Hospital Campus,
Pathikasharam, Sector-12,
Gandhinagar-382012, Gujarat, India.
E-mail: zdpdoctor@yahoo.com

FINANCIAL OR OTHER COMPETING INTERESTS:

None.

Date of Publishing: **Apr 01, 2017**