

# Multidetector Computed Tomography Study of Anatomical Variations of Ethmoidal Sinuses

VISHWANATH T THIMMAIAH

## ABSTRACT

**Introduction:** Anatomical variations of ethmoidal sinuses are complex and surgically very important. Preoperative detection of these variants is important to prevent surgical complications. Multidetector Computed Tomography (MDCT) is the modality of choice for evaluation of these variants of ethmoidal sinuses.

**Aim:** The present work was carried out to study the normal anatomical variations of ethmoidal sinuses by 128 slice MDCT.

**Materials and Methods:** This was a retrospective analysis of paranasal sinuses in 500 cases by MDCT in adults. Axial images of Paranasal Sinuses (PNS) were taken by 128 MDCT, with patients in supine position. Axial images were further reconstructed in both coronal and sagittal planes to evaluate common variations of ethmoidal sinuses. Statistical analysis was done using SPSS version 20.0 and

95% Confidence Interval values (CI) were calculated for each variant of ethmoidal sinuses.

**Results:** Present study shows agger nasi cells as the most common anatomical variant with 76.8% cases (95% CI:73.1-80.5), followed by frontal cells in 50.8% cases (95% CI:46.4-55.2), Haller cells in 41.2% (95% CI:36.9-45.5), Onodi cells in 35.4% (95% CI:31.2-39.6), frontal bullar in 27.4% (95% CI:23.5-31.3), supraorbital cells in 19.2% (95% CI:15.7-22.6) and suprabullar cells in 14.4% cases (95% CI:11.3-17.5).

**Conclusion:** Ethmoidal sinuses form a major component of paranasal sinuses that have high prevalence of anatomical variations. These cells are frequent causes for complicated sinus inflammatory pathologies and failed sinus surgeries. The surgeons must be aware of the anatomical variations to avoid untoward surgical complications and for better surgical outcome.

**Keywords:** Agger nasi, Frontal cells, Paranasal sinuses

## INTRODUCTION

Paranasal sinuses are group of air filled cavities that start developing from intrauterine life to early adulthood. Ethmoidal air cells are present at birth and are one among the paranasal sinuses having highest anatomical variations [1]. Anatomical variants are important to know as they are associated with higher risk of inflammatory process and post sinus surgery outcomes [2]. The success of functional endoscopic sinus surgery depends upon adequate details of anatomy of ethmoidal and other paranasal sinuses. MDCT is the modality of choice for evaluation of normal anatomical variations of ethmoidal sinuses. Acute and chronic rhinosinusitis are the most common medical problems encountered in day today practice and understanding the ethmoidal sinus anatomy and its variations will help surgeons for better outcome of medical or surgical management [3].

## MATERIALS AND METHODS

A retrospective descriptive study was undertaken in the Department of Radiology, JSS Medical College and Hospital, Mysuru, Karnataka, India over a period of three months starting from June 2016 till August 2016. A total of 584 cases underwent MDCT of paranasal sinuses for different indications of sinonasal pathologies, out of which 500 cases satisfying inclusion criteria were included in the study. All patients above 18 years of age and of both sexes who underwent MDCT scans involving paranasal sinuses were included in the study. Post-traumatic/inflammatory/neoplastic lesions with erosion/distortion of paranasal sinuses were excluded from the study.

### Data Collection

Axial images of paranasal sinuses were taken with Philips Ingenuity Core 128 slice MDCT (Netherlands). Patient was positioned supine with head first and axial sections were captured with helix type of scan by fixing the tube current at

120kVp and 117mAs. High resolution images were obtained with scan parameters of collimation 64 x 0.625, Pitch of 0.39, field of view (FOV) of 220 mm, filter at Y-sharp (YC), slice thickness of 1 mm, window centering at 200 and window width of 2000. Multiplanar reconstruction was done from axial images in a dedicated work station to obtain coronal and sagittal images without any loss of volume data. Images were stored in hospital Picture Archiving and Communication System (PACS) and then the images were retrieved from hospital data base system obtaining the inpatient number. All the findings were reported by a single radiologist and analysed retrospectively.

## STATISTICAL ANALYSIS

All the data was entered in Microsoft excel sheet for analysis. Categorical variables were reported as proportions. Analysis was done using Microsoft Excel 2013, SPSS 20.0. For 95% CI values were calculated using a confidence Interval calculator for proportional values.

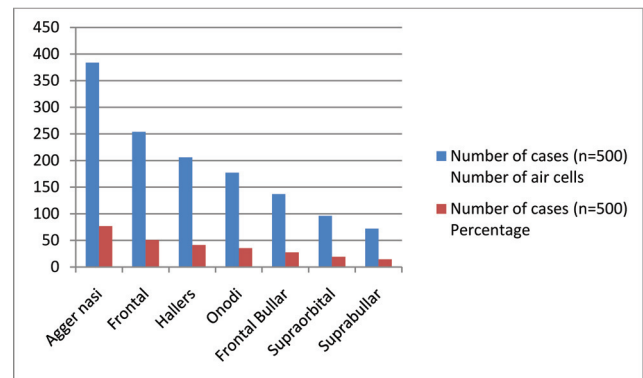
## RESULTS

Out of 500 cases, 316 (63.2%) were males and 184 (36.8%) were females, age of the cases ranged from 19 to 70 years with a mean age of 35 years. Distribution of anatomical variants is shown in [Table/Fig-1] with bar diagram [Table/Fig-2]. Though, more than one anatomical variant was seen in a single case, the study was intended to analyse the frequency of each anatomical variant of ethmoidal sinuses.

Agger nasi cells were identified in the sagittal plane by their anterior most location among the ethmoid groups of air cells and were the most common anatomical variant encountered in our study in 76.8% cases with 95% CI of 73.1-80.5 [Table/Fig-3a]. Frontal cells were better seen on coronal reformatted images [Table/Fig-3b] as well-defined air cells located inbetween the frontal sinus and agger nasi cells, which may or may not extend into the frontal sinus and were seen in 50.8% cases with 95% CI of 46.4-55.2. Haller cells [Table/Fig-3c]

| Anatomical Variations of Ethmoidal Air Sinuses | Number of Cases (n=500) |            | 95% Confidence Level (CI) |
|--|-------------------------|------------|---------------------------|
|  | Number of air Cells     | Percentage |                           |
| Agger nasi                                     | 384                     | 76.8       | 73.1-80.5                 |
| Frontal  | 254                     | 50.8       | 46.4-55.2                 |
| Hallers  | 206                     | 41.2       | 36.9-45.5                 |
| Onodi  | 177                     | 35.4       | 31.2-39.6                 |
| Frontal Bullar                                 | 137                     | 27.4       | 23.5-31.3                 |
| Supraorbital                                   | 96                      | 19.2       | 15.7-22.6                 |
| Suprabullar                                    | 72                      | 14.4       | 11.3-17.5                 |

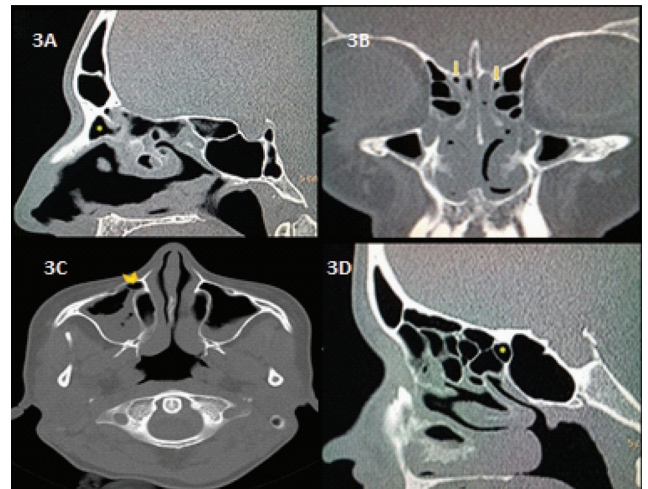
[Table/Fig-1]: Distribution of anatomical variations of ethmoidal air sinuses with 95% confidence interval values.



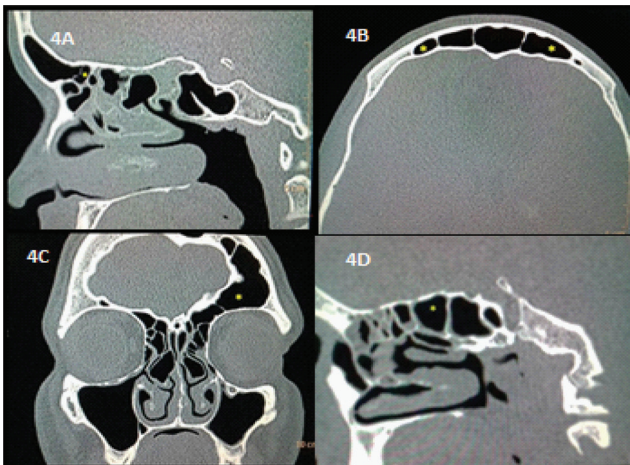
[Table/Fig-2]: Bar diagram showing distribution of anatomical variations of ethmoidal air cells.

were well appreciated in axial plane, being present along the medial part of the roof of maxillary antrum, inferior to ethmoid bulla and lateral to uncinata process, found in 41.2% with 95% CI values of 36.9-45.5. Onodi cells, the posterior most ethmoid cells were present in 35.4% of cases with 95% CI values of 31.2-39.6. They were better viewed in sagittal plane [Table/Fig-3d]. Frontal bullar cells were seen as air cells present above the ethmoidal bulla which pneumatize along the skull base towards the frontal sinus. They were viewed in sagittal plane in 27.4% of cases with 95% CI of 23.5-31.3 [Table/Fig-4a]. Supraorbital ethmoidal cells were the posterior group of frontal recess cells being present posterior to frontoethmoidal recess, seen in 19.2% of cases with 95% CI of 15.7-22.6 and were better analyse in axial and coronal planes [Table/Fig 4b,c]. The least common variant encountered in our study was suprabullar type in 14.4% of cases with 95% CI of 11.3-17.5 which were studied in sagittal plane [Table/Fig-4d].

Other anatomical variations which were often confused with ethmoidal air sinuses were also encountered in the study,



[Table/Fig-3a-d]: (a) Sagittal reformatted MDCT image showing agger nasi cell; (b) Coronal MDCT image with frontal cell; (c) Haller cell on axial CT scan image; (d) Sagittal reformatted MDCT image agger nasi cell.



**[Table/Fig-4a-d]:** (a) Sagittal reformatted MDCT image with frontal bullar cell; (b) Axial MDCT scan image showing supraorbital ethmoidal cell; (c) Coronal reformatted MDCT image with supraorbital ethmoidal cell; (d) Sagittal reformatted MDCT image showing suprabullar cell.

such as pneumatized crista galli (2 cases), dehiscent roof of frontal sinus (1 case), rudimentary frontal sinus (1 case) and absent intersphenoid septum (2 cases).

## DISCUSSION

Paranasal sinus anatomy is not simple and among them ethmoidal sinuses are very complex with their normal and frequent presence of anatomical variations. Ethmoidal sinuses are pneumatized at birth and show variable development up to adulthood. There are mainly two normal anatomical variants that occur during ethmoidal labyrinth development. Extramural cells type, which pneumatize and protrude externally to ethmoid labyrinth and intramural type, which pneumatize and remain within the ethmoid labyrinth. Extramural type comprises mainly agger nasi cells, frontal cells, supraorbital ethmoid cells, Haller cells and Onodi cells. Intramural type comprises frontal bulla cells, suprabullar cells, and ethmoid bulla [4]. Thorough knowledge of ethmoidal sinus anatomy and their variations should be known by operating surgeons, as these cells are in close proximity to drainage pathways of major paranasal sinuses and predispose for recurrent inflammation of sinuses.

Agger nasi cells are anterior most ethmoid air cells and are present at birth in 98% of cases. These cells were first described by H. Meyer and are present anterolaterally and inferior to the frontoethmoidal recess, above the attachment of middle turbinate [5]. Agger nasi cells have lateral relationship to the orbit and lacrimal sac. Depending upon the size of pneumatization, these cells contribute to narrowing of frontonasal duct and are frequent causes for persistent frontoethmoidal pain, chronic sinusitis and majority of revision sinus surgeries [6]. Endoscopically agger nasi cells correspond

to a bulge in the nasal wall anterior to middle turbinate and surgeon can easily identify these cells [7]. The agger nasi cells are best visualized on sagittal and coronal reformatted MDCT images for exact numbers and size of the pneumatized cell. In our study the agger nasi cell constituted the most common type with the maximum of 76.8% of cases.

Frontal cells or Kuhn's cells are group of anterior ethmoid cells that are closely related to agger nasi cells and are classified into four types depending upon the pneumatization patterns. Type I is most common with prevalence of 22-24%, Type II of 4%, Type III of 3% and Type IV being very rare [8]. In Type I, single cell is located inferior to frontal sinus and above agger nasi cells. In Type II, two or more anterior ethmoidal cells are present above agger nasi cells and may extend into frontal sinus. In Type III, single large pneumatized anterior ethmoidal cell is present above agger nasi cell extending into frontal sinus and Type IV are isolated cells located within frontal sinus separately [9]. Axial and coronal reformatted CT images are best to demonstrate these cells. Frontal cells are present in 41% of the specimens during cadaveric dissections [10]. Meyer TA et al., in their study of coronal CT scans of paranasal sinuses detected a prevalence of frontal cells in 20.4% of the studied individuals, while our study had 50.8% in the study subjects [11].

Haller cells orbitomaxillary cells are extramural ethmoidal air cells, first described by Swedish anatomist Albert von Haller in 1743. These cells are present along the medial part of roof of maxillary antrum, inferior to ethmoid bulla and lateral to uncinat process. Depending upon the number and size of the air cells, narrowing of infundibulum can occur, compromising maxillary ostium and causing recurrent maxillary sinusitis [12]. According to Stackpole and Edelstein, 34% of patients with sinonasal pathology can have Haller cells, with more the number of Haller cells more the chances for recurrent maxillary sinusitis [13]. If unrecognized preoperatively surgeon may inadvertently enter into maxillary sinuses and cause damage to adjacent structures.

Onodi cells or sphenoidal cells are the posterior most ethmoidal cells and were first described by Hungarian laryngologist Adolf Onodi, in the year 1904 [14]. Onodi cell usually pneumatize superolaterally or rarely superiorly to sphenoid sinus. When these pneumatize centrally it is called as central Onodi air cell. These cells are in close proximity to both optical and internal carotid canals, as little as 0.03 mm of bone separating them, hence their presence is of clinical importance as optic nerves and internal carotid arteries are at risk when these cells are handled, during surgical excision [15]. Onodi cells form a bulge at the optic nerve canal into the posterior ethmoid cell and if prominent can be at risk for damaging the optic nerve during sinus surgery. Within sphenoid sinus



the bulge is identified in the superolateral wall and surgeon unprepared can damage the optic nerve in an attempt to clear sphenoid sinus pathology [16]. Prevalence varies from 39% and 60%, depending upon how these cells are defined, detection techniques and racial factors [17]. Prevalence of Onodi cells is higher in Asian patients than western population regardless of the method used for identification [18]. Weinberger in his study had prevalence of Onodi cells in 39% of CT and 14% of sinus endoscopic surgeries [19]. In our study Onodi cells were present in 35.4% of studied cases. Analyzing Onodi cell in single plane, can result either missing or over interpretation of cells [20]. Multiplanar MDCT evaluation is thus important for its evaluation in both axial and sagittal reformatted images for sinus surgeries [21].

Frontal bullar cells are present above the ethmoidal bulla and pneumatize along the skull base towards the frontal sinus. Prevalence may be 10% according to Park SS et al., [8]. However, in our study there was higher incidence of 27.4%. These cells are bounded posteriorly by basal lamella of the middle turbinate and form a part of posterior boundary of the frontal recess and frontal sinus. These cells are best seen on sagittal images and they may form a bulge into frontal sinus depending upon the size of air cells [22].

Supraorbital ethmoidal cells constitute posterior group of frontal recess cells that are present posterior to frontoethmoidal recess and bounded superiorly and posteriorly by skull base. These cells extend superolaterally between medial orbital wall and ethmoidal roof, simulating multiple frontal sinuses, Type III frontal cells, suprabullar cells, frontal bulla cells or interfrontal sinus septal cells [23]. Pneumatization of orbital plate of the frontal bone posterior to the frontal recess forms supraorbital ethmoid cells and drains into lateral aspect of frontal recess. These cells can obstruct frontal sinus drainage depending upon the size of pneumatization and their pre-operative identification is important as these can be easily mistaken for frontal ostium. Zhang L et al., reported that the incidence of supraorbital ethmoidal sinus was 5.4% [24]. In study carried out by Owen RG et al., 15% of adults had one or more supraorbital ethmoidal cells [25]. In our study the prevalence was 19.2%. Both coronal and axial CT images are required for accurate identification of these cells. On axial images these cells are seen posterior to frontal sinus and on coronal reformatted sequential images as septate frontal sinus or lateral most frontal sinus present anterior to canal for anterior ethmoidal artery.

Suprabullar cells are ethmoidal cells that are present above the bullae and forms posterior border of frontal recess. These cells must to be differentiated from frontal bullar cells as they lie below frontal sinus ostium and do not extend towards frontal sinus. According to Park SS et al., their prevalence

was 8%, the present study showed slightly higher incidence of 14.4 %. Sagittal reformatted images are the best planes for visualization of these cells. Both frontal and suprabullar cells may be confused for skull base during sinus surgeries and may injure bone if proper care is not taken.

Other anatomical variations that are often confused with ethmoidal sinuses variants and wrongly diagnosed are pneumatized crista galli which is present in 2.4% of cases and pneumatize either from right or left frontal sinus that can be mistaken for frontal cells [26], dehiscent roof of frontal sinus, rudimentary frontal sinus which is present between 0.8% and 7.4% of cases [27], absent intersphenoid septum (11.4%) that can cause difficulty in differentiating posterior ethmoidal cells [28] and absent intersphenoid septum.

## LIMITATIONS

Unossified septae between ethmoidal air cells could not be differentiated on MDCT and categorical classification was not possible in those cases.

## CONCLUSION

Ethmoidal sinuses form a major component of paranasal sinuses and have higher anatomical variants compared to other sinuses. Their prevalence and anatomical variations should be known for operating surgeons to avoid untoward surgical complications also aiding in better medical and surgical outcomes. Such population studies give an insight into the true prevalence of the anatomic variations and provide valuable information to the operating surgeons.

## REFERENCES

- [1] Scuder AJ, Harnsberger HR, Boyer RS. Pneumatization of the paranasal sinuses: normal features of importance to the accurate interpretation of CT scans and MR images. *Am J Roentgenol.* 1993;160:1101-04.
- [2] Aygun N, Zinreich SJ. Imaging for functional endoscopic sinus surgery. *Otolaryngol Clin N Am.* 2006;39:403-16.
- [3] Al-Abri R, Bhargava D, Al-Bassam W, Al-Badaai Y, Sawhney S. Clinically significant anatomical variants of the paranasal sinuses. *Oman Medical Journal.* 2014;29(2):110-13.
- [4] Bent JP, Culty-Siller C, Kuhn FA. The frontal cell as a cause of frontal sinus obstruction. *Am J Rhinol.* 1994;8:185-91.
- [5] Eskiizmir GA. The role of agger nasi air cells in revision endoscopic sinus surgery. *Otolaryngol Head Neck Surg.* 2005;133:464-65.
- [6] Brunner E, Jacobs JB, Shpizner BA, Lebowitz RA, Holliday RA. Role of the agger nasi cell in chronic frontal sinusitis. *Ann Otol Rhinol Laryngol.* 1996;105(9):694-700.
- [7] Earwaker J. Anatomic variants in sinonasal CT. *Radiographics.* 1993;13:381-415.
- [8] Park SS, Yoon BN, Cho KS and Roh HJ. Pneumatization pattern of the frontal recess: relationship of the anterior-to-posterior length of frontal isthmus and/or frontal recess with the volume of agger nasi cell. *Clin Exp Otorhinolaryngol.* 2010;3:76-83.
- [9] Gonçalves FG, Jovem CL, Moura LO. Computed tomography of intra- and extramural ethmoid cells: iconographic essay. *Radiol Bras.* 2011;44(5):321-26.
- [10] Eweiss AZ, Khalil HS. The prevalence of frontal cells and their

- relation to frontal sinusitis: a radiological study of the frontal recess area. *ISRN Otolaryngology*. Volume 2013 (2013), Article ID 687582, 4 pages.
- [11] Meyer TK, Kocak M, Smith MM, Smith TL. Coronal computed tomography analysis of frontal cells. *Am J Rhinol*. 2003;17(3):163-68.
- [12] Laine FJ, Smoker WR. The osteomeatal unit and endoscopic surgery: Anatomy, variation and imaging findings in inflammatory disease. *Am J Roentgenol*. 1992;159:849-57.
- [13] Stackpole AS, Edelstein DR. The anatomic relevance of the Haller cell in sinusitis. *Am J Rhinol*. 1997;11:219-23.
- [14] Thanaviratnanich S, Chaisiwamongkol K, Kraitrakul S, Tangsawad W. The prevalence of an Onodi cell in adult Thai cadavers. *Ear Nose Throat J*. 2003;82(3):200-04.
- [15] Stammberger HR, Kennedy DW. Anatomic terminology group. paranasal sinus: anatomic terminology and nomenclature. *Ann Otol Rhinol Laryngol*. 1995;167:07-16.
- [16] Kainz J, Stammberger H. Danger areas of the posterior rhinobasis. An endoscopic and anatomical-surgical study. *Acta Otolaryngol*. 1992;112(5):852-61.
- [17] Driben JS, Bolger WE, Robles HA. The reliability of computerized tomographic detection of the Onodi (sphenoid) cell. *Am J Rhinol*. 1998;12:105-11.
- [18] Kasemiri P, Thanaviratnanich S, Puttharak W. The prevalence and pattern of pneumatization of Onodi cell in Thai patients. *J Med Assoc Thai*. 2011;94(9):1122-26.
- [19] Weinberger DG, Anand VK, Al-Rawi M, Cheng HI, Messina AV. Surgical anatomy and variations of the Onodi cell. *Am J Rhinol*. 1996;10:365-70.
- [20] Unal B, Bademci G, Bilgili YK, Batay F, Avci E. Risky anatomic variations of sphenoid sinus for surgery. *Surg Radiol Anat*. 2006;28:195-201.
- [21] Hoang JK, Eastwood JD, Tebbit CL, Galstonbury CM. Multiplanar sinus CT : a systemic approach to imaging before functional sinus surgery. *AJR*. 2010;194(6):527-36.
- [22] Kew J, Rees GL, Close D, Sdralis T, Sebben RA, Wormald PJ. Multiplanar reconstructed computed tomography images improve depiction and understanding of the anatomy of the frontal sinus and recess. *Am J Rhinol*. 2002;16(2):119-23.
- [23] Coates MH, Whyte AM, Earwaker JW. Frontal recess air cells: spectrum of CT appearances. *Australas Radiol*. 2003;47:04-10.
- [24] Zhang L, Han D, Ge W, Tao J, Wang X, Li Y, et al. Computed tomographic and endoscopic analysis of supraorbital ethmoid cells. *Otolaryngol Head Neck Surg*. 2007;137:562-68.
- [25] Owen RG, Kuhn FA. Supraorbital ethmoid cell. *Otolaryngol Head Neck Surg*. 1997;116(2):254-61.
- [26] Basic N, Basic V, Jukic T. Computed tomographic imaging to determine the frequency of anatomical variations in pneumatization of the ethmoid bone. *Eur Arch Otorhinolaryngol*. 1999;256:69-71.
- [27] Harris AMP, Wood RE, Nortje CJ, Thomas CJ. Gender and ethnic differences of the radiographic image of the frontal region. *J Forensic Odontostomatol*. 1987;5:51-57.
- [28] Banna M, Olutola PS. Patterns of pneumatization and septation of the sphenoidal sinus. *J Can Assoc Radiol*. 1983;34:291-93.

**AUTHOR(S):**

1. Dr. Vishwanath T Thimmaiah

**PARTICULARS OF CONTRIBUTORS:**

1. Associate Professor, Department of Radiology, JSS Medical College and Hospital, JSS University, Mysuru, Karnataka, India.

**NAME, ADDRESS, E-MAIL ID OF THE CORRESPONDING AUTHOR:**

Dr. Vishwanath T Thimmaiah,  
#15, Block-08, JSS Layout 1st Stage,  
Dr Rajkumar Road, Mysuru-570019, Karnataka, India.  
E-mail: vishurad@gmail.com

**FINANCIAL OR OTHER COMPETING INTERESTS:**

None.

Date of Publishing: **Apr 01, 2017**