

# Gastric Adenocarcinoma in a Male Patient with Plummer-Vinson Syndrome

MATHEWS JAMES, ANANDHI AMARANATHAN, NISHKARSH MEHTA, HARSHIT KRAMADHARI

## ABSTRACT

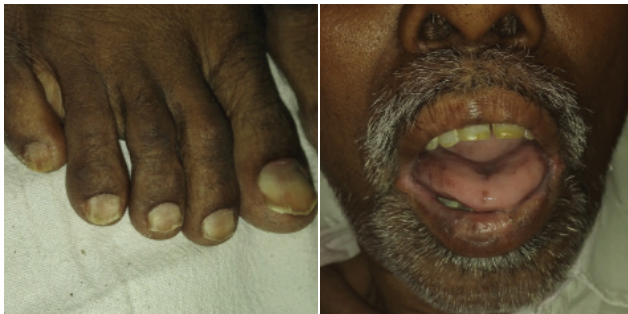Plummer-Vinson syndrome (PVS) also known as Paterson- Brown- Kelly syndrome or sideropenic dysphagia has been known for over a century. The syndrome is characterised by a triad of Iron Deficiency Anaemia (IDA), dysphagia and oesophageal webs. It is seen mostly in middle aged women and is considered pre-cancerous condition as 3-15% of the patients develop squamous cell carcinoma involving upper digestive tract mainly oral cavity, tongue, hypopharynx and oesophagus. However, gastric adenocarcinoma has rarely been reported in PVS. We present a case of gastric carcinoma associated with PVS in a 52 years old male patient, presented with history of progressive dysphagia and severe anaemia requiring transfusion. Further, evaluation revealed oesophageal webs and locally advanced antral adenocarcinoma. Literature review has shed light on five similar cases so far.

**Keywords:** Anaemia, Dysphagia, Pre-cancerous condition

## CASE REPORT

A 52-year-old male patient presented with symptoms of progressive dysphagia over 6 months associated with regurgitation. It progressed from solids to semisolids during this time period. He gave a history of melena for 3 months and anaemic symptoms. He had loss of weight and loss of appetite for 2 months. He was diagnosed as a case of PVS elsewhere and underwent endoscopic bougienage for dysphagia. He had received six transfusions in the mean time for severe anaemia. He presented to us since there was no relief of symptoms despite intervention.

On examination, the patient was thin and asthenic. He had a Body Mass Index of 14.5. He was pale and had platynychia [Table/Fig-1a]. The patient had glossitis and angular cheilitis



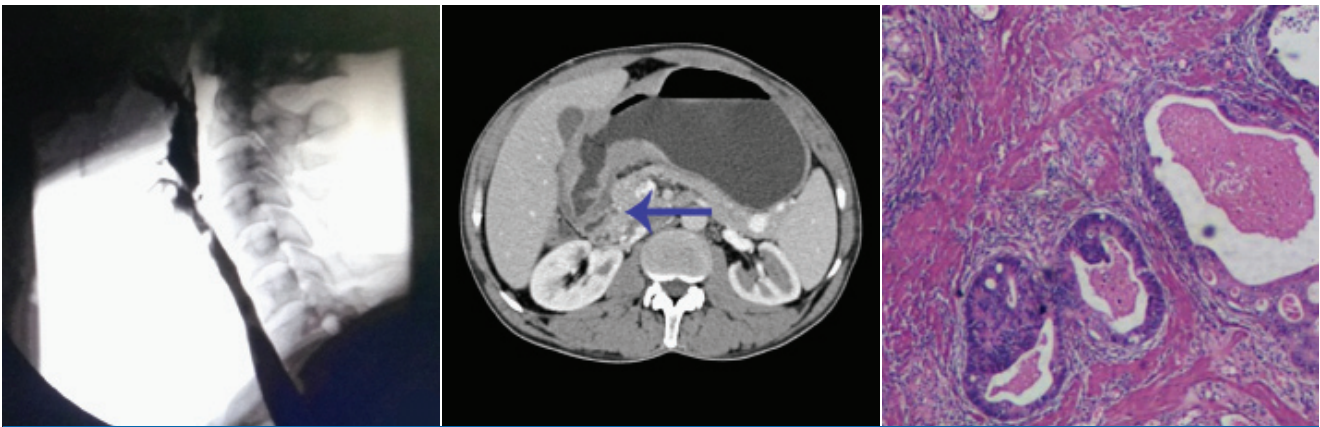
**[Table/Fig-1a-b]:** (a) Shows platynychia and koilonychia involving toes; (b) Shows pale oral mucosa with glossitis and pigmentation along with angular cheilitis.

[Table/Fig-1b]. He had no skin pathologies. A vague, non tender mass was palpable in the right hypochondrium, which was moving with respiration. It had lobulated surface and was firm in consistency. Rest of the abdomen appeared normal.

Blood investigations revealed iron deficiency anaemia with haemoglobin 8.1 gm/dL. Peripheral smear showed microcytic hypochromic anaemia with mild anisopoikilocytosis. Serum ferritin was 38.9 ng/mL. Upper gastrointestinal endoscopy revealed oesophageal webs at cricopharynx and at 32 cm. There was an ulceroproliferative growth in the distal antrum involving pylorus, lesser curvature and the first part of the duodenum, through which the scope was negotiated distally with difficulty.

Barium swallow showed an oesophageal web in hypopharynx arising from the anterior wall [Table/Fig-2a]. Ultrasound showed a 9x6 cm irregular lobulated mass in the first part of the duodenum with loss of gut signature. The mass was closely abutting pancreas and right lobe of the liver. Contrast enhanced CT confirmed size and location of the tumour. It was found to be infiltrating head of pancreas with metastatic pre-caval and peri pancreatic lymph nodes [Table/Fig-2b]. Biopsy from the growth showed well-differentiated adenocarcinoma [Table/Fig-2c].

The patient did not require further dilatation as he was tolerating semi-solid food. The case was discussed in the tumour clinic with medical oncologists and radiotherapist. It



**[Table/Fig-2a-c]:** (a) Esophagogram showing anterior hypopharyngeal web; (b) CT-scan image showing irregular antropyloric wall thickening abutting pancreas; (c) Deep endoscopic biopsy showing well differentiated adenocarcinoma invading muscularis propria (H&E 200X).

was concluded that patient had poor performance status that precluded chemotherapy and surgery as well. Hence, he was given blood transfusion and discharged.

Patient defaulted and did not come for follow-up.

## DISCUSSION

Plummer-Vinson syndrome has been known since the late 19<sup>th</sup> century when Blackstein described a case with anaemia, oesophageal stenosis, and dysphagia. Though, Plummer described similar cases in 1912 followed by Vinson, his student reporting a case series in 1922; both being physicians in Mayo clinic, it was Sir Arthur Hurst in 1926, who coined the eponym [1]. During the same time period two British otolaryngologists, Paterson and Kelly also described this syndrome. But this condition was endemic in the Scandinavian nations, especially in Northern Sweden where it is called sideropenic dysphagia since low serum iron was more common than anaemia [2].

The incidence rate has come down currently, thanks to nutritional improvement like food fortification and advanced health care. It is typically seen in middle-aged white women between 4<sup>th</sup> and 7<sup>th</sup> decades, accounting for 75-90% of patients [1]. Even though it is commonly seen in Caucasians in Northern countries, many cases have been reported from Japan [2].

The etiology of PVS is still debated but thought to be associated with a low dietary intake of vitamins and iron. Previous class of thought that the syndrome was a result of iron deficiency anaemia was challenged by Wynder when he reported that serum iron levels are normal in 68% of the patients as early as in 1958. But IDA does result in low iron-dependent oxidative enzymes which lead to degradation of pharyngeal muscles over time. This results in decreased amplitude of contraction and slower transit time [3]. The contribution of reduced neuronal nitric oxidase in this aspect cannot be ruled out [4]. The iron deficiency becomes apparent in upper digestive tract

because of the high cellular exchange rate [5]. Hence, the role of iron is still disputed [6]. The nutritional hypothesis of dietary deficiency in fresh fruits, vegetables, and meat leading to PVS has become widely accepted. Genetics and environment have a definite role since the syndrome is very rare in Africa where both malnutrition and IDA are prevalent. Autoimmune conditions like celiac disease, thyroid disease, inflammatory bowel disease, Sjogren's syndrome, rheumatoid disease and pernicious anaemia have been often reported in association with PVS [3]. Studies have shown that anaemia responds to iron preparations, whereas glossitis and cheilitis improve with vitamin B2.

Besides the triad, patients usually present with koilonychia, atrophic glossitis, cheilosis, early loss of teeth, achlorhydria, atrophic gastritis, keratitis, conjunctivitis, blepharitis, visual disturbances, dermatitis seborrheica, hyperkeratosis and splenomegaly [1]. Other oral manifestations include recurrent aphthous stomatitis, pale oral mucosa, oral candidiasis, erythematous mucositis, and atrophy of filiform followed by fungiform papilla and a burning sensation in mouth.

A diagnosis of PVS is made by demonstrating oesophageal web either by radiologic methods or endoscopy. Barium swallow is preferred to endoscopy as it identifies motility disorders and do not miss out the benign strictures. It is typically identified in upper oesophagus just below cricoid, eccentrically attached to its anterior wall. Waldenstrom proposed that cracks and ulcers from mechanical trauma on the atrophic mucosa at the entrance of oesophagus induce web formation [2]. Pathologically the web is made of atrophic or hypertrophic squamous cells, sometimes in the background of chronic submucosal inflammation [1], with degenerated atrophic muscularis mucosa and occasionally hyalinised cartilage.

Treatment of PVS is relatively straight forward with correction

of iron deficiency anaemia taking the cornerstone in management. The pharyngeal muscle power is restored and dysphagia is relieved prior to the disappearance of the web, following iron therapy [4]. This alone is sufficient to resolve the dysphagia in many cases, resistant cases requiring endoscopic bougienage. Most of them achieve prolonged remission with a single session, very few requiring multiple sessions.

The incidence of upper oesophageal malignancy is estimated to be 3-15% [2]. This relation was first suggested by Patterson and Kelly, however, was first documented by Ahlbom. In an early study, Ahlbom reported an astounding 70% of patients with upper GI malignancies who also had PVS. Women accounted for 90% of cases with post cricoid carcinoma alone, 90% of whom had associated PVS or achlorhydric anaemia. A similar high incidence of hypopharyngeal malignancy was reported in northern Swedish women where PVS was prevalent in the 1940's [2]. However, it is unusual for it to be associated with gastric adenocarcinoma. Five similar cases were found in literature, 3 involving the distal stomach [2,6], one each involving the whole body [7] and gastro-oesophageal junction [1]. All patients were female in the typical age group. Our patient had an advanced distal gastric adenocarcinoma infiltrating pancreas. The accepted theory is that the mucosal atrophy due to iron deficiency makes it fragile and susceptible to damage by the mechanical stimulus, predisposing to cancer. This is depicted by the multifocal oral malignancies reported in the earliest cases. Similarly, iron deficiency weakens the metabolic machinery set to protect and maintain genome as they are dependent on iron [6]. Even though PVS is a known premalignant condition, endoscopy is indicated for symptomatic treatment only and not for screening [8].

## CONCLUSION

The diagnosis of PVS is rare in the current medical scenario.

In established cases, elaborate evaluation of upper gastrointestinal tract is necessary to exclude possible malignancy, especially in patients presenting with chronic blood loss and anaemia requiring transfusion.

## ACKNOWLEDGEMENT

Authors are immensely grateful to Dr. Manish and Dr. Harsha for their technical help in preparing the final draft of this case report.

## Protection of Patients' Rights to Privacy

An informed consent has been obtained from the patient for the purpose of publication.

## REFERENCES

- [1] Kim KH, Kim MC, Jung GJ. Gastric cancer occurring in a patient with Plummer-Vinson syndrome: A case report. *World J Gastroenterol.* 2005;11(44):7048–50.
- [2] Kitabayashi K, Akiyama T, Tomita F, Saitoh H, Kosaka T, Kita I, et al. Gastric cancer occurring in a patient with Plummer-Vinson syndrome: report of a case. *Surg Today.* 1998;28(10):1051–55.
- [3] Gude D, Bansal D, Malu A. Revisiting Plummer Vinson syndrome. *Ann Med Health Sci Res.* 2013;3(1):119–21.
- [4] Miranda ALM, Dantas RO. Esophageal contractions and oropharyngeal and esophageal transits in patients with iron deficiency anemia. *Am J Gastroenterol.* 2003;98(5):1000–04.
- [5] Donohue-Cornejo A, Guzmán-Gastelum DA, Constandse-Cortéz D, Gaitán-Cepeda LA, Escalera CR. Squamous cell carcinoma in the tongue and Plummer-Vinson syndrome. A case report. *Revista Odontológica Mexicana.* 2011;15:189–92.
- [6] Hellara O, Hammami A, Njim L, Chaabène NB, Mansour WB, Loghmari H, et al. Gastric cancer occurring in a patient with Plummer-Vinson syndrome: an unusual association about one case. *J Afr Cancer Afr J Cancer.* 2013;5(4):224–27.
- [7] Köklü S, Bulut M, Cakal B, Bozkurt A, Yüksel O. Gastric cancer presenting with Plummer-Vinson Syndrome. *J Am Geriatr Soc.* 2009;57(5):933–34.
- [8] Tiwari AK, Laird-Fick HS, Ramesh K W, Hemanth K R. Surveillance for gastrointestinal malignancies. *World J Gastroenterol.* 2012;18(33):4507–16.

### AUTHOR(S):

1. Dr. Mathews James
2. Dr. Anandhi Amaranathan
3. Dr. Nishkarsh Mehta
4. Dr. Harshit Kramadhari

### PARTICULARS OF CONTRIBUTORS:

1. Senior Resident, Department of General Surgery, Jawaharlal Institute of Postgraduate Medical Education and Research, Puducherry, India.
2. Assistant Professor, Department of General Surgery, Jawaharlal Institute of Postgraduate Medical Education and Research, Puducherry, India.
3. Senior Resident, Department of General Surgery, Jawaharlal Institute of Postgraduate Medical Education and Research, Puducherry, India.

4. Senior Resident, Department of Radiology, Jawaharlal Institute of Postgraduate Medical Education and Research, Puducherry, India.

### NAME, ADDRESS, E-MAIL ID OF THE CORRESPONDING AUTHOR:

Dr. Mathews James,  
Plot No 85/86, 1<sup>st</sup> Cross, 2<sup>nd</sup> Main Road,  
Priyadarshini Nagar, Gorimedu,  
Puducherry-605006, India.  
E-mail: mathmoola@gmail.com

### FINANCIAL OR OTHER COMPETING INTERESTS:

None.

Date of Publishing: Apr 01, 2017