

# A Cross Sectional Study of Normal Variations of Sphenoid Sinus Through CT-Scan in North Karnataka, India

MANISHA S. CHOUGULE, PREETAM B. PATIL

## ABSTRACT

**Introduction:** In the humans, paranasal air sinuses play various roles like- make the skull light weight, add the resonance to the voice etc. We have frontal, ethmoid, maxillary and sphenoid sinuses. Out of these, sphenoid sinuses (SS) have got the importance because of trans-sphenoid approach for the pituitary surgeries and skull base surgeries. Therefore, the knowledge of anatomical variation of SS has a significant role in surgical access of pituitary fossa and also, can anticipate the difficulties in surgery.

**Aim:** This is the study to find out the variations of SS and their relations to adjacent neurovascular structures with surgical point of view.

**Materials and Methods:** Computed Tomography (CT) scans of 150 living subjects (53 females and 97 males) were taken in coronal, sagittal and axial planes. Contiguous slice CT technique was used with 1 mm section thickness. The p-value was calculated to find out the association between extent of pneumatization of sphenoid sinus and protrusion or dehiscence of maxillary nerve (MN), vidian nerve (VN), optic nerve (ON) or internal

carotid artery (ICA) in the sinus. Chi square test was used for the calculation of p-value.

**Results:** It was observed that there were 2 cases with conchal pneumatization, 29 cases with pre-sellar pneumatization, 47 cases with sellar pneumatization, 72 cases with post-sellar pneumatization. It was observed that pneumatization of greater wing of sphenoid sinus (GWS) in 40 cases, pterygoid process (PP) in 39 cases and anterior clinoid process (ACP) in 34 cases. Onodi cell were noticed in 17 sinuses. Protrusion of ICA was found in 27 sinuses. The p-value was highly significant for the association between pneumatization of sphenoid sinus and protrusion or dehiscence of nerves or ICA in the sinus. Chi square test was used for the calculation of p-value. Posterior attachment of Inter Sinus Septa (ISS) was noticed in the midline in 36 individuals (24%) and deviated from midline in 113 individuals (75%). Accessory septae were noticed in 76 sinuses (51%).

**Conclusion:** Due to widespread pneumatization of SS, it lies in close relation with MN, ON, VN & ICA. Newer techniques were helpful for the safety of the patient during intra-operative and post-operative period.

**Keywords:** Internal carotid artery, Maxillary nerve, Optic nerve, Pneumatization, Vidian nerve

## INTRODUCTION

Paranasal air sinuses are meant to make the skull light weight, give the resonance to the voice and help to make inspired air moist and warm. To clinicians they are important because of the sinusitis and complications related to it. In humans we have frontal, ethmoid, maxillary and sphenoid sinuses. Out of these, sphenoid sinus (SS) has got clinical significance in this new era of minimal invasive surgery. Especially for neurosurgeons, when they discovered the

trans-sphenoid approach for the pituitary surgeries and also for ENT surgeons for Functional Endoscopic Sinus Surgery (FESS); because of this the normal anatomical variations of the SS are important in surgeon's point of view [1].

Pneumatization varies in each and every individual. Because of variation in pneumatization, we get a lot of variations in SS and its relation with the neighboring neuro-vascular structures. These relations are important for the surgeons to anticipate difficulties and complications during surgeries.

## MATERIALS AND METHODS

This cross sectional study was conducted in the Department of Radiology, SDM Hospital, Dharwad during the period of April 2015 - July 2015. Total 150 CT scans were selected randomly from patients who fulfill our inclusion and exclusion criteria.

Ethical clearance was taken from our institute's ethical committee. We took written informed consent from the patient on the condition of concealing their identity.

Computed Tomography (CT) scans of 150 living subjects (53 females and 97 males) were taken in coronal, sagittal and axial planes. Contiguous slice CT technique was used with 1 mm section thickness. We studied the type of pneumatization, protrusion or dehiscence of neurovascular structures, presence of accessory septa and its attachment, termination of inter-sinus septa, etc. All subjects were between 18 to 70 years. We excluded subjects with acute or chronic sinusitis, FESS, trans-sphenoid surgery, head injury or intra-cranial infection.

CT sections were analyzed pertaining to variations in pneumatization of the sinus, presence of accessory septa with its attachment, position and posterior attachment of inter-sinus septa (ISS). Association of protrusion or dehiscence of the internal carotid artery (ICA), optic nerve (ON), maxillary nerve (MN) & vidian nerve (VN) with extent of pneumatization of SS was also studied.

The p-value was calculated to find out the association between protrusion of ON and the pneumatization of anterior clinoid process (ACP), protrusion of MN and pneumatization of greater wing of sphenoid (GWS) and protrusion of vidian nerve (VN) and pneumatization of PP. Chi square test was used to calculate the p-value.

## RESULTS

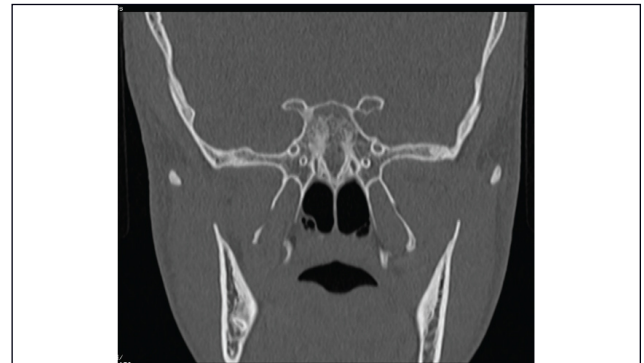
We studied 150 CT scans of Sphenoid sinuses (53-females, 97-Males).

### 1. Type of Sphenoid Sinus (SS)

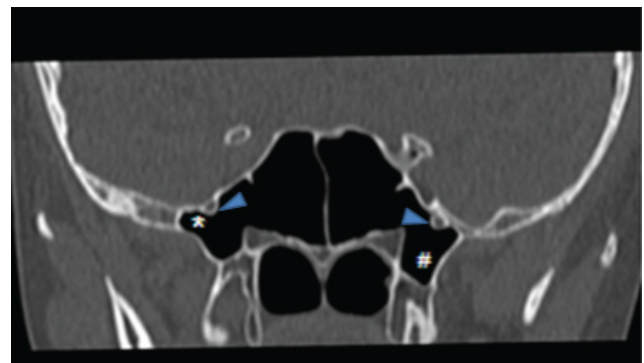
SS are classified according to the extent of pneumatization in relation to the sella turcica, as pre-sellar, sellar and post-sellar variety [2]. Total absence of pneumatization is called as conchal variety [Table/Fig-1]. Conchal pneumatization was well appreciated in coronal section of CT-scan & other types were well appreciated in sagittal sections of CT-scan. We noticed 2 conchal, 29 pre-sellar, 47 sellar, 72 post-sellar variety of SS.

### 2. Extent of Pneumatization

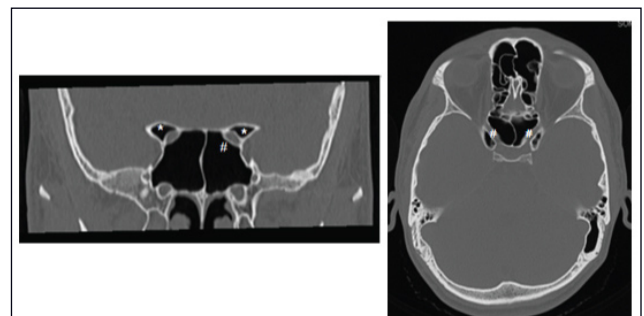
It was observed that pneumatization of greater wing of sphenoid sinus (GWS) in 40 sinuses, pterygoid process (PP)



[Table/Fig-1]: CT-scan of the sella, coronal section showing Conchal or absence of pneumatization of SS.



[Table/Fig-2]: Pneumatization of right GWS (\*) with protrusion of both MN (arrow heads) and pneumatized PP (#).



[Table/Fig-3]: Bilateral pneumatized ACP (\*) with both ON (#) passing through sinus.

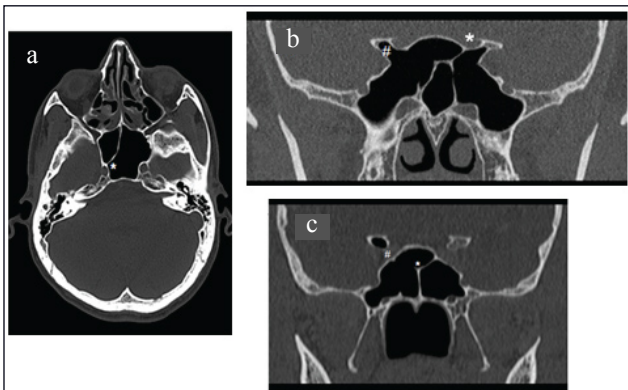
in 39 sinuses [Table/Fig-2] and anterior clinoid process (ACP) in 34 sinuses [Table/Fig-3 & 4].

### 3. Onodi Cell

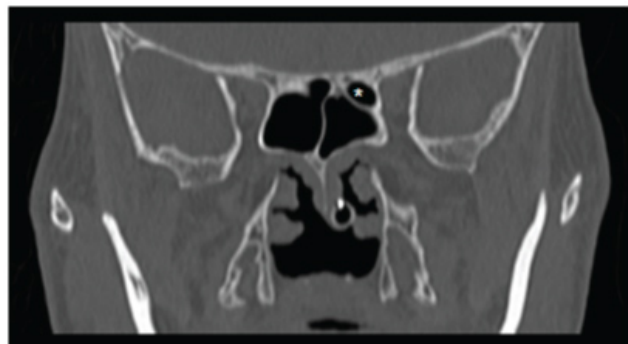
Onodi cell is posterior most ethmoid air cell which is incorporated in sphenoid sinus. It was observed in 17 sinuses [Table/Fig-5].

### 4. Protrusion of Neurovascular Structures

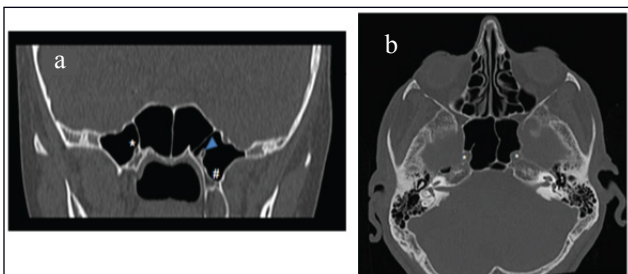
Usually protrusion of ON is associated with pneumatization of ACP [Table/Fig-3 & 4B], protrusion of MN is associated with pneumatization of GWS [Table/Fig-2], protrusion of



**[Table/Fig-4]:** (a) Termination of ISS on bony wall covering protruded left ICA (\*). (b) Bilateral ON protrusion with ACP pneumatization (#) and attachment of ISS over left ON (\*). (c) Left ON passing through the sinus (#) and insertion of bifurcated ISS on the bony wall covering both ON (\*).



**[Table/Fig-5]:** Right Onodi cell (\*).

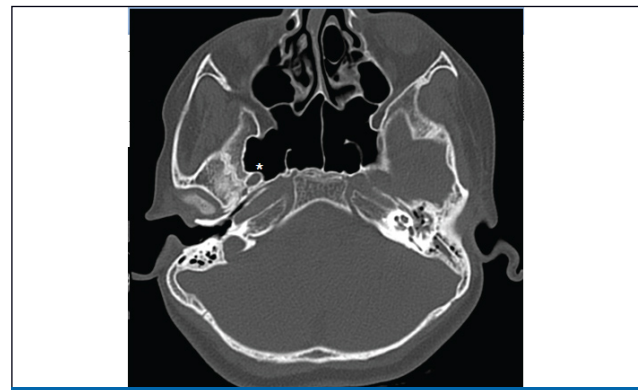


**[Table/Fig-6]:** (a) Attachment of accessory septa over bony wall covering right VN (\*) and left VN (arrow head) showing typical eye on stalk appearance due to pneumatization of left PP (#). (b) Protrusion of both ICA (\*) with accessory septa terminating over the bony wall covering left ICA.

vidian nerve (VN) is associated with pneumatization of PP. [Table/Fig-6a].

But, protrusion of these nerves can occur without pneumatization of ACP, GWS & PP also. In 3 cases protrusion of MN was observed without pneumatization of ACP, GWS and PP. Also, there was a case of protrusion of foramen ovale due to pneumatization of GWS [Table/Fig-7].

Protrusion of ICA was observed in 27 sinuses. Out of



**[Table/Fig-7]:** Protrusion of foramen ovale (\*) due to pneumatization of GWS.

		Protrusion of ON		
		Present	Absent	Total
Pneumatized ACP	Present	23	11	34
	Absent	14	102	116
	Total	37	113	150

**[Table/Fig-8]:** Relation between protrusion of Optic Nerve (ON) & pneumatization of Anterior Clinoid Process (ACP).  $\chi^2 = 43.707$ ,  $df = 1$ ,  $p < 0.05$

		Protrusion of MN		
		Present	Absent	Total
Pneumatized GWS	Present	33	7	40
	Absent	16	94	110
	Total	49	101	150

**[Table/Fig-9]:** Relation between protrusion of Maxillary Nerve & pneumatization of greater wing of sphenoid (GWS).  $\chi^2 = 61.583$ ,  $df = 1$ ,  $p < 0.05$

		Protrusion of VN		
		Present	Absent	Total
Pneumatized PP	Present	34	5	39
	Absent	14	97	111
	Total	48	102	150

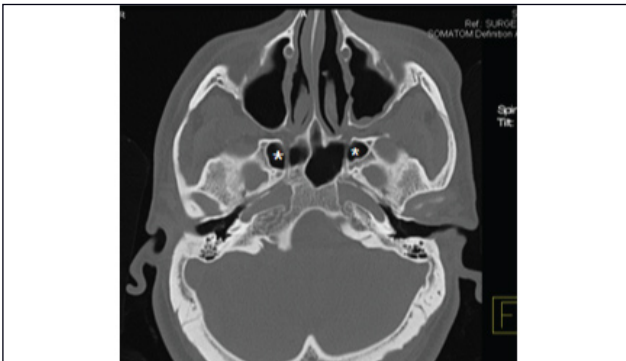**[Table/Fig-10]:** Relation between protrusion of Vidian nerve (VN) & pneumatization of pterygoid process (PP).  $\chi^2 = 73.744$ ,  $df = 1$ ,  $p < 0.05$

this, in 23 cases, protrusion of ICA was associated with pneumatization of ACP. This association was significant as p-value is significant ( $p < 0.05$ ). Total 20 sinuses were associated with both pneumatization of ACP & GWS. Our findings were enumerated in the [Table/Fig-8-10].

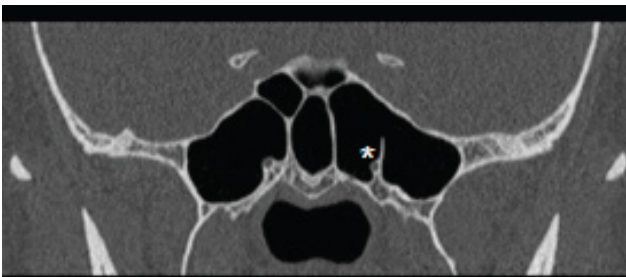The p-value was highly significant for all 3 findings. The p-value was calculated using Chi-square test.

### 5. Dehiscence of Neurovascular structures

Dehiscence of ON was noticed in 10 cases. In 3 cases



**[Table/Fig-11]:** Dehiscence of both MN (\*).



**[Table/Fig-12]:** Protrusion of right Vidian nerve (VN) with accessory septa terminating on it (\*). Also note the multiple septa within the SS.

dehiscent ON traverses through sinus [Table/Fig-5], while there was a case of dehiscent MN traversing through sinus [Table/Fig-11]. There was absence of dehiscent ICA.

## 6. Inter-Sinus Septum (ISS)

ISS was noticed in the midline in 36 individuals and deviated from midline in 113 individuals.

There was a lot of variation in the posterior attachment of ISS. It was over the bony wall covering ICA in 23 individuals [Table/Fig-4a], over the bony wall covering ON in 19 individuals [Table/Fig-4b & 4c]. While in a case, posterior attachment was over accessory septa [Table/Fig-4b], in the other it was over both ICA & ON and in another case it was diverged & attached to bony wall covering both ON [Table/Fig-4c].

## 7. Accessory septa

Accessory septa were noticed in 76 sinuses. These septa were either complete or partial. It shows attachment on bony wall covering ICA (27 sinuses) [Table/Fig-6b] or ON (6 sinuses) or MN (2 sinuses) or VN (2 sinuses) [Table/Fig- 6a & 12]. In other sinuses it terminates over ISS or any wall of the sinuses.

## DISCUSSION

Normal SS has two symmetrical cavities separated by ISS placed in the midline. ISS does not usually encroach

upon surrounding neuro-vascular structures. Absence of accessory septa, absence of protrusion and dehiscence of neuro-vascular structures within the sinus are noticed [3].

During normal development, a process takes place in which red bone marrow gets replaced by yellow marrow slowly. According to several studies, this conversion of red to yellow marrow is an important step in the pneumatization of paranasal air sinuses and mastoid air cells [4,5]. Failure of this step will lead to non development of air sinuses and SS is most commonly affected. In SS, this process starts in the anterior portion and moves posteriorly towards clivus [6-9]. To explain the relation between aeration and bone marrow conversion, many studies were done and each one forms their own hypothesis behind it [10]. Some authors proposed that changes in vasculature and temperature were promoting factors for marrow conversion [6,11] while others proposed that ratio of trabecular to cortical bone is the driving factor [12]. Pneumatization process starts with the invasion of the respiratory mucosa into the sphenoid fatty marrow conversion areas. Failure of this process by any means will lead to arrested pneumatization in adulthood [13].

## Type of Sphenoid Sinus

It was observed that there were 19% pre-sellar, 31% sellar, 48% post-sellar types of pneumatization. Two cases were of Conchal variety. S Elwany et al., [14] observed 30% pre-sellar, 71% post-sellar type of pneumatization. D Sethi et al., [15] observed pre-sellar in 27 % and post-sellar in 73% of sinuses. In another study done in Libiya by Ossama Hamid et al., [16], observed 2% conchal, 21% pre-sellar, 54.7% sellar and 22.3% post-sellar type of pneumatization. In most of the studies, it was observed that post-sellar variety is common except in Libiya. Post-sellar type offers maximum optimum conditions for trans-sphenoid approach to intra-cranial surgeries like spacious sinuses, thin walls of the sinuses. In the conchal type, surgeons require special instruments for the successful procedure.

## Extent of Pneumatization

Pneumatization of GWS was observed in 27%, PP in 26% and ACP in 23% cases. The p-value was significant for the association between pneumatization of GWS with the protrusion of MN, PP with the VN and ACP with the ON.

Hewaidi GH et al., [3] observed pneumatization of ACP in 15%, of GWS in 20 % and that of PP in 29% of the patients. Bolger et al., [13] identified pneumatization of ACP in 13% and of PP in 43% patients. John Earwaker [8] found pneumatization of GWS in 20% of patients. ACP pneumatization was observed in 4% and in 24% of patients by De Lano et al., [5] and Birsan et al., [11] respectively.



## Relations of Neuro-Vascular Structures

We observed protrusion of ICA in 18%, ON in 24%, MN in 32.5% and VN in 32% cases. Onodi cell was observed in 6% cases. ON dehiscence was noticed in 8.5% cases.

CT scan study done by Hewaidi GH et al., [3] protrusion of ICA was observed in 41% of patients and dehiscence of the artery in 30%. Protrusion and dehiscence of the ON was observed in 35.6% and 30.6% of patients respectively. Protrusion and dehiscence of the MN was observed in 24.3% and 13% of patients respectively. VN protrusion was found in 27% of patients. Fuji et al., [12] observed 8% dehiscent ICA, 4% dehiscent ON. Kennedy et al., [17] found dehiscence of ICA in 25% of patients. Birsen et al., [11] found protrusion and dehiscence of ICA in 30.3% and 3.5% of patients. They noticed protrusion of MN in 24.3%. Sirikci et al., [18] observed protrusion ICA in 26.1% of patients and dehiscence of the artery in 23%.

Significant difference in our findings as compared to other studies was mostly due to regional or racial difference.

## CONCLUSION

SS is surrounded by important neurovascular structure. Various types of pneumatization can be seen and if pneumatization spreads beyond body of the sphenoid bone it forms recesses. Due to this, SS is in close relation with MN, ON, VN & ICA. Newer techniques were helpful for the safety of the patient during intra-operative and post-operative period. Now, intra-operative fluoroscopic imaging or intra-operative navigational devices are used to confirm surgical landmarks making these techniques very safe.

## REFERENCES

- [1] Chougule MS, Dixit D. A cross-sectional study of sphenoid sinus through gross and endoscopic dissection in North Karnataka, India. *Journal of Clinical and Diagnostic Research*. 2014;8(4):AC01-05.
- [2] Gurevitch O, Slavin S, Feldman AG. Conversion of red bone marrow into yellow cause and mechanisms. *Med Hypotheses*. 2007;69:531-36.
- [3] Hewaidi GH and Omami GM. Anatomic variation of sphenoid sinus and related structures in Libyan population: CT scan study. *Libyan Journal of Medicine*. 2008;49:01-08.
- [4] Aoki S, Dillon WP, Barkovich AJ, Norman D. Marrow conversion before pneumatization of the sphenoid sinus: assessment with MR imaging. *Radiology*. 1989;172:373-75.
- [5] Delano MC, Fun FY, Zinrich SJ. Relationship of optic nerve to the posterior paranasal sinuses: a CT anatomic study. *Am J Neuroradiol*. 1996;17:669-75.
- [6] Szolar D, Preidler K, Ranner G, Braun H, Kern R, Wolf G et al. Magnetic resonance assessment of age-related development of the sphenoid sinus. *Br J Radiol*. 1994;67:431-35.
- [7] Yonetsu K, Watanabe M, Nakamura T. Age-related expansion and reduction in aeration of the sphenoid sinus: volume assessment by helical CT scanning. *AJNR Am J Neuroradiol*. 2000;21:179-82.
- [8] Earwaker J. Anatomic variants in sinonasal CT. *Radiographics*. 1993;13:381-415.
- [9] Taccone A, Oddone M, Occhi M, Dell'Acqua A, Ciccone MA. MRI "road-map" of normal age-related bone marrow. I. Cranial bone and spine. *Pediatr Radiol*. 1995; 25: 588-95.
- [10] Jalali E, Tadinada A. Arrested pneumatization of the sphenoid sinus mimicking intraosseous lesions of the skull base. *Imaging Science in Dentistry*. 2015;45: 67-72.
- [11] Birsen U, Gulsah B, Yasemin K. Risky anatomic variations of sphenoid sinus for surgery. *Surg Radil Anat*. 2006;28:195-201.
- [12] Fuji K, Chambers A, Rhoton J. Neurosurgical relationships of the sphenoid sinus: a microsurgical study. *J Neurosurgery*. 1979;50:31-39.
- [13] Bolger WE, Butzin CA, Parsons DS. Paranasal sinus bony anatomic variations and mucosal abnormalities: CT analysis for endoscopic sinus surgery. *Laryngoscope*. 1991;101:56-64.
- [14] Elwany S, Yacout YM, Talaat M, El-Nahass M, Gunied A. Surgical Anatomy of the Sphenoid Sinus. *The Journal of Laryngology and Otology*. 1983;97:227-41.
- [15] Sethi DS, Pillay PK. Endoscopic management of lesions of the sella turcica. *The Journal of Laryngology and Otology*. 1995;109: 956-62.
- [16] Hamid O, El Fiky L, Hassan O, Kotb A and El Fiky S. Anatomic variations of the sphenoid sinus and their impact on trans-sphenoid pituitary surgery. *Skull Base*. 2008;18(1):09-15.
- [17] Kennedy D, Zinrich H, Hassab M. The internal carotid artery as it relates to endoscopic spheno-ethmoidectomy. *Am J Rhinology*. 1990;4:7-12.
- [18] Sirikci A, Bayazit YA, Bayram M. Variations of sphenoid sinus and related structures. *Eur Radiology*. 2000;10:844-48.

### AUTHOR(S):

1. Dr. Manisha S. Chougule
2. Dr. Preetam B. Patil

### PARTICULARS OF CONTRIBUTORS:

1. Assistant Professor, Department of Anatomy, SDM College of Medical Sciences and Hospital, Dharwad, Karnataka, India.
2. Associate Professor, Department of Radiology, SDM College of Medical Sciences and Hospital, Dharwad, Karnataka, India.

### NAME, ADDRESS, E-MAIL ID OF THE CORRESPONDING AUTHOR:

Dr. Manisha S. Chougule,  
282, Agarkar Road, Tilakwadi, Belgaum,  
Karnataka-590006, India.  
E-mail: drmanishasc23@gmail.com

### FINANCIAL OR OTHER COMPETING INTERESTS:

None.

Date of Publishing: Jul 01, 2016