

Hydatid Cyst of Lung- Common Disease, Many Signs, All in One!

RAGHAVENDRA BHAT, GITA RAGHAVENDRA BHAT, NITA RAGHAVENDRA BHAT, MEENAKSHI SHETTY, PARUL KODAN

Keywords: Air Crescent-sign, Cumbo-sign, Sunrise sign, X-ray

Hydatid cyst of lung is a common disease which can be diagnosed by serology or radiological signs [1-4]. Here we present a X-ray of the patient which helped us to clinch the diagnosis of hydatid cyst with its characteristic signs. The diagnosis was later confirmed by serological testing and successfully treated with symptomatic treatment and anti-helminthics. The black and white picture of X-ray is an easily available imaging modality revealed so many signs- all in one image, that it prompted us to share the beautiful picture. A 64 years old patient presented with history of abdominal discomfort and dysphagia for 2 months and cough with expectoration, decreased appetite and generalized malaise and weight loss for 1 month duration. There was no history of fever. On examination, he was moderately built and poorly nourished, afebrile; had no pallor, icterus, cyanosis, clubbing, lymphadenopathy or edema. He had generalized ichthyosis. Vitals were stable. Chest X-ray of the patient showed many radiological features of hydatid cyst of the lung clearly seen in a single image [Table/Fig-1]. Air Crescent- sign, Rising sun -sign, Cumbo-sign and Water lily- sign are some characteristics of hydatid cyst which can be visualized on a X-ray film.

ELISA test for IgG antibodies against echinococcal antigen was done and was positive (=1.2)

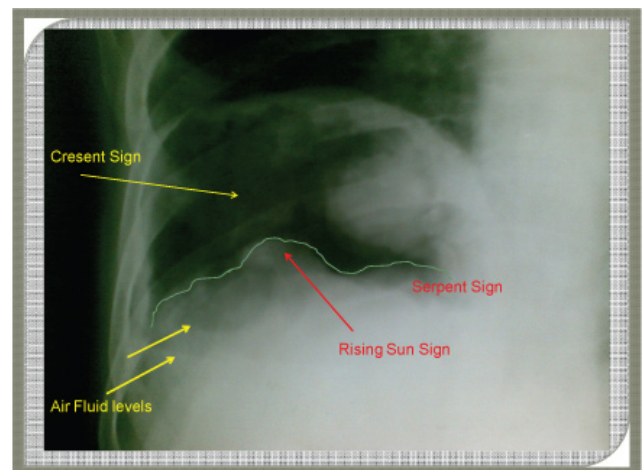
(Negative-<0.9, Equivocal-0.9-1.1, Positive >1.1).

He was started on parenteral antibiotics (Inj. Ciprofloxacin and Inj. Metronidazole) and oral Albendazole 400 mg twice daily. After 2 weeks, the antibiotics were stopped and oral Albendazole was continued. The patient refused surgery. On 1 month follow-up patient showed a dramatic clinical improvement and radiological improvement.

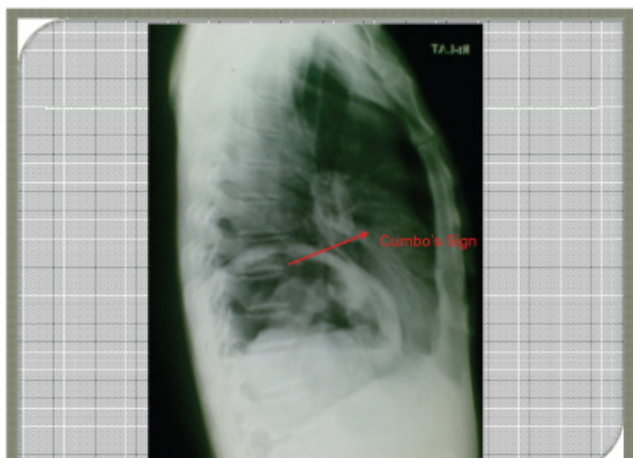
Hydatid cyst is caused by *Echinococcus granulosus*. The larvae can settle in the lungs, liver or brain, and cause slow-growing cysts. In the lung, the cyst may cause inflammation, chest pain, coughing up of blood, wheezing and other symptoms. Radiology can be a useful tool for lung lesions like cyst. Lung cyst on a X-ray can be due to various etiologies

like congenital like bronchogenic cyst, infective or malignant. Hydatid cyst may present as single or multiple cystic lesion on imaging. The cyst may appear as a circumscribed dense homogenous opacity. The typical radiological sign commonly described is a water-lily sign seen in a cyst associated with communication with small bronchioles and with a detached laminated membrane [4,5]. Many other typical signs in the chest X-ray or a CT-scan are due to rupture of the cyst, expulsion of the contents and the entry of air into the cyst between its various layers. Some of these signs which can all be seen in our image are:

1. Air Crescent Sign/Meniscus Sign/Double Arch Sign/Moon Sign: The crescent of air around the periphery of cyst between pericyst and exocyst.
2. Air-Fluid Level: rupture of all cyst walls resulting in direct communication with the endocyst.
3. Cumbo-Sign: Air fluid level inside endocyst + air between pericyst and endocyst with "onion peel" appearance [Table/Fig-2].
4. Consolidation: Spread of cyst fluid to surrounding lung parenchyma.



[Table/Fig-1]: Chest X-Ray PA view showing ruptured hydatid cyst.



[Table/Fig-2]: Chest X-Ray lateral view of ruptured hydatid cyst depicting Combo's-sign.

5. Water Lily-Sign/Sign of Camelotte: Completely collapsed crumpled cyst membrane floating in cyst fluid after cyst rupture into bronchial tree.

6. Serpent-Sign: Collapsed membrane inside the cyst outlined by air (after expectoration of cyst contents).
7. Mass within the cavity: Crumpled membranes fall to the most dependent portion of the cavity after complete expectoration of cyst fluid.
8. Water Lily-Sign+ hydropneumothorax/pneumothorax (may be under tension): cyst rupture into pleural space.

REFERENCES

- [1] Babba H, Messedi A, Masmoudi S et al. Diagnosis of human hydatidosis: comparison between imagery and six serologic techniques. *Am J Trop Med Hyg.* 1994; 50:64-68.
- [2] Ramos G, Orduña A, García-Yuste M. Hydatid cyst of the lung: diagnosis and treatment. *World J Surg.* 2001;25(1):46-57.
- [3] Eckert J, Deplazes P. Biological, epidemiological, and clinical aspects of echinococcosis, a zoonosis of increasing concern. *Clin Microbiol Rev.* 2004; 17:107-35.
- [4] Beggs I. The radiology of hydatid disease. *AJR Am J Roentgenol.* 1985;145:639-48.
- [5] Ghallab NH, Alsabahi AA. Giant viable hydatid cyst of the lung: a case report. *Journal of Medical Case Reports.* 2008;2:359.

AUTHOR(S):

1. Dr. Raghavendra Bhat
2. Dr. Gita Raghavendra Bhat
3. Dr. Nita Raghavendra Bhat
4. Dr. Meenakshi Shetty
5. Dr. Parul Kodan

PARTICULARS OF CONTRIBUTORS:

1. Professor, Department of Internal Medicine, RAK Medical and Health Sciences University, UAE.
2. Post Graduate, Department of Medical Oncology, Kidwai Memorial Institute of Oncology, Mangalore, Karnataka, India.
3. Post Graduate, Department of Ophthalmology, KS Hegde Medical Academy, NITTE University, Mangalore, Karnataka, India.

4. Associate Professor, Department of Medicine, KMC, Mangalore, Karnataka, India.
5. Post Graduate, Student, Department of Medicine, KMC, Mangalore, Karnataka, India.

NAME, ADDRESS, E-MAIL ID OF THE CORRESPONDING AUTHOR:

Dr. Raghavendra Bhat,
Professor, Department of Internal Medicine,
RAK Medical and Health Sciences University,
Post Box No. 11172, Ras al Khaimah-UAE.
E-mail: nita2005bhat@yahoo.co.in

FINANCIAL OR OTHER COMPETING INTERESTS:

None.

Date of Publishing: Jul 01, 2016