

Tubercular Spondylitis: Prospective Comparative Imaging Analysis on Conventional Radiograph and MRI

GAURAV SHARMA, RITA GHODE

ABSTRACT

Introduction: Tuberculosis remains a major health hazard with a rebound insurgency with increasing incidence of HIV. Skeletal involvement occurs in 1-3% of patients with tuberculosis and spine accounts for almost 50% cases of skeletal tuberculosis. Imaging plays an important role in managing spinal tuberculosis by making a prompt diagnosis so as to prevent irreversible neurological deficit and spinal deformity.

During this era of cross sectional imaging, plain radiography can still provides important information necessary for diagnosis, however disease may not be apparent for upto 8 weeks and or involvement of 30-50% of the vertebra.

MRI remains the standard imaging modality with its high contrast resolution, multiplanar capacity and ease of assessment of spinal cord and neural element.

Aim: To compare and correlate the imaging findings of tubercular spondylitis on plain radiograph and MRI.

Materials and Methods: This was prospective diagnostic study carried out over 1 year of period in the department of radio diagnosis, JR Tantia Charitable Trust and Rural Hospital, comprising a sample size of 32 patients. The various spinal imaging findings were prospectively evaluated and compared on plain radiograph and MRI.

Results: A definite level of lesion could be localised in 27(84.3%) on radiograph while MRI could localized the disease in all 32(100%) patients. Thoracic spine was the most common site on both plain radiograph and MRI. Paradiskal with posterior location 15(46.8%) was commonest pattern of vertebral involvement on MRI while plain radiograph could localized mostly paradiskal lesion 24(88.8%). Both modalities could detect vertebral body destruction, reduced disc height in equal number of patients (19). Skip lesion was seen in 4(12.5%) cases on MRI and in 2 (7.4%) on plain radiograph. Paravertebral soft tissue mass was evident in 26(81.2%) patients on MRI and in 15(55.5%) on plain radiograph. The two modalities showed a moderate agreement (k value: 0.685) amongst them for detection of skip lesion while they showed poor agreement (k value: 0.09) for detection of paravertebral soft tissue mass. The two modalities showed a perfect agreement (k value:1) for evaluation of reduced disc height.

Conclusion: Plain radiograph does reveal the important diagnostic imaging findings and serves as the initial first line imaging modality due to its cost effectiveness and availability. However, MRI is more sensitive, specific and accurate than plain radiography in the diagnosis of spinal tuberculosis.

Keywords: Extrapulmonary tuberculosis, Imaging modality, Pott's spine

INTRODUCTION

Of all the manifestation of tuberculosis, pulmonary tuberculosis gets the justifiable maximum attention since, it is the most frequent of all manifestation and is the only manifestation which is infectious. Even though extra pulmonary tuberculosis is non infectious, it does lead to considerable suffering, disability and certainly merits more attention.

The history of tuberculosis is long, fascinating and is probably as old as mankind with historic spectrum starting from Hebrews to Robert Koch. With the discovery of tubercle bacillus in 1882 by Robert Koch, new vistas opened for eradicating a scourge

that plagued humanity in all its recorded history.

Tubercular infection caused by *Mycobacterium tuberculosis*, remains a major public health hazard and the skeletal involvement occurs in approximately 1-3% of patients, with spine as commonest osseous site in 50% cases. In developing countries like India in which poverty, malnutrition, presence of drug resistant strains combined with increasing incidence of HIV infection aiding in the disease spread and reactivation of dormant tuberculosis [1].

A multidisciplinary approach to tuberculous spondylitis is essential for prompt assessment of the disease to ensure

timely management so as to prevent irreversible neurologic sequelae and spinal deformity. Due to high disease burden in countries like India, tissue biopsy is not usually undertaken and the diagnosis can be confidently made on imaging features and using therapeutic trail of anti-tuberculous treatment.

Conventional radiograph are the best initial diagnostic test especially in rural places where advanced cross sectional imaging modalities are not readily available. However, the findings on plain radiograph is nonspecific and the disease may not be apparent for up to 8 weeks and more than 50% of the vertebra has to be destroyed before a lesion can be evident [2].

MRI with its high contrast resolution, multiplanar capacity, ability to detect early marrow infiltration and ease of assessment of extradural disease has become the established optimal imaging technique.

The present study was carried out aiming to compare the various imaging features on both MRI and plain radiograph and to correlate these findings with final confirmed diagnosis.

MATERIALS AND METHODS

This was a prospective, diagnostic study carried out in the Department of Radiodiagnosis, J.R Tantia Charitable Trust and Rural Hospital in a District place of Rajasthan, India between March 2012 to April 2013.

These are the patients referred from clinicians with high suspicion of tubercular infection of spine based on symptoms, signs and laboratory findings. All patients underwent plain radiograph and MRI of symptomatic spinal column with screening of whole spine. Final sample size of 32 patients was selected having atleast one of imaging features suspicious for tuberculosis on either modality. Patients consent was taken both before MRI scan and before planning for biopsy/FNAC.

Inclusion Criteria: All patients referred by the clinicians for MRI examination with high clinical suspicion of spinal tuberculosis based on symptoms, signs and laboratory parameters.

Exclusion Criteria: Patient with metallic implants, pacemakers, metallic aneurysm clips and patient with underlying diagnosed spinal neoplasm are excluded from the study.

Plain radiograph of spine in standard anteroposterior and lateral views was taken on 500mA Allengers radiographic machine followed by evaluation on Hitachi 0.7T MR unit after consent. Plain T1 weighted, T2 weighted and Short tau inversion recovery (STIR) sequences in routine axial, sagittal and coronal planes were acquired. In addition to routine sequence, whole spine T2 weighted sagittal screening was also done.

Both imaging modalities were used to evaluate the spine in terms of:

- i. Level of lesion (cervical, thoracic, lumbosacral, cervicothoracic, thoracolumbar)
- ii. Number and pattern of vertebral body involvement (Solitary; Multiple; paradiskal, anterior, central, posterior)
- iii. Curvature of spine
- iv. Presence of skip lesion
- v. Intervertebral disc involvement
- vi. Presence of paravertebral soft tissue mass

Confirmation of diagnosis was done either by:

- i. Assessment of response to Anti-tuberculous therapy at 2 months follow-up.
- ii. Guided biopsy and positive tubercular serology.

The various imaging features was recorded on a pre-designed proforma and were correlated with final confirmed diagnosis in terms of their sensitivity, specificity, positive predictive and kappa agreement value for descriptive statistical analysis using Base SAS(R) 9.2 software.

The p value was not evaluated. We considered the degree of agreement between radiograph and MRI for a given imaging parameter.

RESULTS

Out of the total 32 cases in this study, a definite level of the lesion could be localized in 27(84.3%) on radiograph while MRI could localized the disease in all patients (100%).

Maximum numbers of cases were seen in Thoracic spine on both plain radiography (n=10, 31.2%) and MRI (n=13, 40.6%) [Table/Fig-1]. The most common pattern of vertebral involvement was paradiskal (n=24, 88.8%) on radiography and paradiskal with posterior location (n=15, 46.8%) on MRI, conferring that MRI is more sensitive in evaluating posterior location disease [Table/Fig-2].

Out of the 32 cases, 11(34.3%) patients showed loss of normal curvature of spine on both plain radiograph and MRI. 7(21.8%) patients had kyphotic deformity and 4(12.5%) had scoliosis on both modalities.

Pattern of vertebral involvement, presence of vertebral

Level of Lesion	Imaging modality	
	Radiograph	MRI
Cervical	4(12.5%)	4 (12.5%)
Thoracic	10(31.2%)	13(40.6%)
Lumbosacral	8(25%)	9 (28.1%)
Cervico-thoracic	2(6.3%)	2 (6.3%)
Thoracolumbar	3 (9.4%)	4(12.5%)
No definite level	5(15.6%)	—
Total	32	32

[Table/Fig-1]: Correlation of level of lesion by radiographic and MRI findings.

Pattern of Vertebral Involvement	Modality	
	Radiograph	MRI
Paradiskal	24 (88.8%)	11 (35.4%)
Anterior	0	1 (3.2%)
Central	0	2 (6.45%)
Posterior	0	1 (3.2%)
Anterior + Posterior	0	1 (3.2%)
Paradiskal + Posterior	3(11.2%)	15 (48.3%)
Total	27	31

[Table/Fig-2]: Correlation of pattern of vertebral involvement by Radiographic and MRI findings.

* One patient had isolated posterior epidural abscess without any vertebral involvement accounting for n=31.

destruction, end plate erosion, evaluation of disc height, presence of skip lesion and paravertebral mass are shown in [Table/Fig-3].

Vertebral body destruction was present in 19 cases on both plain radiograph and MRI thus showed a perfect agreement (k value-1, 95% confidence interval: 0.66-1) amongst them for detection of vertebral body destruction.

The statistical correlation of findings of skip lesion, reduced disc height, paravertebral soft tissue mass on radiograph with MRI is depicted in [Table/Fig-4].

Imaging Findings	Plain Radiograph (n=27)	MRI (n= 31)*
Solitary Vertebral Involvement	5(18.6%)	3(9.6%)
Multiple Vertebral Involvement	22(81.4%)	28(90.3%)
Vertebral Body Destruction	19(70.3%)	19(61.2%)
Vertebral End Plate Erosion	19(70.3%)	26(83.8%)
Skip Lesion	2(7.4%)	4(12.9%)
Reduced Disc Height	19(70.3%)	19(59.3%)
Para Vertebral Soft tissue Mass	15(55.6%)	26(81.3%)

[Table/Fig-3]: Major imaging findings on radiograph and MRI

*One patient had isolated posterior epidural abscess without any vertebral involvement accounting for n=31.

	Sensitivity (95% CI)	Specificity (95% CI)	PPV	Diagnostic Accuracy	Kappa value
Skip Lesion	50% (0.106-0.50)	100% (0.94-1)	100%	93% (0.83-0.93)	0.685
Reduced disc Height	100% (0.70-1)	100% (0.87-1)	100%	93% (0.82-1)	1
Para-vertebral mass	58% (0.54-0.58)	100% (0.05-1)	100%	59% (0.53-0.59)	0.09

[Table/Fig-4]: Correlation of findings of skip lesion, reduced disc height, paravertebral soft tissue mass on radiograph with MRI, the plain radiography modality provides:

*CI: confidence interval; PPV: positive predictive value

The two modalities showed a moderate agreement (k value-0.685) amongst them for detection of skip lesion while both showed a perfect agreement (k value-1) for evaluation of reduced disc height.

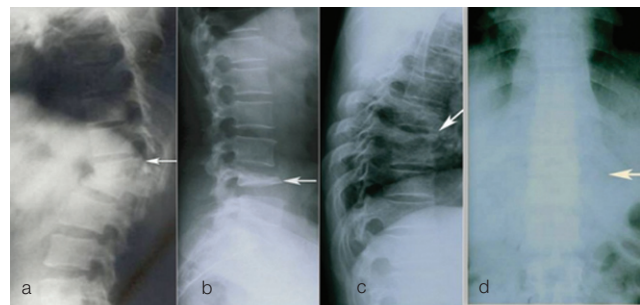
The two modalities showed a poor agreement (k value-0.09) amongst them for detection of paravertebral soft tissue mass.

Biopsy was done in 6(18.75%) patients out of total 32 cases; a positive result indicative of caseating granulomatous lesion was present in 5(83%) patients. Two patients were confirmed to have metastasis and pyogenic osteitis on follow-up and biopsy.

Out of the 32 cases, 27(84.3%) patients were suspicious of tubercular spondylitis on plain radiography. The radiographic findings considered were vertebral end plate erosion, decreased disc height, vertebral destruction and presence of paravertebral soft tissue mass [Table/Fig-5]. Out of the 30 confirmed cases of spinal tuberculosis, there was a suspicion of tubercular spondylitis by radiography in 25 cases only; however in 5 cases radiographic findings were absent.

In this study all 32 cases were diagnosed as tubercular spondylitis by MRI. Out of this, 30 (93.7%) cases were confirmed finally for spinal tuberculosis based response to ATT on follow up and biopsy. However 2 cases which were diagnosed by MRI were found to be negative for tuberculosis, one on biopsy (neoplastic), another with no response on follow up to ATT (pyogenic).

The diagnostic accuracy of MRI and plain radiography in the diagnosis of spinal tuberculosis is shown in [Table/Fig-6].



[Table/Fig-5]: Radiographic Changes in Spinal Tuberculosis. Anterior Wedging with kyphosis (a); Vertebral Body Destruction (b); Vertebral end plate erosions (c); and bilateral Paravertebral soft tissue mass (d).

Imaging Modality	No. of Patients		Sensitivity	Specificity	Accuracy
	Present	Absent			
Radiography	25	7	83.3%	0%	78%
MRI	30	2	100.0%	0%	94%

[Table/Fig-6]: Diagnostic accuracy of MRI and plain radiography in the diagnosis of spinal tuberculosis.

*In this study only those patients with high clinical suspicion of tubercular spine were included therefore there were no true negative cases, hence the absolute specificity

DISCUSSION

The principal difficulty in the management of spinal tuberculosis is making the initial diagnosis. In countries like India, the diagnosis is traditionally made on clinical and radiological grounds with histopathological confirmation or needle biopsy not always necessary [3].

In this present prospective study, we have evaluated 32 patients by plain radiograph and MRI spine for identifying main imaging features of spinal tuberculosis, comparing these findings together and with final diagnosis.

A definite level of the lesion in the spine could be localized in all 32 patients. Maximum number of cases had involvement in the thoracic spine on both modalities. MRI (32/32, 100%) had clear advantage over plain radiography (27/32, 84.3%) in localization of lesion site. The findings of thoracic spine as the most common site were also found by Yusuf et al., and B Dass et al., [4, 5].

MRI being able to pick up initial vertebral-end plate edema and with its multiplanar high contrast soft tissue-bone resolution helps in localizing the disease better in its early stages, whereas, radiograph requires a disease process to affects at least 30% of the bone to be able to recognized.

The source of spinal infection is usually through hematogeneous route. Within the vertebral body, the anterior-inferior part adjacent to end plate is the intial site of infection due to its rich vascularity. With progression infection spread within the vertebra, disc, endplate or manifests as non-contiguous disease through subligamentous spread.

Tubercular spondylitis presents with four different imaging pattern- Paradiskal, anterior, central and posterior lesion [6].

Paradiskal with posterior location (n=15, 46.8%) was the commonest pattern of vertebral involvement on MRI followed by paradiskal location (n=11, 35.4%). MRI was definitely better in localizing various patterns than plain radiograph, which could localize mostly paradiskal (n=24, 88.8%) lesions. Antonio G et al., in their literature review while evaluating spinal MRI explorations, found paradiskal as most frequent pattern of vertebral involvement (80%) and emphasised the high sensitivity of MRI in determining the disease extent [7].

Recognition of posterior element involvement is important for surgery and also these cases are more likely to have neurological symptoms. Similar to study of Tariq Sinan [8], in present study also MRI had the advantage of localizing posterior element involvement efficiently in 17 (54%) patients [Table/Fig-7a-d]. This included 15 patients with posterior and paradiskal location, 1(3.2%) patients with isolated posterior and 1 patient with posterior and anterior involvement.

Again MRI has definitive advantage in terms of evaluation of posterior element, neural arch with imaging possible in all three

planes. The use of simple STIR sequence allows identification of abnormal hyperintense edema signal within the posterior element early and easily.

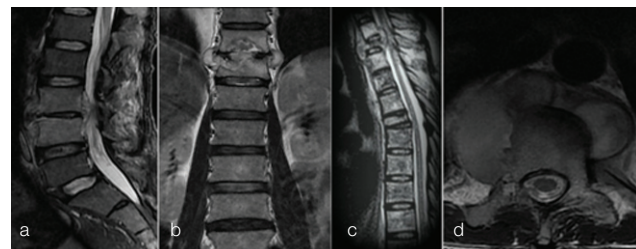
Vertebral body destruction in patient of spinal tuberculosis signifies spondylitis as a predominant presentation. In this study both MRI and radiograph could detect vertebral body destruction in equal number of cases (n=19), similar to study findings done by Ansari S et al., [9].

BMGD Yasaratne et al., in their descriptive case series of 32 patients found that the earliest sign of spondylitis was end plate involvement in form of loss of end plate definition, abnormal signal intensity, end plate edema, sclerosis and or erosive changes. They reported 72% incidence of end plate involvement [10].

Spinal Tuberculosis in its classical form is characterized by two contiguous vertebral diseases; [Table/Fig-7a,7b] however non contiguous involvement in the form of skip lesion signifies spread of infection along the anterior longitudinal ligament and the adjacent soft tissue. In this study Skip lesion was seen in 4 (12.5%) on MRI and in 2 (7.4%) patients on radiograph with clear advantage of MRI [Table/Fig-7c]. Polley P et al., identified 16 cases(16.3%) of non contiguous spinal tuberculosis from a single series of 98 patients concluding that if available a quick survey of whole spine on sagittal MRI plane is extremely useful to identify skip lesion [11].

Kaila Rajiv et al., retrospectively reviewed whole spine MRI of all cases over 3 years to identify the incidence of multiple level non-contiguous vertebral tuberculosis and found it to be 71.4% and concluded that this non contiguous vertebral involvement is more frequent than previously thought (1.1 to 16%) [12].

While plain radiography requires multiple exposures to screen a whole spine, on MRI a quick T2 weighted sagittal screening of whole spine helps in identifying skip lesion without any added radiation exposure.



[Table/Fig-7A-D]: MRI Pattern in Spinal Tuberculosis. Sagittal STIR with contiguous two vertebral lesions, reduced disc height, prevertebral and anterior epidural mass (a); Coronal T2 weighted image showing end plate destruction, Osteitis with disc space involvement and paravertebral masses (b); Sagittal T2 weighted image with Non Contiguous Skip Lesion (c); T2 weighted axial image showing involvement of posterior element (d).

Due to lack of proteolytic enzymes and primary avascular nature of disc, disc involvement is relatively late. However, mild reduction of disc height in early stage can be seen due to herniation of disc materials into adjacent destroyed vertebral body [10]. The high incidence of disc involvement in developing countries is usually due to late presentation.

In the present study, intervertebral disc involvement was seen as reduced disc height in 19 patients on both MRI and plain Radiograph with features of diskitis on MRI. Similar observations were made by Ansari S et al., were disc involvement and signal changes were seen in 73.3% cases on plain radiograph and 83.3% on MRI [9].

Paravertebral soft tissue mass is commonly seen in spinal tuberculosis and multiplanar imaging capability of MRI helps in better delineation of the disease extent. In the present study MRI could detect paravertebral component in 26(81.2%) patients while radiograph could detect it in 15(55.5%) patients only [Table/Fig-8a-c]. Chang Ming-Chau et al., and Gehlot PS et al., emphasized the advantage of MRI were MRI could detect paravertebral component in 82% and 80% patients respectively [13,14].

MRI provides exact localization of intravertebral and paravertebral abscesses. The use of contrast imaging is sensitive in differentiating granulation tissue from cold abscess.

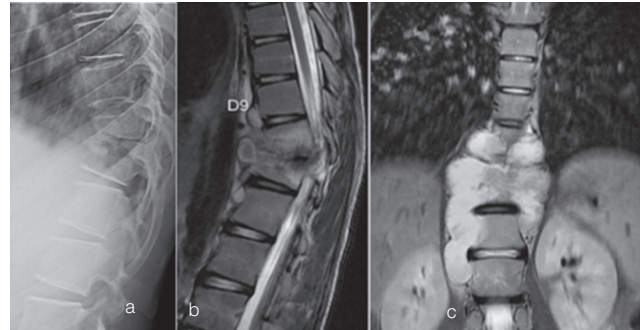
Danchavijitr Nasuda et al., studied MR images of 65 patients and divided them into two groups- 32 patients with tuberculous spondylitis and 34 patients with other spinal disease. End plate disruption, paravertebral soft tissue and high signal intensity of disc on T2 weighted were the three most useful MR features with high sensitivity and specificity of more than 80%, with overall sensitivity and specificity of MRI for diagnosis of spinal tuberculosis to be 100% and 88.2% respectively [15].

While MRI is a more sensitive technique, in an appropriate clinical setting with high index of clinical suspicion, plain radiograph can provides enough clues for diagnosis and management of spinal tuberculosis [Table/Fig-8a-c]. Indistinct or end plate destruction, reduced disc height, vertebral destruction, paravertebral abscess, soft tissue abscess with calcification are the classic radiographic manifestation of spinal tuberculosis.

Out of the total 32 cases in this study, 27(84.3%) patients had imaging findings suspicious of tubercular spondylitis on plain radiograph.

Pertuiset E et al., in their study over 5 years had found 103 confirmed cases of spinal tuberculosis, out of which 44 patients were investigated by MRI. In these 44 patients, 38 (86.3%) patients had finding on plain radiograph with 6 negative cases [16].

Polley P et al., while reviewing a single series of 98 patients



[Table/Fig-8]: Lateral Radiograph with destruction of D10,D11 with reduced disc height (a); T2 weighted sagittal (b) and Coronal (c) image showing anterior destruction of D10, altered marrow signal over D10,D11 with disc involvement and lobulated paraspinal masses.

on MRI and plain radiography, identified 16(16.3%) cases of non contiguous spinal tuberculosis. 15 of these 16 cases had evidence of skip lesions on the plain films, highlighting the importance of simple radiography [11].

In poor countries where non availability of a much costlier MRI is an issue, plain radiography still remain the most important and basic of spinal imaging in majority of cases for the diagnosis of spinal tuberculosis [17].

The limitation of plain radiography is that the disease should involved 30-50% of the bony element to be appreciated on radiograph. In rural setup the tubercular cases often present late due to lack of awareness and medical facility. In these cases suspicious findings on plain radiograph can be picked up and further evaluation by MRI can be performed at higher centre.

In the present study confirmed final diagnosis was made in 30(93.7%) patients, based on their imaging findings and a positive clinical response to ATT at 2 moths follow-up. Biopsy or histopathology was done in only 6(19%).

Yasaratne et al., asserted that a proper clinical diagnosis with biochemical markers like raised ESR when correlated with imaging features of end plate-paraspinal disease on MRI provides with a sensitivity of 81.2% for the diagnosis of spinal tuberculosis even in the absence of histopathological evidence in majority of cases. They also concluded that clinico-radiological based diagnosis with ATT trial is an effective alternative course for management of spinal tuberculosis [10].

S Bhojraj and A Nene in 2002 stated that in countries like India where tuberculosis is endemic, histopathological confirmation is not usually undertaken due to large case load and the confidence of making the diagnosis clinicrodiologically. A therapeutic trail of anti-tubercular treatment is a practical alternative to taking a biopsy [3].

LIMITATIONS

The major limitations was a small sample size, wherefrom significant conclusions could be drawn but they cannot be said to be absolute decisive. Secondly as the study was done in rural setup, contrast study was not performed due to cost issue which could have provided better characterisation of enhancement pattern of osteal/paravertebral abscess.

CONCLUSION

The diagnosis of spinal tuberculosis remains a challenge and requires a high index of suspicion. Plain radiograph does reveals the important diagnostic imaging findings, providing the initial relevant information and serves as the initial first line imaging modality due to its cost effectiveness and availability especially in rural based country like India. However, MRI is more sensitive, specific and accurate than plain radiography in the diagnosis of spinal tuberculosis with added advantages in terms of evaluation of disease extent, spinal cord status and involvement of posterior element.

REFERENCES

- [1] Moore SL, Rafi M. Imaging of musculoskeletal and spinal tuberculosis. *Radiol Clin North Am.* 2001;39(2):329-42.
- [2] Mehta JS, Bhojraj SY. Tuberculosis of the thoracic spine: A classification based on the selection of surgical strategies. *J Bone Joint Surg Br.* 2001;83(6):859-63.
- [3] Bhojraj S, Nene A. Lumbar and lumbosacral tuberculous spondylodiscitis in adults. Redefining the indications for surgery. *J Bone Joint Surg Br.* 2002;84(4):530-34.
- [4] Yusof MI, Hassan E, Rahmat N, Yunus R. Spinal tuberculosis: the association between pedicle involvement and anterior column damage and kyphotic deformity. *Spine.* 2009;34(7):713-17.
- [5] Dass B, Puet TA, Watanakunakorn C. Tuberculosis of the spine presenting as compression fractures. *Spinal Cord.* 2002;40(11):604-08.
- [6] Moorthy S, Prabhu NK. Spectrum of MR imaging findings in spinal tuberculosis. *AJR.* 2002;179(4):979-83.
- [7] Rivas-Garcia A, Sarria-Estrada S, Torrents-Odin C et al. Imaging findings of Pott's disease. *Eur Spine J.* 2013;22(S4):567-78.
- [8] Sinan T, Al-khawari, Ismail M et al. Spinal tuberculosis: CT and MRI features. *Ann Saudi Med.* 2004;24(6):437-41.
- [9] Ansari S, Rauniyar RK, Dhungel K, Sah PL et al. MR evaluation of spinal tuberculosis. *Al Ameen J Med Sci.* 2003;6(3):219-25.
- [10] Yasaratne BMGD, Wijesinghe SNR, Madegedara RMD. Spinal tuberculosis: A study of the disease pattern, diagnosis and outcome of medical management in Sri Lanka. *Indian J Tuberc.* 2013;60:208-16.
- [11] Polly P, Dunn R. Non-contiguous spinal tuberculosis: incidence and management. *Eur Spine J.* 2009;18(8):1096-101.
- [12] Kaila R, Malhi AM, Mahmood B, Saifuddin A. The incidence of multiple level non-contiguous vertebral tuberculosis detected using whole spine MRI. *J Spinal Disord Tech.* 2007;20(1):78-81.
- [13] Chang MC, Wu HT, Lee CH, Liu CL et al. Tuberculous spondylitis and pyogenic spondylitis: comparative magnetic resonance imaging feature. *Spine.* 2006;31(7):782-88.
- [14] Gehlot PS, Chaturvedi S, Kashyap R, Singh V. Pott's spine: retrospective analysis of MRI scan of 70 cases. *J Clin Diagn Res.* 2012;6(4):1534-38.
- [15] Danchaivijitr N, Temram S, Thepmongkhon K. Diagnostic accuracy of MR imaging in tuberculous spondylitis. *J Med Assoc Thai.* 2007;90(8):1581-89.
- [16] Pertuiset E, Beaudreuil J, Horowitzky A et al. Spinal tuberculosis in adults. A study of 103 cases in a developed country. *Medicine (Baltimore).* 1999;78(5):309-20.
- [17] Garg RK, Somvanshi DS. Spinal tuberculosis: a review. *J spinal cord Med.* 2011;34(5):440-54.

AUTHOR(S):

1. Dr. Gaurav Sharma
2. Dr. Rita Ghode

PARTICULARS OF CONTRIBUTORS:

1. Assistant Professor, Department of Radio-diagnosis TIFAC-CORE in Intervention Radiology, DMIMS JNMC Sawangi, Wardha, India.
2. Senior Resident, Department of Radio-diagnosis TIFAC-CORE in Intervention Radiology, DMIMS JNMC Sawangi, Wardha, India.

NAME, ADDRESS, E-MAIL ID OF THE CORRESPONDING AUTHOR:

Dr. Gaurav Sharma,
Flat No. 101, Gajanan Shivani Apartment, Tiwari Layout,
Sawangi Bypass, Sawangi, Wardha 442001. Maharashtra,
India.
E-mail: drgsharma78@gmail.com

FINANCIAL OR OTHER COMPETING INTERESTS:

None.

Date of Publishing: Jul 01, 2016