

# Spontaneous Choledochoduodenal Fistula Due to Chronic Duodenal Ulcer—A Case Report

PALANIAPPAN.M, N.S.KANNAN, JAYA KARTHIK.Y, KARTHIKESH.S

## ABSTRACT

Choledochoduodenal fistulas account for only 1-25% of biliary enteric fistulas cases. Only 5-6% of biliary enteric fistula cases are spontaneous associated with duodenal peptic ulcers and they appear with the signs and symptoms of the underlying peptic ulcer disease. The first sign of this abnormal biliary-enteric communication may be the presence of air in the biliary tree as seen on plain X-ray, ultra-

sound or CT of the abdomen. Treatment should be directed towards peptic ulcer disease relief rather than correction of choledochoduodenal fistula. Here we present a patient with chronic duodenal ulcer and spontaneous choledochoduodenal fistula, gastric outlet obstruction and multiple jejunal diverticulae treated with truncal vagotomy and posterior gastroenterostomy.

**Keywords:** Biliary enteric fistula, Gastric outlet obstruction, Jejunal diverticulae, Pneumobilia

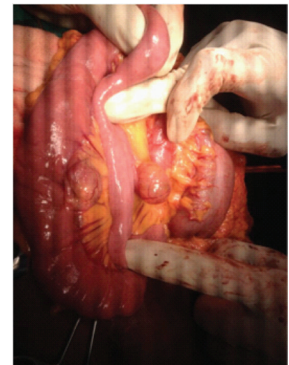
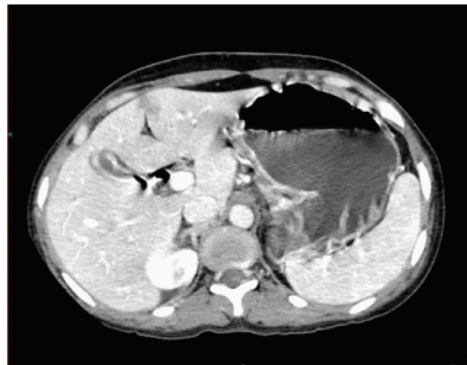
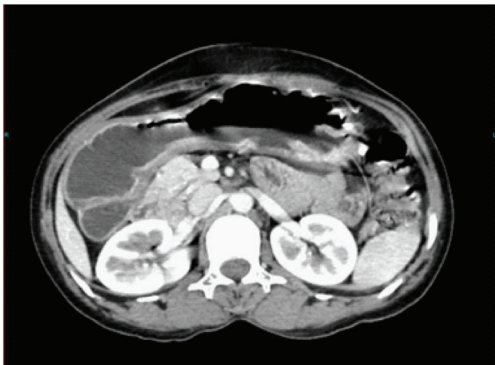
## CASE REPORT

A 39-year-old female was admitted with 6 year history of pain abdomen with periods of exacerbation and remission with vomiting after food for six months. On examination, the patient was reasonably well built, mildly anaemic and not jaundiced. Abdominal examination showed visible gastric peristalsis but no mass. Rest of the abdomen was normal. Upper GI endoscopy showed an active ulcer in the first part of duodenum with post bulbar stenosis. Contrast CT abdomen showed a dilated and thickened stomach and first part of duodenum with obstruction of the outlet [Table/Fig-1]. The CT also showed gas in the biliary tract [Table/Fig-2]. Patient was operated upon after adequate preparation. Operative findings confirmed dilated and thickened stomach with gastric outlet obstruction due to cicatrised chronic duodenal ulcer. In addition to these findings multiple jejunal diverticulae were found [Table/Fig-3]. The jejunal diverticulae were not disturbed as they were incidental findings without any complication. The choledochoduodenal fistula also did not require any surgical intervention because the patient did not have any biliary obstruction. Truncal vagotomy and posterior gastrojejunostomy was done. Patient made a smooth recovery and was discharged on the 10th post operative day.

## DISCUSSION

Bartholin first described a biliary enteric fistula in 1654, but duodenal ulcer as a cause for choledochoduodenal fistula was first recognized and published by Long in 1840 in the London Medical Gazette [1]. Biliary-enteric fistula is a rare complication, occurring in 0.3-0.5 % of patients who have been treated for chronic duodenal ulcer disease [1-3]. Spontaneous choledochoduodenal fistulas are infrequent and are usu-

ally secondary to peptic ulcer disease in 80% of cases and they appear with the signs and symptoms of the underlying peptic ulcer disease [2]. Since 1987 to 2004, a total of 199 cases of Choledochoduodenal fistula secondary to duodenal ulcer have been reported in world literature, according to publications sited in Medline database, but the actual incidence is probably higher, as the majority of Choledochoduodenal fistulas are asymptomatic [4-6]. Choledochoduodenal fistulas account for only 1-25% of biliary enteric fistulas cases [5]. Only 5-6% of biliary enteric fistula cases are associated with duodenal peptic ulcers [7]. The first sign of this abnormal biliary-enteric communication may be the presence of air in the biliary tree as seen on plain X-ray, ultrasound or CT of the abdomen [8]. The natural history of Choledochoduodenal fistulas caused by ulcers is determined by features of the underlying chronic duodenal ulcer [9]. Most often ulcer healing is accompanied by fistula healing [9, 10]. Surgery is reserved for patients with poorly controlled or recurrent ulcer symptoms, major ulcer complications, such as perforation, haemorrhage, or obstruction, or exceptional cases with cholangitis or biliary obstruction [9]. A complete follow-up for as long as 12 years confirms the previous observations that jaundice, cholangitis, or abnormal liver function are rarely encountered in ulcerogenic choledochoduodenal fistulas [10]. Treatment should be directed towards peptic ulcer disease relief rather than correction of choledochoduodenal fistula [10]. In many patients, optimal results may be achieved by using only oral medical therapy [1,10]. If operation is indicated, vagotomy and gastroenterostomy will accomplish these goals and obviate the necessity of entering a scarred duodenum and leaves the choledochoduodenal fistula to heal by itself [10]. Spontaneous choledochoduodenal fistula has been described in patients



**[Table/Fig-1]:** Contrast CT abdomen showing dilated stomach with outlet obstruction **[Table/Fig-2]:** CT showing gas in the biliary tract **[Table/Fig-3]:** Showing jejunal diverticulae

with chronic posterior duodenal ulcer or cicatrised chronic duodenal ulcer. However, the combination of chronic duodenal ulcer and spontaneous choledochoduodenal fistula, gastric outlet obstruction and multiple jejunal diverticulae in the same patient has not been described in the literature.

## CONCLUSION

This patient who had spontaneous biliary enteric fistula as well as gastric outlet obstruction due to chronic duodenal ulcer also had multiple jejunal diverticulae. With truncal vagotomy and gastrojejunostomy, the patient completely recovered and was relieved of symptoms. This case is reported for its rarity and to emphasize that spontaneous biliary enteric fistula does not require surgical intervention for the fistula itself but treatment must be directed towards the alleged aetiopathogenic lesion leading to biliary enteric fistula which itself will facilitate biliary fistula closure. Multiple jejunal diverticulae also can be left without any surgical intervention if they were incidental finding only.

## REFERENCES

- [1] Long J. On the post-mortem appearances found after burns. *Lond Med Gaz.* 1840;25:743.

- [2] Michowitz M, Farago C, Lazarovici I, et al: Choledochoduodenal fistula: a rare complication of duodenal ulcer. *Am J Gastroenterol.* 1984;79:416-20.
- [3] Misra MC, Grewal H, Kapur BML: Spontaneous Choledochoduodenal fistula complicating peptic ulcer disease. A case report. *Jpn J Surg.* 1989;19:367-69.
- [4] Parekh D, Segal I, Ramalho RM: Choledochoduodenal fistula from a penetrating duodenal ulcer. *SAMJ.* 1992;81:478-79.
- [5] Zhu-Ming J, Wei P, Li-min F: Choledochoduodenal fistula: a rare complication of duodenal ulcer. *Chin Med J.* 1986;99:782-84.
- [6] Naga M, Mogawer MS: Choledochoduodenal fistula rare sequel of duodenal ulcer, *Endoscopy.* 1991;23:307-08.
- [7] Marshall SF, Polk RC. Spontaneous internal biliary fistula. *Surg Clin North Am.* 1958;38:679.
- [8] Topai U, Savei G, Sadikoglu MY, et al; Choledochoduodenal fistula secondary to duodenal peptic ulcer. A case report. *Acta Radiologica.* 1997;38:1007-09.
- [9] Feller ER, Warsaw AL, Schapiro RH: Observations on management of choledochoduodenal fistula due to penetrating peptic ulcer. *Gastroenterology.* 1980;76:126-31.
- [10] N.S. Xeropotamos, V.E. Nousias, A.D. Vekris, K.H. Katsanos, E.V. Tsianos, A.M. Kappas Choledochoduodenal fistula: an unusual complication of penetrated duodenal ulcer disease. *Annals of Gastroenterology.* 2004;17(1):104-08.

### AUTHOR(S):

1. Dr. Palaniappan. M
2. Dr. N. S. Kannan
3. Dr. JayaKarthik. Y
4. Dr. Karthikesh. S

### PARTICULARS OF CONTRIBUTORS:

1. Professor, Department of General Surgery, Mahatma Gandhi Medical College and Research Institute, Pillaiyarkuppam, Pondicherry, India.
2. Associate Professor, Department of General Surgery, Mahatma Gandhi Medical College and Research Institute, Pillaiyarkuppam, Pondicherry, India.
3. Assistant Professor, Department of General Surgery, Mahatma Gandhi Medical College and Research Institute, Pillaiyarkuppam, Pondicherry, India.

4. Post Graduate Resident, Department of General Surgery, Mahatma Gandhi Medical College and Research Institute, Pillaiyarkuppam, Pondicherry, India.

### NAME, ADDRESS, E-MAIL ID OF THE CORRESPONDING AUTHOR:

Dr. N.S.Kannan,  
Associate Professor, Department of General Surgery,  
Mahatma Gandhi Medical College and Research Institute,  
Pillaiyarkuppam, Pondicherry-607402, India.  
Phone : 9843330521, E-mail: drnskannan@yahoo.co.in

**FINANCIAL OR OTHER COMPETING INTERESTS:**  
None.

Date of Publishing: Dec 01, 2014