

# Clinical Study of Granulomatous Mastitis- A Rare Entity

AYUSH MOHAN GOEL<sup>1</sup>, KESHAV PRASAD<sup>2</sup>, SUNIL KUMAR MATH<sup>3</sup>,  
VIVEK VISWANATH<sup>4</sup>, MONIKA GARG<sup>5</sup>, ARUSHI BHURA<sup>6</sup>



## ABSTRACT

**Introduction:** Granulomatous Mastitis (GM), a rare and benign disorder, has two forms- Idiopathic Granulomatous Mastitis (IGM) and Specific Granulomatous Mastitis (SGM). IGM is caused without any particular discernable and attributable cause while SGM is caused secondary to tuberculosis, other infectious causes like syphilis, fungal, parasitic infections, corynebacterial; Wegener's granulomatosis, sarcoidosis, reaction to a foreign body, vasculitis etc.

**Aim:** To identify clinical presentations and to formulate a treatment protocol for patients with granulomatous mastitis.

**Materials and Methods:** This prospective descriptive observational study was conducted at Government Wenlock Hospital and Kasturba Medical College Hospital, Attavar, Mangalore, Karnataka, India, from October 2015 to March 2018 on 32 patients admitted to the Department of General Surgery in the study centre, who had a histopathological diagnosis of granulomatous mastitis. All the relevant data of the patients: demographic data and clinical findings, any medical co-morbidities were collected by telephonic interview and case sheets, operative notes were studied thoroughly and the patients were followed-up for regression of their signs and symptoms at one month, two months and six months of their hospital visits. Results of microbial cultures or stains,

imaging (mammography, ultrasound, if done) and biopsy results were collected. All the collected data was analysed by Chi-square test and Fisher's-exact test and the p-values <0.05 was considered significant.

**Results:** Total of 32 female patients (13 patients were in the age group of 31-40 years) were analysed in the present study. A total of 27 (84.4%) had last child birth <5 years back. The patients who presented with a left laterality lesion were 25 (78.1%) with statistically significant difference (p-value=0.049). A total of 18 (56.2%) of the patients had a lesion in the upper outer while 11 (34.4%) in lower outer quadrant of breast. A total of 29 (90.6%) of patients, the disease was extending upto the areola region. All the patients had a firm lump and out of these, 25 (78.1%) of the patient presented with a painful lump. Inflammatory skin changes were seen in 20 (62.5%) of the patients. Retraction of nipple was presented in 26 (81.2%) of the patients. A total of 19 (59.4%) patients underwent an excision biopsy of the lump and 22 (68.8%) patients were initiated with Antitubercular Therapy (ATT).

**Conclusion:** Granulomatous mastitis is a highly unpredictable disease with frequent flares and periods of inactivity which may falsely be considered as successful treatment. Due to rare nature of this disease, randomisation of all treatment modalities are available.

**Keywords:** Breast tuberculosis, Rare mastitis, Tubercular mastitis

## INTRODUCTION

Granulomatous Mastitis (GM) has been a rare entity in clinical practice, with diagnosis of rarity in most cases, was first described in the year 1972 by the team of Kessler E and Wolloch Y [1] as it mimics carcinoma breast clinically. Two forms of GM has been described in literature as idiopathic and specific granulomatosis. The SGM has most commonly been seen in Asia and Africa region. It can be encountered at any age. The cause in most cases were found to be tuberculosis, sarcoidosis and autoimmune disorders, with recent increase in cases secondary to undiagnosed tuberculosis.

The prevalence of the disease as described by a study undertaken by Baslaim MM et al., reported that out of 1106 patients diagnosed as having benign breast diseases in their clinics, 1.8% of them were diagnosed as having IGM [2]. The IGM is defined as granulomatous mastitis without any particular discernable and attributable cause and SGM has been concluded as secondary to tuberculosis, other infectious causes like syphilis, fungal, parasitic infections, corynebacterial; Wegener's granulomatosis, sarcoidosis, reaction to a foreign body, vasculitis etc. [3]. An autoimmune aetiology has also been advocated in few recent studies.

The IGM is diagnosed when there is presence of non caseified granulomatous inflammation on histological sections. It has generally been seen in reproductive age group females with a usual age range of 17-42 years and most commonly during the immediate 2-6 years

of postpartum period [4]. The SGM has most commonly been seen in Asia and Africa region. It can be encountered at any age. The cause in most cases were found to be sarcoidosis and tuberculosis and autoimmune disorders. Multiple recent studies have postulated the recent increase in the number of reported cases in South Asia region due to undiagnosed Tuberculosis (TB) infection.

Hence, this study was conducted to identify clinical presentations and to formulate a treatment protocol for patients with granulomatous mastitis.

## MATERIALS AND METHODS

The present study was a prospective descriptive observational analysis with patient followed-up upto six months and 12 months, conducted in hospitals attached to Kasturba Medical College, including Government Wenlock Hospital and Kasturba Medical College Hospital, Attavar, Mangalore, Karnataka, India, from October 2015 to March 2018. Informed and written consent was obtained from all the patients included in the study, explaining the details of the study and the study protocol was approved by Institutional Ethics Committee (IEC) [Approval letter No. IEC KMC MLR 10-16/261].

**Inclusion criteria:** All patients with breast lump with constitutional symptoms presenting to the Department of General Surgery in hospitals attached to Kasturba Medical College, Mangalore, Karnataka, India, were included in the study, who had a histopathological diagnosis of GM.

**Exclusion criteria:** The patients with negative histology for granulomatous mastitis, or those who were established as cases of carcinoma breast on evaluation, those with any other benign breast diseases like acute mastitis, breast abscess, fibroadenoma, fibroadenosis, duct ectasia and plasma cell mastitis were excluded.

### Study Procedure

All the relevant data of the patients (n=32) like demographic data including age, last child birth, laterality of the breast involved, duration of their symptoms, clinical findings, any medical co-morbidities that included history of any of the following: tuberculosis, sarcoidosis, chronic inflammatory or granulomatous diseases were collected by telephonic interview and case sheets and the patients were followed-up for regression of their signs and symptoms at one month, two months and six months of their hospital visits. Results of microbial cultures or stains, imaging (mammography, ultrasound, if done) and biopsy results were collected. Operative records and operative notes were reviewed for all the patients who underwent a surgical procedure, and details were collected including type of surgery and the extent of excision. Various drugs used in management of the patients were documented including empirical antibiotics, ATT and corticosteroids.

### STATISTICAL ANALYSIS

Chi-square test and Fisher's-exact test were used in the descriptive analysis of the data. Statistical Package for Social Sciences (SPSS) version 17.0 was used to do the analysis and a p-value of <0.05 was taken as statistically significant.

### RESULTS

A total of 32 patients were analysed in this study. Out of these, most of the patients 13 (40.6%) were in age group of 31-40 years [Table/Fig-1]. None of the patients had co-morbid illness and none of the patients had any significant past medical history.

Age group (years)	n (%)
21-30	11 (34.4)
31-40	13 (40.6)
Above 40	8 (25.0)
Total	32 (100)

[Table/Fig-1]: Age distribution of patient's at time of presentation.

Except 1 (3.1%) patient who was nulliparous at time of presentation, all the patients had a history of atleast one child birth, out of which 22 (68.8%) were multiparous and 9 (29%) primipara and 27 (84.4%) patients had history of child birth and hence breast feeding in last five years. Statistically significant values were obtained (p-value <0.0001). A total of 25 (78.1%) patients presented with a lesion on the left side of the breast while 7 (21.9%) on the right side which may be the result of preferential breast feeding from the right-side as was noted in most patients of the present study, which was found to be statistically significant with p-value 0.049, as well. Among those with a left sided disease, 21 patients (84%) had a lesion which had the greatest dimension >5 cm and among those with right-sided disease, majority of the patients, 4 (57%) had a size <5 cm, the findings which were statistically significant (p-value=0.048). A total of 18 (56.2%) of the patients had a lesion in the upper outer and 11 (34.4%) in lower outer quadrant of breast. A total of 29 (90.6%) patients had the extension of lesion upto the nipple-areola region, out of which 26 (89.7%) had a history of childbirth in the last five years. All the patients in the present study presented with a firm lump mimicing a malignant lesion.

In 21 (84%) patients, the greatest dimension was >5 cm however no statistical significance was found on size of lesion on outcome of the treatment of disease in this study. A total of 25 (78.1%) patients presented with painful lump, out of which 24% were in

21-30 age group , 44% were in 31-40 age group and only 32% were older than 40 years, while 7 (21.9%) patients with painless lump. Inflammatory skin changes were seen in 20 (62.5%) patients and 10 (31.3%) patients had sinus at the site due to delay in presentation. A total of 26 (81.2%) patients had retraction of nipple, 19 (59.4%) patients presented with positive axillary lymph nodes however, 13 patients (40.6%) of them did not have axillary lymphadenopathy. A total of 30 patients (93.8%) cases had total leukocyte count normal which ruled out abscess.

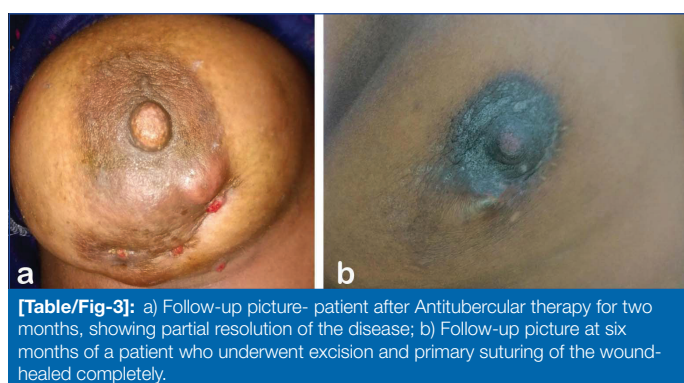
Most patients, 20 (62.5%) presented within three months of starting of their symptoms, however there were still 12 (37.5%) of patients who presented much later which can be attributed to the fact that occasionally this disease does cause a painless lump, resulting in delayed presentation to hospital [Table/Fig-2]. Fourteen (43.7%) patients who presented to Outpatient Department (OPD) had already been administered a few courses of empirical antibiotics by local general practitioner, as the condition was misdiagnosed as a simple breast abscess.

Time lag period division	Frequency (n)	Percentages (%)
Below 3 months	20	62.5
3-9 months	9	28.1
Above 9 months	3	9.4
Total	32	100.0

[Table/Fig-2]: Time lag between starting of symptoms and presentation to OPD.

A 19 (59.4%) of the patients underwent an excision biopsy of the lump, while, remaining 13 (40.6%) were managed conservatively with either incision and drainage, and if absolutely necessary, followed by ATT for a period of six months. Among all the patients treated, 22 (68.8%) patients received ATT as out of the total 32 patients in this study 10 patients had recovery with the empirical antibiotics and excision with drainage in some.

At one month follow-up, 18 (56.3%) of all the patients treated showed partial resolution. Seven patients (21.9%) had complete resolution and the rest 7 (21.9%) had no resolution. The resolution of disease was complete in 19 (59.4%) of our patients at two month follow-up period. Total of 31 (96.9%) of the patients showed complete resolution of the disease at the end of six months follow-up period, [Table/Fig-3 a,b] irrespective of the treatment modality instituted and only 1 (3.1%) patient had incomplete resolution, were managed with an extended regimen of ATT, leading to complete resolution at 12 months. All the patients were followed-up for a minimum period of six months [Table/Fig-3b] during the treatment out of which 27 (84.4%) of the patient were followed-up for 12 months and more and none of these patients reported any recurrence of the disease during the follow-up period; around 5 (15.6%) of the patients were followed-up for nine months and in them as well the authors did not see any recurrence of the disease.



[Table/Fig-3]: a) Follow-up picture- patient after Antitubercular therapy for two months, showing partial resolution of the disease; b) Follow-up picture at six months of a patient who underwent excision and primary suturing of the wound-healed completely.

One patient who was a nullipara but presented with a lump and was diagnosed to have granulomatous mastitis by tru-cut biopsy, was managed successfully with six months of ATT leading to complete resolution.

There were four patients who were not in reproductive age group and in whom last child birth was >5 years, but they were diagnosed to have granulomatous mastitis, out of these, two patients underwent excisional biopsy of the lump followed by ATT for six months and other two underwent a tru-cut biopsy followed by ATT. All four had complete resolution of disease at end of six months and reported no recurrence.

## DISCUSSION

The authors observed that 24 patients (75%) of the patient were in early reproductive age group which has also been the findings in multiple other studies by Baslaim MM et al., [2]. In the present study, observation of most of the patient being in early reproductive age group of 21-40 years and having a history of child birth in last five years was also found to be statistically significant ( $p$ -value <0.001). Similar findings have been seen in multiple other studies that have been conducted by Bani-Hani KE et al., [5] Importantly, as seen in few other studies undertaken by Lai ECH et al., [6] where they found the disease in patients who are nulliparous and were post their reproductive age group. Hence, it was concluded that recent history of pregnancy and breastfeeding was an important risk factor but it was less understood and needed to be studied for better understanding [6].

Patients who presented with a painful lump, 24% were in 21-30 years age group and 44% were in 31-40 years of age group, only 32% percent of those with a painful lump were in the older age group of above 40 years. Previous studies observed and concluded that younger age of presentation (21-40 years) was statistically significantly associated ( $p$ -value=0.046) with more chances of lump being painful [7] and such observation has not been made in any other study till date. This observation needs further evaluation in future study which may help us institute more aggressive therapy in these patients at an initial stage to prevent complications.

The authors of the present study observed that the difference of the patients who had history of a recent breastfeeding over the last five years predominantly had a left sided disease and those who did not have a cycle of breastfeeding in last five years had the disease on the right-side, was statistically significant. This points towards the fact that a recent history of breastfeeding predisposes the patient to the disease and more so of the left side. It is also important to note that during interview of the patient in the present study most of the patients who had disease on the left side had for one or the other reason fed their baby predominantly from the right side particularly during early period of initiation of breast feeding. Similar findings were reported in the study by Elzahaby IA et al., [8].

The present study observed that among patients with lesion extending up to the nipple-areola complex, 89.7% had history of childbirth in the last five years and 10.3% had no history of childbirth in the last five years. It is important to note that 66.7% patients who did not have extension of the lesion till the nipple-areolar complex belonged to the group without history of childbirth in the last five years. This finding was found to be statistically significant ( $p$ -value=0.011).

As these findings have statistical significance, the authors can safely presume that in patients with a recent child birth, there are significantly higher chances of disease extending to the nipple areolar complex and resulting in retraction of nipple. These findings further provide support to long held belief of various authors about a definite relationship existing between child birth and GM and it also shows why so commonly GM is confused with a malignancy of the breast [9]. It is evident from these findings that there is need for prospective, well-designed studies to clarify the role of hormones in the pathogenesis of IGM.

The authors of the present study observed that, of those with a left sided disease, maximum had the greatest dimension >5 cm and among those with right-sided disease, majority of the patient had

a size <5 cm and the difference was statistically significant when viewed along with the earlier stated finding that most of the patients who had left sided disease had predominantly fed their child from right-side points towards the fact that absence of breastfeeding from a particular side of breast results in lesions with much bigger dimensions if the disease develops in that breast at a later date. Similar observations were done in previous studies as well [9].

In the present study, the authors did not observe any added benefit of empirical antibiotic therapy for patient with GM but in view of literature evidence of infectious agents being one of the causative factors in the aetiology of GM [9], the usefulness of empirical antibiotic therapy in these patients cannot be ruled out. A total of 22 patients (68.8%) were prescribed ATT and as discussed earlier no recurrence were noted in any of the patients in the study. Similarly in study by Farouk O et al., [9] where they administered tablet rifampicin 300 mg twice daily, 60% patients for six months and 40% patients for nine months and 12 months after the initiation of the therapy, all the patients showed complete clinical resolution and ultrasonographic response. They did not report any relapse of symptoms with a mean follow-up period of 15.5 months [9]. Hence the role of rifampicin, to inhibit the growth of many gram negative organisms including atypical mycobacteria, in pathogenesis of IGM and most of the gram positive organisms, became clear [10]. Rifampicin was found to be effective as a solo medical therapy and can be considered as an alternative accepted method not only to surgical excision and thus resulting in avoidance of the complications especially the consequent deformities and recurrences and also the side effects of systemic steroids [10].

None of the present study patients, who were treated conservatively with ATT for six months showed recurrence at end of follow-up period also points towards usefulness of ATT in patients with granulomatous mastitis. Therefore, in Indian subcontinent tuberculosis may be one of the reasons for granulomatous mastitis. The fact that Acid Fast Bacilli (AFB) has rarely been isolated in the cultures or identified on staining maybe because of the lack of proper techniques when isolating the organism and also because most of the studies as well as data are from the western world [8,10,11-14] where the incidence of tuberculosis is very less and thus the evaluators need to modify the approach to evaluation of patients with GM and need to include AFB culture and AFB staining of the tissue in all the patients and also include gene expert for mycobacterium tuberculi which may avoid unnecessary use of steroids or surgical interventions.

None of the patients in the present study were administered steroids at any point of time, this is contrary to the current popular belief that IGM is predominantly the result of or part of an autoimmune disorder [11], however these beliefs have to be viewed along with the fact that most of the patient population in these studies are from the western world [8,10,11-14] and very few studies have been conducted in the Indian subcontinent where infectious causes particularly TB may be a more common cause [15].

In the present study, all the patients were followed-up for a minimum period of six months during the treatment out of which 27 patients (84.4%) of the patient were followed-up for 12 months and more and none of these patients reported any recurrence of the disease during the follow-up period. Around 15.6% of the patient were followed-up for nine months and they did not show any recurrence of the disease either. In most of the literature, the usual rate of recurrence reported was about 5-50% with various treatment modalities however most of these studies were totally retrospective in nature and had a much longer follow-up period as compared to the present study [12].

In the present study, about 59.4% of the patients underwent an excision of the lump in totality and none of the patient came back with a recurrence in the follow-up period. Similar findings were reported by Tauch A et al., [12] in their study. Kok KYY and Telisinghe PU [14] have also proposed surgical treatment as the first modality of choice with any recurrences being managed with a more conservative



approach. However, few authors [6,8,13] do not advocate surgery as the initial treatment of choice and have proposed use of steroids which they have opined helps in two ways-one is by decreasing the size of the lump thus allowing a more limited excision of the lump and in few cases, complete resolution of the disease was also possible by single mode of treatment.

### Limitation(s)

Firstly, small sample size due to rare nature of this disease and secondly a shorter follow-up period were the limitations of the present study.

### CONCLUSION(S)

The clinical presentation of Granulomatous mastitis patients is highly variable as is the method of evaluation and the treatment of this disease. Granulomatous mastitis is a highly unpredictable disease with frequent flares and periods of inactivity which may falsely be considered as successful treatment. Furthermore, due to rare nature of this disease randomisation of all treatment modalities available and suggested in the existing literature has not been possible till date. There exists a need for extensive, well-planned, multi-institutional, prospective trials with much larger patient populations and longer follow-up periods to evaluate the various aspects related to GM, its aetiology, evaluation and management strategies.

### REFERENCES

- [1] Kessler E, Wolloch Y. Granulomatous mastitis: A lesion clinically simulating carcinoma. *Am J Clin Pathol.* 1972;58(6):642-46. Doi: 10.1093/ajcp/58.6.642. PMID: 4674439.
- [2] Baslaim MM, Khayat HA, Al-Amoudi SA. Idiopathic granulomatous mastitis: A heterogeneous disease with variable clinical presentation. *World J Surg.* 2007;31(8):1677-81. Doi: 10.1007/s00268-007-9116-1. PMID: 17541683.
- [3] Tse GMK, Poon CSP, Ramachandram K, Ma TKF, Pang LM, Law BKB, et al. Granulomatous mastitis: A clinicopathological review of 26 cases. *Pathology.* 2004;36(3):254-57.
- [4] Diesing D, Axt-Fliedner R, Hornung D, Weiss JM, Diedrich K, Friedrich M, et al. Granulomatous mastitis. *Arch Gynecol Obstet [Internet].* 2004;269(4):233-36.
- [5] Bani-Hani KE, Yaghan RJ, Matalaka II, Shatnawi NJ. Idiopathic granulomatous mastitis: time to avoid unnecessary mastectomies. *Breast J.* 2004;10(4):318-22.
- [6] Lai ECH, Chan WC, Ma TKF, Tang APY, Poon CSP, Leong HT, et al. The role of conservative treatment in idiopathic granulomatous mastitis. *Breast J.* 2005;11(6):454-56.
- [7] Schelfout K, Tjalma WA, Cooremans ID, Coeman DC, Colpaert CG, Buytaert PM, et al. Observations of an idiopathic granulomatous mastitis. *Eur J Obstet Gynecol Reprod Biol.* 2001;97(2):260-62.
- [8] Elzahaby IA, Khater A, Fathi A, Hany I, Abdelkhalik M, Gaballah K, et al. Etiologic revelation and outcome of the surgical management of idiopathic granulomatous mastitis. An Egyptian centre experience. *Breast Dis.* 2016;36(4):115-22.
- [9] Farouk O, Abdelkhalik M, Abdallah A, Shata A, Senbel A, Attia E, et al. Rifampicin for idiopathic granulomatous lobular mastitis: A promising alternative for treatment. *World J Surg.* 2017;41(5):1313-21.
- [10] Wallis RS, Weyer K, Fourie PB. Acquired rifamycin resistance: Pharmacology and biology. *Expert Rev Anti Infect Ther [Internet].* 2008;6(2):223-30.
- [11] Radoska-Leśniewska DM, Skopińska-Różeńska E, Jóźwiak J, Demkow U, Joanna Bała B. Angiomodulatory properties of some antibiotics and Tolpa Peat Preparation. *Cent J Immunol.* 2016;41(1):19-24.
- [12] Tauch A, Fernández-Natal I, Soriano F. A microbiological and clinical review on *Corynebacterium kroppenstedtii*. *Int J Infect Dis.* 2016;48:33-39.
- [13] Erozgen F, Ersoy YE, Akaydin M, Memmi N, Celik AS, Celebi F, et al. Corticosteroid treatment and timing of surgery in idiopathic granulomatous mastitis confusing with breast carcinoma. *Breast Cancer Res Treat [Internet].* 2010;123(2):447-52.
- [14] Kok KYY, Telisinghe PU. Granulomatous mastitis: Presentation, treatment and outcome in 43 patients. *Surg.* 2010;8(4):197-01.
- [15] Nayal B, Vasudevan G, Singh VK. Fine needle aspiration cytology of granulomatous lesions of the breast a six-year retrospective study. *Annals of Pathology and Laboratory Medicine.* 2020;7(2):A52-A55. Doi: <https://doi.org/10.21276/apalm.2561>.

#### PARTICULARS OF CONTRIBUTORS:

1. Assistant Professor, Department of General Surgery, Kasturba Medical College, Mangalore, Karnataka, India.
2. Associate Professor, Department of General Surgery, Kasturba Medical College, Mangalore, Karnataka, India.
3. Assistant Professor, Department of General Surgery, Kasturba Medical College, Mangalore, Karnataka, India.
4. Assistant Professor, Department of General Surgery, Kasturba Medical College, Manipal, Karnataka, India.
5. Senior Resident, Department of Anaesthesia, SMS Medical College, Jaipur, Rajasthan, India.
6. Clinical Observer, Department of General Surgery, Kasturba Medical College, Mangalore, Karnataka, India.

#### NAME, ADDRESS, E-MAIL ID OF THE CORRESPONDING AUTHOR:

Sunil Kumar Math,  
Flat 17, C-3 Block, KMC Staff Quarters, LH Road, Jyothi Circle,  
Mangalore, Karnataka, India.  
E-mail: sunilmath579@gmail.com

#### PLAGIARISM CHECKING METHODS: [Jain H et al.]

- Plagiarism X-checker: Jul 20, 2022
- Manual Googling: Sep 22, 2022
- iThenticate Software: Sep 30, 2022 (6%)

#### ETYMOLOGY: Author Origin

#### AUTHOR DECLARATION:

- Financial or Other Competing Interests: None
- Was Ethics Committee Approval obtained for this study? Yes
- Was informed consent obtained from the subjects involved in the study? Yes
- For any images presented appropriate consent has been obtained from the subjects. Yes

Date of Submission: **Jul 18, 2022**

Date of Peer Review: **Sep 12, 2022**

Date of Acceptance: **Sep 30, 2022**

Date of Publishing: **Oct 01, 2022**