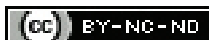

Association between American College of Radiology Thyroid Imaging Reporting and Data System and Bethesda Scoring System in Assessment of Thyroid Nodule: A Prospective Cross-sectional Study

RITHI MELISSA DSILVA¹, HB SURESH², CS JAYAPRAKASH³

ABSTRACT

Introduction: In view of increased detection of incidental thyroid nodules on ultrasonography, there is a need for standardising the reporting system of thyroid nodules for better patient management.

Aim: To assess concordance between two classification systems of thyroid nodules: American College of Radiology (ACR) Thyroid Imaging Reporting and Data System (TI-RADS) 2017 criteria on sonography and Bethesda categories on cytology.

Materials and Methods: A prospective, cross-sectional validation study was conducted in Department of Radiology in collaboration with the Department of Pathology at a tertiary care hospital in Dakshina Kannada district, Karnataka, India, over a period of 12 months between October 2017 to September 2018. A total of 175 thyroid nodules detected on Ultrasonography (USG) were categorised based on ACR TI-RADS 2017 criteria. Ultrasound guided Fine Needle Aspiration Cytology (FNAC) was performed on the nodules and were scored on the basis of Bethesda categories.

Nodules were categorised into benign and malignant under TI-RADS and Bethesda and their concordance was assessed. Sensitivity, specificity, positive and negative predictive value was assessed. Pearsons Chi-square test statistical method and kappa values were used in analysis. A p-value of <0.05 was considered as significant.

Results: Solid composition, hypoechoic echotexture, Wider than tall nodule, irregular margin and microcalcification descriptors of ACR TI-RADS 2017 system were features more in favour of a malignant nodule. With FNAC as gold standard, TI-RADS had a sensitivity, specificity, positive and negative predictive value and diagnostic accuracy of 91.7%, 86.3%, 63.5%, 97.6% and 87.4% respectively. The Kappa value was 0.67 which indicates very good agreement with a p-value of <0.001.

Conclusion: The stratification of risk among thyroid nodules as benign or malignant using ACR TI-RADS 2017 criteria yielded good result in our study. With careful examination of nodules, TI-RADS can be used to select appropriate nodules for further evaluation with cytology.

Keywords: Concordance, Fine needle aspiration, Malignancy risk, Ultrasound

INTRODUCTION

Thyroid gland is an endocrine gland which is located superficially in the region of neck. Due to its superficial location, USG plays an important role in assessing pathologies in the gland [1]. Thyroid nodule is any lesion in the thyroid gland that is discrete and is radiologically distinct from the surrounding thyroid parenchyma [2].

Among the radiologic procedures, High Resolution Ultrasonography (HRUS) is a sensitive, relatively inexpensive, non invasive and an easily accessible modality of imaging for examination of thyroid gland [2]. With development of ultrasound technology and transition from A-mode to B-mode and then to gray-scale imaging, the quality of imaging has improved and interpretability of ultrasound images is better [3]. The prevalence of incidental thyroid nodule can vary from 10-41% in general population on HRUS [4].

Hence there is a need for standardising the reporting system for thyroid nodules which is easily reproducible and would facilitate better patient management based on their risk of malignancy. In order for radiologists to communicate with the physicians regarding certain pathologies, and eliminate the ambiguity between different radiologists' reports there is a need for an organised and standard reporting system which helps the physician understand the report better.

With this intention and background, the first edition of a standardised lexicon was released for breast imaging reporting in 1993 by ACR

and was named Breast Imaging Reporting and Data System (BIRADS) [5,6]. Similar lexicons that have been developed for other areas of imaging include Liver Imaging Reporting and Data System (LI-RADS) for liver, Head Injury Imaging Reporting and Data System (HI-RADS) for head injury, Lung Imaging Reporting And Data System (Lung-RADS) for lung cancer screening and Prostate Imaging Reporting and Data System (PI-RADS) for prostate cancer [6].

The concept of TI-RADS gives a direction regarding the management of incidentally detected lesions depending on the score it holds as well as categorises thyroid nodules as benign or suspicious for malignancy. It also helps in deciding the next plan of action for the nodule depending on the score it holds. The Bethesda System for Reporting Thyroid Cytology (TBSRTC) is a category based, standardised reporting system for FNAC specimens of thyroid [7].

Very few published data on Indian ethnicity are available in literature with regard to TI-RADS. One of the recent published article from Kolkata, India, revealed only moderate agreement between TI-RADS and Bethesda systems. The highest degree of discordance was for follicular lesions in this study. However, good concordance was observed for thyroid nodules which were benign [8].

Another recent study published in 2020 also revealed that with higher TI-RADS score, probability of malignant cytology was higher. However, in this study, majority of the TI-RADS 4 and TI-RADS 5 lesions belonged to benign cytology categories [9].

In view of few heterogenous literature results and lack of published articles from Southern India, this study aimed to assess the concordance between ACS TI-RADS 2017 [10] and Bethesda [7] system in the target population. In the study, thyroid nodules were grouped under the above mentioned ultrasound and cytology categories following FNAC to look for the degree of concordance. The objective of our study would be to estimate the proportion of various categories of thyroid nodules based on ACR TI-RADS and Bethesda categories and to estimate the strength of association between ACR TI-RADS scoring system and Bethesda scoring system in evaluation of thyroid nodules.

MATERIALS AND METHODS

This prospective, cross-sectional validation study was conducted in Department of Radiology in collaboration with the Department of Pathology. The study was conducted in a tertiary care hospital in Dakshina Kannada District, Karnataka, India, over a period of one year between October 2017 to September 2018. Institutional Ethics Committee approval was attained for the study (Ref. No: FMCC/FMIEC/4427/2017). Informed and written consent was taken from each patient prior to the study.

Sample size calculation: The sample size was determined to be a minimum of 170 patients based on the overall agreement (p-value=87.2%) according to the study on concordance between the TI-RADS ultrasound criteria and the Bethesda cytology criteria on the non toxic thyroid nodule by Vargas-Uricoechea H et al., [11]. The allowable error was 5%.

The formula used for calculation was:

$$n = Z\alpha^2 p (1-p) / e^2$$

Where, n=sample size, $Z\alpha=1.96$ at 95% confidence interval and e=allowable error.

Inclusion criteria: All patients with clinically suspected thyroid nodule above the age of 18 years, sent for ultrasonography of thyroid gland to Department of Radiodiagnosis. Since most of the patients referred for ultrasonography of neck were adults, 18 years was taken as age cut-off for the study.

Exclusion criteria: All diffuse thyroid pathologies without distinct nodules, patients who have not undergone cytologic diagnosis. Patients in whom cytology specimen is non diagnostic, and also with previous history of thyroid surgery were excluded from the study.

Study Procedure

Thyroid ultrasonography was performed in Philips Affinity 50 G ultrasound system with 4-12 MHz high frequency linear probe. Nodules were categorised based on ACR TI-RADS 2017 [10], by assigning appropriate points under each category.

Ultrasound guided FNAC was performed by radiologist on the most suspicious nodule/nodules based on the recommendations from ACR [10] as well as the nodules referred by surgeons/endocrinologist for USG guided FNA examination. Slides were prepared immediately by the pathologist and were taken for examination under microscope. The nodules were scored by the pathologist on the basis of Bethesda categories [7].

The nodules were categorised into benign and malignant under both scoring systems and concordance between TI-RADS and Bethesda was calculated.

Technique of Ultrasound neck:

Scanning technique: Patients were examined in supine position with neck slightly extended. A thorough examination was done in a transverse plane as well as sagittal plane. Observations were made and tabulated.

The observations under categories included in ACR TI-RADS 2017 [10] were made for each nodule. Other observations included: vascularity pattern in the nodule, presence of cervical lymph nodes, assessment of the carotid and jugular vessels and assessment of the soft tissues of neck.

In case of multiple nodules, each nodule was assessed for all characteristics.

Technique of USG guided FNAC: The patient was briefed regarding the procedure and consent was taken for the same. FNAC was performed by radiologist standing beside the patient's chest or head end. The area of interest and linear transducer were cleansed with povidone-iodine and draped. A sterile cover placed over the USG probe. The probe was then positioned to view the target nodule. FNAC was then performed under continuous USG guidance, with orientation of the needle parallel or perpendicular to the USG probe. Soon after aspiration from the nodule, the sample was handed over to the pathologist to prepare the slides for cytology. On an average about two to four passes were taken from the nodule under examination. After completion of the procedure, the skin was cleansed, and a sterile dressing placed after applying gentle pressure on the area.

STATISTICAL ANALYSIS

Concordance between TI-RADS and Bethesda was calculated using sensitivity, specificity, positive predictive value, and negative predictive value. Pearson's Chi-square test statistical method and kappa values were used for statistical analysis of data and level of significance was assessed. A p-value of <0.05 was considered as significant.

RESULTS

The study group included 175 patients between 20 to 85 years of age. The mean age of presentation was 48 years. The most common age group affected belonged to 41 to 50 years (34%) and the least common age group affected was 71 to 80 years (2%).

Maximum benign as well as malignant nodules were observed between 41 to 50 years of age. Least number of benign nodules were noted in >70 years age (one out of 139 nodules) and least number of malignant nodules were noted in <30 years age (one out of 36 nodules).

Present study included a total of 175 patients, of which 87.4% (n=153) were females and 12.6% (n=22) were males. Of the 153 nodules in female patients, 128 (83.7%) nodules were benign on FNAC and 25 (16.3%) nodules were malignant. Out of the 22 nodules diagnosed in male patients 11 (50%) were benign and 11 (50%) were malignant on FNAC.

Ultrasonographic findings: Thyroid nodules were described under categories of composition, echogenicity, shape, margin and echogenic foci within as described by ACR TI-RADS 2017 [10] categories. The following results were observed and compared with FNAC categories [Table/Fig-1-5].

Composition on USG	FNAC number of nodules		Total
	Benign	Malignant	
Cystic	4	0	4
Mixed cystic solid	114	12	126
Solid	20	24	44
Spongiform	1	0	1
Total	139	36	175

[Table/Fig-1]: Composition of the nodule vs nature of nodule. p-value (using chi-square test) for composition of the nodule was <0.001; p-value <0.05 considered significant

Echogenicity on USG	FNAC number of nodules		Total
	Benign	Malignant	
Anechoic	5	0	5
Iso/hyperechoic	127	18	145
Hypoechoic	7	17	24
Very hypoechoic	0	1	1
Total	139	36	175

[Table/Fig-2]: Echogenicity of the nodule vs nature of nodule. p-value (Using chi-square test) for echogenicity of the nodule was <0.001; p-value <0.05 considered significant

Shape of the nodule on USG	FNAC number of nodules		Total
	Benign	Malignant	
Wider than tall nodule	138	30	168
Taller than wide nodule	1	6	7
Total	139	36	175

[Table/Fig-3]: Shape of the nodule vs nature of nodule. p-value (Using chi-square test) for shape of the nodule was <0.001; p-value <0.05 considered significant

Margin of the nodule on USG	FNAC Number of nodules		Total
	Benign	Malignant	
Smooth	137	26	163
Lobulated/irregular	1	8	9
Extra thyroid extension	0	1	1
Ill defined	1	1	2
Total	139	36	175

[Table/Fig-4]: Margin of the nodule vs nature of nodule. p-value (Using chi-square test) for nodule margin was <0.001; p-value <0.05 considered significant

Calcifications		FNAC number of nodules		Total
		Benign	Malignant	
Punctate echogenic foci	Absent	136	14	150
	Present	3	22	25
Peripheral calcifications	Absent	132	35	167
	Present	7	1	8
Macro calcification	Absent	108	25	133
	Present	31	11	42

[Table/Fig-5]: Calcific foci in thyroid nodule on ultrasonography. p-value (Using chi-square test) for macrocalcification was 0.3, peripheral calcification was 0.5 and punctate echogenic foci (microcalcification) was <0.001; p-value <0.05 considered significant

Thyroid nodule size vs nature of nodule: The thyroid nodule size did not show any significance in our study in relation to the nature of nodule being benign or malignant. About 54 (38.8%) of benign nodules were between 21 to 30 mm and 43 (30.9%) were between 11 to 20 mm. Among malignant nodules, 15 (41.7%) were >30 mm and 11 (30.6%) were between 11 to 20 mm.

Thyroid nodule vascularity vs nature of nodule: Out of 36 malignant nodules, 32 (88.8%) showed intrinsic vascularity, 2 (5.6%) showed peripheral vascularity and 2 (5.6%) showed no significant vascularity. Out of 139 benign nodules, 31 (22.3%) nodules showed intrinsic vascularity, 71 (51%) showed peripheral vascularity and 37 (26.6%) showed no vascularity. Hence in this study, malignant nodules had more of internal vascularity than peripheral vascularity.

In our study, among the nodule descriptors not included in ACR TI-RADS 2017 [10], vascularity of nodule revealed a p-value (Using chi-square test) of <0.001 which was significant. Whereas the p-value (Using chi-square test) for size of the nodule was 0.062 and was not significant.

Statistical analysis of association of nature of nodule with composition, echogenicity, shape of the nodule, margin of

nodule, microcalcifications had a p-value of <0.001 which implies significant association.

The FNAC grades based on Bethesda [7] classification system was compared with sonologic grades based on ACR TI-RADS 2017 [10] for the nodules assessed. The results were tabulated in [Table/Fig-6].

Grade systems		TI-RADS grade					Total
		TI-RADS 1	TI-RADS 2	TI-RADS 3	TI-RADS 4	TI-RADS 5	
FNAC grade	Bethesda I	2	1	0	0	0	3
	Bethesda II	3	72	37	14	0	126
	Bethesda III	0	3	3	5	0	11
	Bethesda IV	0	0	1	7	4	12
	Bethesda V/VI	0	2	0	6	15	23
Total		5	78	41	32	19	175

[Table/Fig-6]: FNAC grade vs TI-RADS grade. Kappa value of 0.318 indicating moderate agreement; p-value <0.001 Total agreement is (2+72+3+7+15)/175 =99/175; p-value <0.05 considered significant

The ACR TI-RADS [10] categories were also compared with FNAC results which were classified under broad categories of benign and malignant and the findings were tabulated in [Table/Fig-7].

TI-RADS grade	FNAC		Total
	Benign	Malignant	
TI-RADS 1	5	0	5
TI-RADS 2	76	2	78
TI-RADS 3	40	1	41
TI-RADS 4	18	14	32
TI-RADS 5	0	19	19
Total	139	36	175

[Table/Fig-7]: TI-RADS grade vs FNAC grade.

Comparison of statistical parameters of ACR TI-RADS 2017 [10] and Bethesda [7] FNAC categories have been tabulated in [Table/Fig-8]. For evaluation and statistical analysis, TI-RADS 1, 2, 3 were considered benign and TI-RADS 4 and 5 as malignant. Similarly, Bethesda I, II and III were considered benign and Bethesda IV, V and VI as malignant. With such consideration, on comparison of the test group TI-RADS with the gold standard of FNAC, the study obtained the following results [Table/Fig-9] [12-19]. The Kappa value was 0.67 which indicates very good agreement with a p-value of <0.001.

Test group (TI-RADS)	Gold standard (FNAC)		Total
	Malignant	Benign	
Positive	33	18	51
Negative	3	121	124
Total	36	139	175
Sensitivity	91.7%		
Specificity	86.3%		
Positive predictive value	63.5%		
Negative predictive value	97.6%		
Diagnostic accuracy	87.4%		

[Table/Fig-8]: Comparison of statistical parameters of TI-RADS and FNAC.

The ACR TI-RADS lexicon, TR levels, and criteria for fine-needle aspiration or follow-up ultrasound recommendations are depicted in a chart in [Table/Fig-10].

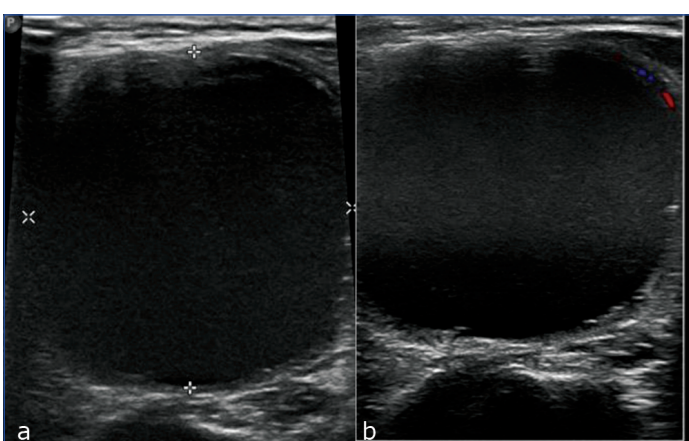
Ultrasonographic image plates of various category of thyroid nodules have been depicted in [Table/Fig-11-15].

Studies on risk stratification systems for thyroid nodules	Risk stratification system used	Sensitivity (%)	Specificity (%)	PPV (%)	NPV (%)	Accuracy (%)
Current study (considering FNAC)	ACR TI-RADS 2017	91.7	86.3	63.5	97.6	87.4
Horvath E et al., [14] 2009	TI-RADS developed by Horvath E et al., [14]	88	49	49	88	94
Russ G et al., [15] 2011	TI-RADS developed by Russ G et al., [15]	95	68	-	-	90
Stoian D et al., [16] 2015	TI-RADS adapted from Russ G et al., [15]	97.9	86.2	97.2	89.2	95.9
Chandramohan A et al., [17] 2016	TI-RADS adapted from Kwak JY et al., [12]	72	68.8	63.9	76.2	70.2
Popli MB et al., [13] 2017	Ultrasound Gray scale characteristics	81.8	87.2	59	95.5	-
Macedo BM et al., (ATA) [19] 2018	2015 ATA's Ultrasound Risk	100	75	-	100	76
Macedo BM et al., (TI-RADS) [19] 2018	TI-RADS adapted by Russ G et al., [15]	100	61.1	-	100	63
Periakaruppan G et al., [18] 2018	TI-RADS adapted from Horvath E et al., [14]	92.3	94.1	54.5	99.3	-

[Table/Fig-9]: Comparison of results of various risk stratification systems [12-19].

Composition (Choose 1)	Echogenicity (Choose 1)	Shape (Choose 1)	Margin (Choose 1)	Echogenic foci (Choose all that apply)
Cystic or almost completely cystic - 0 points	Anechoic - 0 points	Wider than tall - 0 points	Smooth - 0 points	None/large comet tail artifacts - 0 points
Spongiform - 0 points	Hyper/isoechoic - 1 point	Taller than wide - 3 points	Ill defined - 0 points	Macrocalcifications - 1 point
Mixed cystic solid - 1 point	Hypoechoic - 2 points		Lobulated/irregular - 2 points	Peripheral rim calcification - 2 points
Solid or almost completely solid - 2 points	Very hypoechoic - 3 points		Extra-thyroidal extension - 3 points	Punctate echogenic foci - 3 points
0 points	2 points	3 points	4 to 6 points	7 points or more
TR1 Benign	TR2 not suspicious	TR3 mildly suspicious	TR4 moderately suspicious	TR5 highly suspicious
No FNA	No FNA	FNA if ≥ 2.5 cm	FNA if ≥ 1.5 cm	FNA if ≥ 1 cm
		Follow if ≥ 1.5 cm	Follow if ≥ 1 cm	Follow if ≥ 0.5 cm

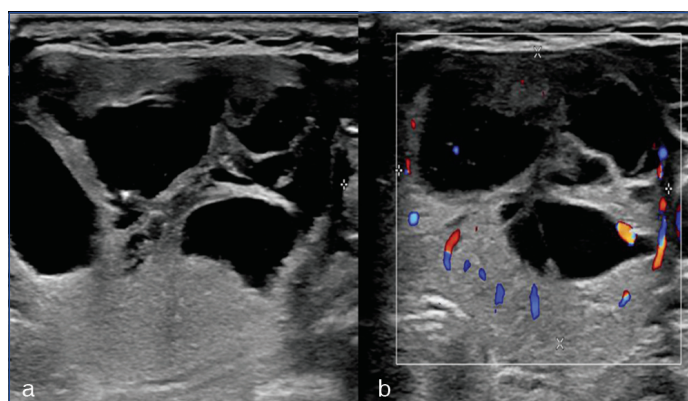
[Table/Fig-10]: Chart showing five categories on the basis of the ACR TI-RADS lexicon, TR levels, and management recommendation (criteria for fine-needle aspiration or follow-up ultrasound). Add points from all levels to determine TI-RADS category [10].



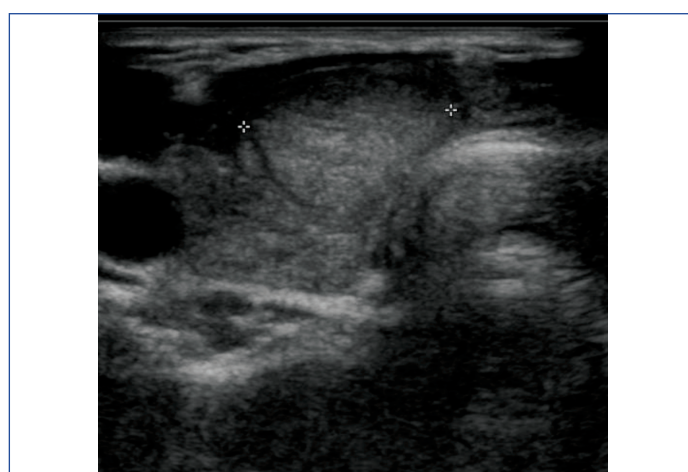
[Table/Fig-11]: TI-RADS 1 category. (a). USG image showing A cystic (score-0), anechoic (score-0), well-defined nodule with smooth margins (score-0) and wider than tall (score-0) in thyroid gland with no evidence of echogenic foci within (score-0); Total TI-RADS score of 0- TR1category, benign lesion. (b) No intrinsic vascularity seen on doppler. Cytology- cyst fluid (Bethesda I).

DISCUSSION

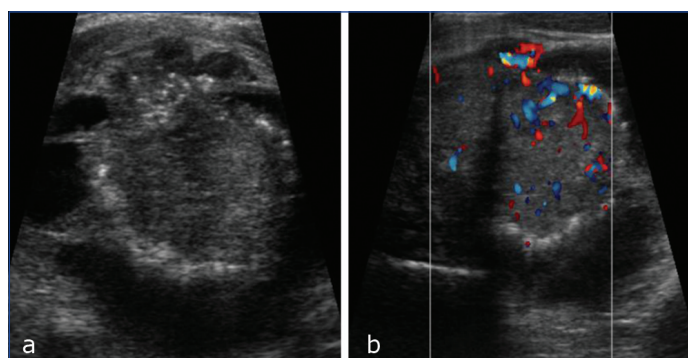
The prevalence of incidental thyroid nodule can vary from 10-41% in general population on High Resolution Ultrasonography (HRUS) with an increase in prevalence among females [4]. A thyroid incidentaloma is defined as an unexpected, asymptomatic thyroid tumour discovered during the investigation of an unrelated condition. Increased detection has led to a state of dilemma among the clinicians concerning its management [20]. There have been many



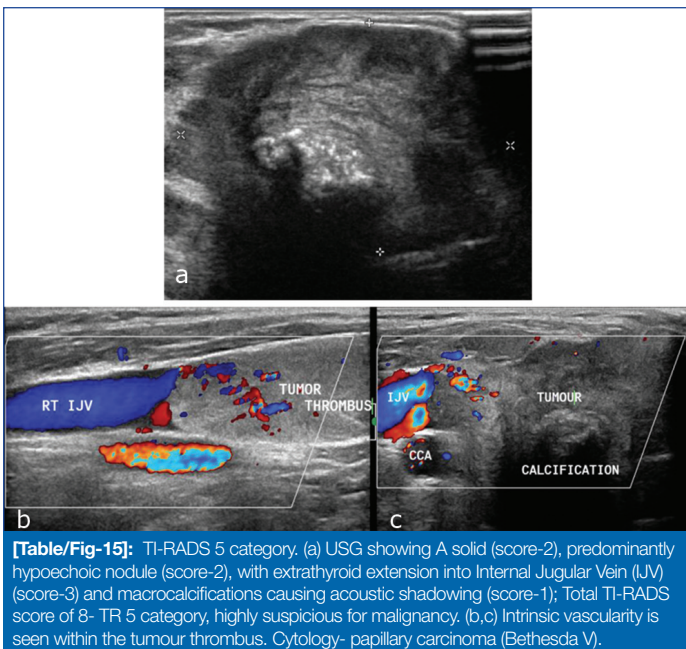
[Table/Fig-12]: TI-RADS 2 category. (a) USG showing A mixed solid cystic lesion (score-1) with predominant hyperechoic solid component (score-1), with smooth margins (score-0), wider than tall (score-0) with no echogenic foci within; Total TI-RADS score of 2- TR 2 category, not suspicious for malignancy. (b) Mild peripheral vascularity seen on doppler Cytology- colloid nodule (Bethesda II).



[Table/Fig-13]: TI-RADS 3. USG showing a solid (score-2), hyperechoic (score-1), with smooth margin (score-0), wider than tall (score-0) with no echogenic foci (score-0). Total TI-RADS score of 3- TR 3 category, mildly suspicious for malignancy. Cytology- adenomatoid nodule (Bethesda II).



[Table/Fig-14]: TI-RADS 4 category. (a) USG shows mixed solid cystic nodule (score-1), predominantly hyperechoic solid component (score-1), with smooth margin (score-0), which is wider than tall (score-0) and shows punctate echogenic foci within (score-3); Total TI-RADS score of 5- TR 4 category, moderately suspicious for malignancy. (b) Intrinsic vascularity is seen on doppler. Cytology- papillary carcinoma (Bethesda V).



studies performed in the recent past with regard to risk stratification systems for thyroid nodules [12-16, 21, 22]. However, a universal lexicon has not been arrived yet.

The current study analyses the accuracy of ACR TI-RADS 2017 criteria [10] for risk stratification of thyroid nodules, considering FNAC as gold standard.

In this study, among malignant nodules, solid pattern was the predominant composition observed. About 11 (55%) of the papillary carcinomas were of solid composition and rest (n=9) were of mixed echogenicity of which one had a background of multinodular goitre. Hence it is essential to carefully examine all the nodules in a case of multinodular goitre and look for malignant imaging characteristics. The FNAC proven Hurthle cell carcinomas (n=3) and a medullary carcinoma (n=1) in our study were solid in composition on USG. Among the two follicular carcinomas, one was of mixed echogenicity and the other was solid in composition. The predominant mixed solid cystic composition in benign nodules can be attributed to high prevalence of colloid nodules or colloid degeneration in a long standing multinodular goitre which comprised of most of the benign cases. Many studies on TI-RADS have shown solid composition of the nodule to be a predictor or suspicious feature of malignant nodule [12,17,21]. In a study by Popli MB et al., none of the hyperechoic nodules or nodules with predominant cystic component were malignant [13].

According to ACR TI-RADS 2017 [10], four descriptors are used for echogenicity of the nodule. Our study showed, adenomatous benign nodules to be either solid hyperechoic or mixed echogenicity with predominant hyperechoic solid component. Hypoechoic composition was more prevalent in malignant nodules which could be due to high cellularity of malignant nodules. According to literature upto 90% of papillary carcinomas appear hypoechoic. Medullary carcinoma and papillary carcinoma have similar sonological appearance. Metastasis to cervical nodes and local invasion are more frequent in medullary carcinoma [23].

In a study by Na DG et al., suspicious ultrasound features such as microcalcification, taller than wide shape, and spiculated/microlobulated margin, in the solid or hypoechoic nodule group, were independently predictive of malignancy. Whereas in the partially cystic nodule group only microcalcification was independently predictive of malignancy and in the iso and hyperechoic nodule group microcalcification and spiculated/microlobulated margin were independently predictive of malignancy. This implies that the hypoechoic descriptor of TI-RADS is more suspicious of a

malignant nodule compared to iso/hyperechoic or predominantly cystic nodule [21].

With respect to shape of the nodule in our study, wider than tall nodule was very specific descriptor for a malignant nodule. This is because the malignant nodules tend to grow perpendicular to the natural growth plane (which corresponds to width of the nodule on transverse scans) and in centrifugal pattern. This gives the nodule a greater anteroposterior diameter compared to transverse diameter with a taller than wide appearance on ultrasound [13]. Taller than wide nodules showed significant association with a malignant nodule according to studies by Kwak JY et al., Popli MB et al., as well as Chandramohan A et al., [12,13,17].

Margin represents the outline of thyroid nodule. The nodule margins have been defined as follows [22]: Smooth margin- clear demarcation of nodule to surrounding thyroid parenchyma, ill-defined margin- lack of clear demarcation of nodule to surrounding thyroid parenchyma, spiculated margin- ≥ 1 sharp angle or spiculation on the margin, Microlobulated- ≥ 1 smooth, focal, round protrusions on the margin of nodule. In our study, most of the benign nodules showed smooth surface. Kwak JY et al., Popli MB et al., Chandramohan A et al., Vinayak S and Sande J, observed that ill-defined/irregular margins or lobulated margins were more in favour of malignant nodule characteristic [12,13,17,24].

Microcalcification refers to calcifications < 1 mm, which are most often round in shape. It may have small comet tail artefacts [22]. Among the various calcifications in thyroid nodules, punctate echogenic foci/ microcalcifications was found to be more in favour of malignancy in our study. Of these, majority of the nodules (n=13) were proven to be papillary carcinoma, one of the nodules belonged to follicular carcinoma and medullary carcinoma each. However, three out of these seven nodules were falsely graded as malignant on TI-RADS but FNAC showed features of colloid goitre in two of them and one nodule was an adenomatous nodule. Misinterpretation of macrocalcification on ultrasound can lead to classifying the nodule as suspicious for malignancy and hence careful examination of each nodule to differentiate these features is important.

Macrocalcifications refer to calcifications > 1 mm, coarse and large calcifications with posterior acoustic shadowing [22]. In our study, majority of the nodules with macrocalcification were benign which belonged to multinodular goitre or adenomatous nodule category.

From our findings, authors found that adenomatous nodules are attributed higher grades on TI-RADS as well as Bethesda and may appear suspicious. This may be due to solid composition of the nodule and hyperechoic texture in which microcalcifications may be over diagnosed and wrongly interpreted. Kwak JY et al., and Popli MB et al., in their studies also suggested that microcalcifications were more in favour of malignant nodule [12,13].

In a study by Catal O et al., usefulness of ACR TI-RADS was assessed in a particular cytology category which was Atypia of Undetermined Significance (AUS) and Follicular Lesion of Uncertain Significance (FLUS). They concluded that TI-RADS was useful in predicting malignancy in this group and showed statistical significance. This can help to prevent unnecessary thyroidectomies [25].

A study by Chen F et al., which compared TI-RADS and American Thyroid Association (ATA) risk stratification systems for thyroid nodules concluded that the diagnostic accuracy of both the systems for thyroid nodule malignancy risk assessment was similar. This study used Receiver Operating Characteristic (ROC) analysis for statistical analysis and area under the curve was assessed for both the systems [26].

Nodule Characteristics not Included in ACR TI-RADS 2017

- Size of the nodule: In our study there was no significant association between size of the nodule and the nature of nodule

(benign or malignant). According to a study by Alexandrov YK et al., the size of the thyroid nodule is not of much value as an indication for FNAC or biopsy [27]. According to study by Xu T et al., thyroid nodule size had a marked influence on diagnostic performance of TI-RADS and ATA models for risk stratification of thyroid nodules. In larger nodules >20 mm, specificity of ATA was superior to TI-RADS whereas sensitivity of TI-RADS was better than ATA. The diagnostic value of TI-RADS was better for nodules between 10-20 mm size. However, in nodules <10 mm size both ATA and TI-RADS were less reliable [28].

- Vascularity of the nodule: The vascularity pattern in a thyroid nodule can be classified into three types [22]:

Type I: Absence of intranodular or perinodular flow

Type II: Presence of perinodular and/or slight intranodular flow

Type III: Presence of marked intranodular and slight perinodular flow

Among these patterns, malignant nodules usually demonstrate type III vascularity, whereas benign nodules demonstrate type I and II patterns. Increase in the size of benign nodule is associated with increase in intranodular signals [22].

Though vascularity is not one of the descriptors in ACR TI-RADS 2017 [10], we assessed the pattern of vascularity in thyroid nodules. In our study, majority of malignant nodules (88.9%) showed intrinsic vascularity. Among benign nodules, only 22% showed intrinsic vascularity and most of the benign nodules (51%) showed peripheral vascularity. Vinayak S and Sande JA in their study performed index scoring of nodules using four USG characteristics one of which was central vascularity which showed significant association with malignant nodules. Other features included in their study were nodule margin, calcification, and nodule echotexture [24]. Doppler criteria remain controversial as findings depend on the equipment and settings, hence, has not been used in many of the risk stratifications systems. In the presence of thick colloid, doppler can be used to differentiate it from a hypoechoic solid nodule [22]. Follicular carcinomas usually have irregular tumour margins and occasionally thick irregular halo. They may reveal tortuous/ chaotic internal blood vessels on doppler [23].

Risk of Malignancy Using TI-RADS

In our study, considering FNAC as gold standard the malignancy risk for TI-RADS 1 was 0%, TI-RADS 2 and 3 was 2.4 to 2.5%, TI-RADS 4 was 43% and TI-RADS 5 was 100%. Most of the studies on thyroid nodule risk stratification have shown a risk of malignancy of 0% for TI-RADS 2 category nodules [12,14,18]. However, in our study, two nodules which were categorised as TI-RADS 2, were suggestive of malignancy on FNAC. This finding, could be due to observer interpretation error in our study wherein, very fine microcalcifications might have been missed.

The statistical analysis of various studies based on risk stratification systems for thyroid nodules have been tabulated in chronological order in [Table/Fig-9]. ACR TI-RADS 2017 lexicon, TR levels, and criteria for further management have been tabulated in a chart in [Table/Fig-10].

Limitation(s)

The limitations of the study would be its small sample size. Greater sample size would enable more credible results which can be used for standardisation. Further inclusion of histopathology results of all nodules can help detect the sensitivity and specificity of the diagnostic criteria better. In this study, histopathology results were available for only 74 nodules. Use of advanced applications like elastography can provide additional information regarding the nature of nodule and help in better characterisation of nodules. Further research in this field is recommended.

CONCLUSION(S)

The risk stratification of thyroid nodules as benign or malignant using ACR TI-RADS 2017 criteria yielded good results in this study. There were only few discordances between TI-RADS and Bethesda groups and the diagnostic accuracy of the study was observed to be 87.43%. Though 100% sensitivity was not observed in our study for detecting benign nodules on USG, this could be due to operator dependence in sonogram. Hence nodules with mixed echogenicity and solid composition should be looked at carefully in detail so that minor details of microcalcifications are not missed. Use of ACR TI-RADS 2017 scoring system enables better risk stratification of nodules and can be used for deciding further management. The TI-RADS lexicon proposed by ACR 2017 can be universally used to assess thyroid nodules to create a uniform reporting system.

REFERENCES

- [1] Diagnostic Ultrasound. 5th ed. Carol M. Rumack, Deborah Levine. The Thyroid Gland. pp-691-93.
- [2] Tamhane S, Gharib H. Thyroid nodule update on diagnosis and management. Clin Diabetes Endocrinol. 2016;2:17.
- [3] Levine RA. Something old and something new: A brief history of thyroid ultrasound technology. Endocrine Practice. 2004;10(3):227-33.
- [4] Varma SR, Shayeb MA, Kaseh AE, Ashekhi A, Kuduruthullah S, Khader IE, et al. Incidental thyroid nodules an ultrasound screening of the neck region: Prevalence & risk factors. Clin Pract. 2018;15(5):873-79.
- [5] Balleyguier C, Ayadi S, Van Nguyen K, Vanel D, Dromain C, Sigal R. BIRADS classification in mammography. Eur J Radiol. 2007;61(2):192-94.
- [6] Rao AA, Feneis J, Lalonde C, Ojeda-Fournier H. A pictorial review of changes in the BI-RADS Fifth Edition. Radiographics. 2016;36(3):623-39.
- [7] Cibas ES, Ali SZ. The 2017 Bethesda system for reporting thyroid cytopathology. Thyroid. 2017;27(11):1341-46.
- [8] Biswas A, Basu K, De S, Karmakar S, De D, Sengupta M, et al. Correlation between thyroid imaging reporting and data system and bethesda system of reporting of thyroid cytopathology of thyroid nodule: A single center experience. J Cytol 2020;37:193-99.
- [9] Modi L, Sun W, Shafizadeh N, Negron R, Yee-Chang M, Zhou F, et al. Does a higher American College of Radiology Thyroid Imaging Reporting and Data System (ACR TI-RADS) score forecast an increased risk of malignancy? A correlation study of ACR TI-RADS with FNA cytology in the evaluation of thyroid nodules. Cancer Cytopathol. 2020;128(7):470-81.
- [10] Tessler FN, Middleton WD, Grant EG, Hoang JK, Berland LL, Teefey SA, et al. ACR Thyroid Imaging, Reporting and Data System (TI-RADS): White paper of the ACR TI-RADS committee. J Am Coll Radiol. 2017;14(5):587-95.
- [11] Vargas-uricochea H, Meza-cabrera I, Herrera-chaparro J. Concordance between the TIRADS ultrasound criteria and the BETHESDA cytology criteria on the nontoxic thyroid nodule. Thyroid Res. 2017;10:1.
- [12] Kwak JY, Han KH, Yoon JH, Moon JH, Son JE, Park SH, et al. Thyroid imaging reporting and data system for US features of nodules: A step in establishing better stratification of cancer risk. Radiology 2011;260(3):892-99.
- [13] Popli MB, Rastogi A, Bhalla PJS, Solanki Y. Utility of gray-scale ultrasound to differentiate benign from malignant thyroid nodules. Indian J Radiol Imaging 2012;22:63-68.
- [14] Horvath E, Majlis S, Rossi R, Franco C, Niedmann JP, Castro A, et al. An ultrasonogram reporting system for thyroid nodules stratifying cancer risk for clinical management. J Clin Endocrinol Metab. 2009;94(5):1748-51.
- [15] Russ G, Bigorgne C, Royer B, Rouxel A, Bienvenu-Perrard M. The Thyroid Imaging Reporting and Data System (TIRADS) for ultrasound of the thyroid. [Article in French] J Radiol. 2011;92(7-8):701-13.
- [16] Stoian D, Timar B, Derban M, Pantea S, Varcus F, Craina M, et al. Thyroid Imaging Reporting and Data System (TI-RADS): The impact of quantitative strain elastography for better stratification of cancer risks. Med Ultrason. 2015;17(3):327-32.
- [17] Chandramohan A, Khurana A, Pushpa BT, Manipadam MT, Naik D, Thomas N et al. Is TIRADS a practical and accurate system for use in daily clinical practice? Indian J Radiol Imaging. 2016;26(1):145-52.
- [18] Periakaruppan G, Seshadri KG, Vignesh Krishna GM, Mandava R, Sai VPM, Rajendiran S, et al. Correlation between ultrasound-based TIRADS and Bethesda system for reporting thyroid-cytopathology: 2-year experience at a tertiary care center in India. Indian J Endocrinol Metab. 2018;22(5):651-55.
- [19] Macedo BM, Izquierdo RF, Golbert L, Meyer ELS. Reliability of Thyroid Imaging Reporting and Data System (TI-RADS), and ultrasonographic classification of the American Thyroid Association (ATA) in differentiating benign from malignant thyroid nodules. Arch Endocrinol Metab. 2018;62(2):131-38.
- [20] Russ G, Leboulleux S, Leenhardt L, Hegedüs L. Thyroid incidentalomas: Epidemiology, risk stratification with ultrasound and workup. Eur Thyroid J. 2014;3(3):154-63.
- [21] Na DG, Baek JH, Sung JY, Kim JH, Kim JK, Choi YJ, et al. Thyroid imaging reporting and data system risk stratification of thyroid nodules: Categorization based on solidity and echogenicity. Thyroid. 2016;26(4):562-72.
- [22] Russ G, Bonnema SJ, Erdogan MF, Durante C, Ngu R, Leenhardt L. European Thyroid Association Guidelines for Ultrasound Malignancy Risk Stratification of Thyroid Nodules in Adults: The EU-TIRADS. Eur Thyroid J. 2017;6(5):225-37.

- [23] Patel SB, Shah SR, Goswami KG, Patel HB. Pictorial essays: Ultrasound features of thyroid and parathyroid lesions. *Ind J Radiolmag*. 2005(15)2:211-16.
- [24] Vinayak S, Sande JA. Avoiding unnecessary fine-needle aspiration cytology by accurately predicting the benign nature of thyroid nodules using ultrasound. *J Clin Imaging Sci*. 2012;2:23.
- [25] Catal O, Ozer B, Sit M, Yazgi H. Evaluation of the American College of Radiology Thyroid Imaging, Reporting and Data System (Thyroid imaging reporting) scoring in thyroid Bethesda category on atypia and follicular lesion of uncertain significance patients. *Rev Assoc Med Bras*. 2021;67(4):511-15.
- [26] Chen F, Sun Y, Chen G, Luo Y, Xue G, Luo K, et al. The Diagnostic Efficacy of the American College of Radiology (ACR) Thyroid Imaging Report and Data System (TI-RADS) and the American Thyroid Association (ATA) risk stratification systems for thyroid nodules. *Comput Math Methods Med*. 2022;2022:9995962.
- [27] Alexandrov YK, Sergeeva ED, Sencha AN. Restatement of indications for thyroid nodules biopsy. [Article in Russian] *VestnKhirlm I IGrek*. 2015;174(1):23-25.
- [28] Xu T, Gu JY, Ye XH, Xu SH, Wu Y, Shao XY, et al. Thyroid nodule sizes influence the diagnostic performance of TIRADS and ultrasound patterns of 2015 ATA guidelines: A multicenter retrospective study. *Sci Rep*. 2017;7:43183.

PARTICULARS OF CONTRIBUTORS:

1. Senior Resident, Department of Radiodiagnosis, Father Muller Medical College, Mangalore, Karnataka, India.
2. Professor, Department of Radiodiagnosis, Father Muller Medical College, Mangalore, Karnataka, India.
3. Professor, Department of Pathology, Father Muller Medical College, Mangalore, Karnataka, India.

NAME, ADDRESS, E-MAIL ID OF THE CORRESPONDING AUTHOR:

Rithi Melissa Dsilva,
1205, Abhiman Texas Apartment, Upper Bendur Road, Mangalore, Karnataka, India.
E-mail: rithi.dsilva@gmail.com

PLAGIARISM CHECKING METHODS: [Jain H et al.]

- Plagiarism X-checker: Feb 23, 2022
- Manual Googling: Jun 09, 2022
- iThenticate Software: Jun 20, 2022 (12%)

ETYMOLOGY: Author Origin**AUTHOR DECLARATION:**

- Financial or Other Competing Interests: None
- Was Ethics Committee Approval Obtained for this study? Yes
- Was informed consent obtained from the subjects involved in the study? Yes
- For any images presented appropriate consent has been obtained from the subjects. Yes

Date of Submission: **Feb 20, 2022**Date of Peer Review: **May 04, 2022**Date of Acceptance: **Jun 30, 2022**Date of Publishing: **Jan 01, 2023**