

# Case Report on Penetrating Right Renal Trauma caused by a Wooden Stick

AKASH RAJENDRAKUMAR PATEL<sup>1</sup>, JIGNESH DAVE<sup>2</sup>, JATIN BHATT<sup>3</sup>, DIVYAM GOEL<sup>4</sup>

(CC) BY-NC-ND

## ABSTRACT

Blunt trauma by motor vehicle accidents and falls, followed by penetrating injuries comprise the common mechanisms of renal injury. Unilateral Penetrating Renal Trauma (UPRT) is extremely rare. Here, we reported a unique case of Right Penetrating Renal Trauma (RPRT). A nine-year-old male child, with a 124 cm height and 30 kg weight without any medical history, had a history of falling down from tree with right side penetrating abdominal injury. On admission, patient was vitally stable. Patient had macroscopic haematuria with haemoglobin count of 10 gm/dL, creatinine 1.2 mg/dL. The Computed Tomography (CT) demonstrated right-sided penetrating renal injuries by some foreign material perinephric haematoma with surrounding air foci with renal vascular pedicle injury. An emergency exploratory laparotomy was executed immediately. According to the American Association for the Surgery of Trauma (AAST) organ injury scale grading system, it was considered grade IV renal injury. Nephrectomy was done. Piperacillin and tazobactam was injected to prevent bacterial infection. The postoperative course was uneventful. Patient was discharged after seven days without any complications.

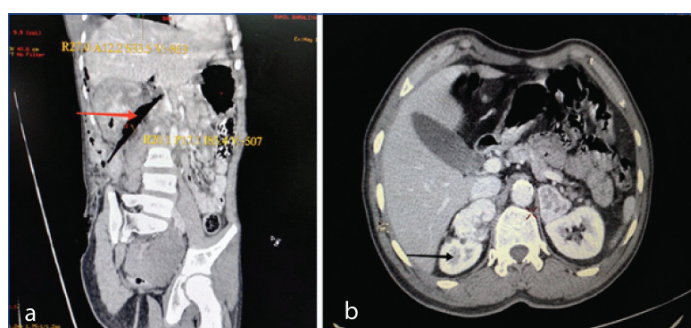
**Keywords:** American association for the surgery of trauma, Haematuria, Nephrectomy

## CASE REPORT

A nine-year-old male child was admitted in Emergency Department, with history of falling down from tree, with complaint of abdominal pain and wound over right flank region. His father gave history of penetrating injury from wood due to fall down from tree. There was no history of loss of consciousness, vomiting, ear and nasal bleeding and chest pain.

On physical examination, he was haemodynamically stable (blood pressure, 110/70 mmHg) and tachypnoeic (respiratory rate 26 times/minute). There was a solitary entry wound in right flank sized approximately 5×3 cm, elliptical in shape directed upward forward and medially. On palpation, sharp irregular object was found at the point of maximum depth. Urethral catheter was inserted and gross haematuria was observed.

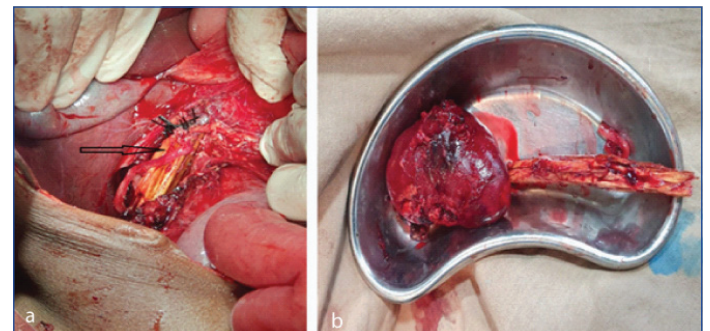
Laboratory tests revealed haemoglobin 10 gm/dL, creatinine 1.2 mg/dL. Chest and abdomen CT scan was performed, demonstrated right penetrating renal injuries by some foreign material with non-enhanced areas in right kidney with perinephric haematoma with surrounding air foci with no excretion of contrast on delayed one hour scan, corresponding to grade IV renal injury [Table/Fig-1a,b].



**[Table/Fig-1]:** a) Preoperative CT scan: foreign body (HU -507) (Red arrow) at the hilum of right kidney; b) Axial view showing non enhancing area with perinephric haematoma (Black arrow).

An emergency exploratory laparotomy was performed. A piece of wood was found penetrating right kidney and injuring right renal vein and abutting inferior vena cava. After clamping the right renal pedicle, the hilum was transected. The collecting system was seriously damaged and contaminated with extensive parenchymal and vascular injuries which were unreparable [Table/Fig-2a]. It was

considered a grade IV injury according to AAST [1] organ injury scale grading system. Right nephrectomy was done [Table/Fig-2b].



**[Table/Fig-2]:** Intra operative image: a) Damaged renal parenchyma and vascular pedicle with foreign body in situ. b) Nephrectomy specimen with foreign body (wooden stick).

Then abdominal cavity was explored and no intestinal injury was found. Intraperitoneal drainage tube was placed and the laceration of the right flank was repaired. During operation, two units of packed red-blood cells were transfused. Tetanus antitoxin was given as patient has not taken DPT vaccine at the age of five years. Piperacillin and tazobactam was injected to prevent bacterial infection. Two units whole blood was given intraoperatively. The patient was transferred to surgical intensive care unit for resuscitation.

The postoperative course was uneventful. There was approximately 1200 mL of urine for next 24 hours postoperatively. Serial haemoglobin and renal function were within normal limit. Seven days after surgery, patient recovered well and discharged with no complications. His discharge time blood pressure was 114/72 mmHg and creatine was 0.9 mg/dL.

## DISCUSSION

In every abdominal trauma, initial assessment including airway, breathing and circulation assessment is necessary. In case of haemodynamic instability and severe haemorrhage, immediate exploration should be done [2]. If patient is haemodynamically stable, thorough evaluation and imaging should be performed [3]. Patient history and injury mechanism are very important for making the right treatment decisions, especially in cases of solitary kidney. On physical examination any sign indicating renal trauma should

be noted, such as visible haematuria, rib fractures and flank/upper abdomen haematoma. Haematocrit and creatinine levels are necessary to evaluate current blood loss status and baseline renal function. Urine analysis should be done to diagnose microscopic haematuria.

The gold standard imaging for haemodynamically stable patients with penetrating renal trauma is intravenous contrast-medium enhanced CT. Computed Tomographies demonstrate contralateral kidney, grade the renal injury, while identifying associated injuries. For penetrating renal trauma patients, most frequent findings on CT are parenchymal disruption and perirenal haematoma [4]. Reimaging is recommended for patients with high-grade injuries two to four days later, and patients with clinical signs of deterioration or postoperative complications, such as fever, persistent haematuria, ongoing blood loss and abdominal distention [5].

Renal trauma is most commonly classified according to AAST grading system, which is based on the extent of damage to the renal parenchymal, collecting system, and/or renal vasculature [1]. It was reported to be significantly associated with the need for surgical intervention and the risk for nephrectomy [6]. Treatment options include conservative management, minimally invasive intervention, and open surgery [3]. Conservative management involves bed rest, analgesia, haemodynamic monitoring, serial laboratory evaluation and reimaging when there is any deterioration. Minimally invasive interventions are- angio embolisation, or placement of ureteral stent, perinephric drain and nephrostomy tube for urinary extravasation. Open surgeries were generally nephrectomy, partial nephrectomy, renorrhaphy, renal packing, or autotransplantation. Non operative management is currently the standard care for low-grade renal injuries, and also recommended for high-grade renal injuries in haemodynamically stable patients [7].

Patients with penetrating renal injuries were noted to have higher proportion of grade IV and V renal injuries, higher overall rate of concomitant injuries, angioembolisation and nephrectomy (27% vs 7% for blunt) [6,8]. Schechter SC et al., reported three cases, all of them were with unstable haemodynamics managed with immediate laparotomy [9]. Synchronous IV and V penetrating renal injuries, with stable retroperitoneal haematoma, were reported to be managed by the angioembolisation [10].

In this case, after contrast-enhanced CT scan, emergency laparotomy was done as foreign body must be taken out and the right kidney was seriously damaged. Renal exploration was done via a transperitoneal approach with early control of renal pedicle, and retroperitoneal evaluation was done. Nephrectomy was performed. Close monitoring was imperative after the surgery. Postoperative hospital stay should be at least one week, since non negligible complications such as arterial pseudoaneurysms or arteriovenous fistula may occur six to eight days after penetrating renal injury [11].

## CONCLUSION(S)

Penetrating renal injury is rare and challenging case which requires urgent evaluation of patient, CT scan abdomen to know extent and severity of disease and urgent surgical intervention which may include nephrectomy or renorrhaphy.

## REFERENCES

- [1] Moore EE, Shackford SR, Pachter HL, McAninch JW, Browner BD, Champion HR, et al. Organ injury scaling: Spleen, liver, and kidney. *J Trauma*. 1989;29(12):1664-66.
- [2] Colaco M, Navarrete RA, MacDonald SM, Stitzel JD, Terlecki RP. Nationwide procedural trends for renal trauma management. *Ann Surg*. 2019;269(2):367-69.
- [3] Erlich T, Kitrey ND. Renal trauma: The current best practice. *Ther Adv Urol*. 2018;10(10):295-303.
- [4] Alonzo RC, Nacenta SB, Martinez PD, Guerrero AS, Fuentes CG. Kidney in danger: CT findings of blunt and penetrating renal trauma; *RadioGraphics*. 2009;29(7):2033-53.
- [5] Kitrey ND, Djakovic N, Gonsalves M, Kuehas FE, Lumen N, Serafetinidis E, et al. EAU guidelines on urological trauma. XXX 2017;8-17 ISBN 978-94-92671-14-1. <http://uroweb.org/guidelines/compilations-of-all-guidelines/>.
- [6] Keihani S, Xu Y, Presson AP, Hotaling JM, Nirula R, Piotrowski J, et al. Contemporary management of highgrade renal trauma: Results from the American Association for the Surgery of Trauma Genitourinary Trauma study. *J Trauma Acute Care Surg*. 2018;84(3):418-25.
- [7] Mingoli A, La Torre M, Migliori E, Cirillo B, Zamboni M, Sapienza P, et al. Operative and nonoperative management for renal trauma: Comparison of outcomes. A systematic review and meta analysis. *Ther Clin Risk Manag*. 2017;13:1127-38. Doi: 10.2147/TCRM.S139194.
- [8] Mann U, Zemp L, Rourke KF. Contemporary management of renal trauma in Canada: A 10-year experience at a level 1 trauma centre. *Can Urol Assoc J*. 2019;13(6):E177-82.
- [9] Schechter SC, Schechter WP, McAninch JW. Penetrating bilateral renal injuries: Principles of management. *J Trauma*. 2009;67(2):E25-28.
- [10] Yeung L, Brandes S. The ultimate in genitourinary damage control: Minimally invasive management of synchronous grade 4 and 5 bilateral penetrating renal injuries. *J Trauma*. 2011;70(5):1299. Doi: 10.1097/TA.0b013e3181f8f8b2.
- [11] Hadjipavlou M, Grouse E, Gray R, Sri D, Huang D, Brown C, et al. Managing penetrating renal trauma: Experience from two major trauma centres in the UK. *BJU Int*. 2018;121(6):928-34. Doi: 10.1111/bju.14165. Epub 2018 Mar 13.

### PARTICULARS OF CONTRIBUTORS:

1. Junior Resident, Department of General Surgery, PDU Medical College and Hospital, Rajkot, Surat, Gujarat, India.
2. General Surgeon, Department of General Surgery, PDU Medical College and Hospital, Rajkot, Gujarat, India.
3. General Surgeon, Department of General Surgery, PDU Medical College and Hospital, Rajkot, Gujarat, India.
4. Junior Resident, Department of General Surgery, PDU Medical College and Hospital, Rajkot, Gujarat, India.

### NAME, ADDRESS, E-MAIL ID OF THE CORRESPONDING AUTHOR:

Dr. Akash Rajendrakumar Patel,  
60, Shantivan Society, Opp. Gail Tower, Anand Mahal Road, Surat, Gujarat, India.  
E-mail: akp1711@yahoo.com

### AUTHOR DECLARATION:

- Financial or Other Competing Interests: None
- Was informed consent obtained from the subjects involved in the study? Yes
- For any images presented appropriate consent has been obtained from the subjects. Yes

### PLAGIARISM CHECKING METHODS: [Jain H et al.]

- Plagiarism X-checker: May 10, 2021
- Manual Googling: Jul 08, 2021
- iThenticate Software: Aug 19, 2021 (17%)

### ETYMOLOGY: Author Origin

Date of Submission: **May 08, 2021**  
Date of Peer Review: **Jun 10, 2021**  
Date of Acceptance: **Jul 18, 2021**  
Date of Publishing: **Oct 01, 2021**