

Study of the Accessory Mandibular Foramina in Dry Adult Human Mandibles and their Clinical and Surgical Implications

PRATIK N MISTRY¹, JABA RAJGURU², MITESH R DAVE³



ABSTRACT

Introduction: Accessory Mandibular Foramina (AMF) are most commonly located around the mandibular foramen in the ramus of the mandible. They may transmit the branches of the inferior alveolar nerve and vessels, which may lead to the failure to achieve the inferior alveolar nerve block during various dental procedures.

Aim: To evaluate the incidence, the site/location and the number of the AMF in the dry adult human mandibles.

Materials and Methods: This was a cross-sectional study. A total of 140 dry adult human mandibles were studied in Parul Institute of Medical Sciences and Research, Parul University, Vadodara for the presence of the AMF with respect to their incidence, number, site/location around the mandibular foramen from December 2018 to July 2020. The findings were recorded, tabulated, analysed and stated using descriptive statistics.

Results: The AMF were present in 44 (31.42%) out of 140 dry human mandibles. In 26 (18.57%) mandibles, they were present bilaterally and in 18 (12.85%) mandibles they were present unilaterally; eight (5.71%) on the right side while 10 (7.14%) on the left side. In 62 (77.5%) left and right sides of the mandibles, they were present above the mandibular foramen while in 18 (22.5%) left and right sides, they were present below the mandibular foramen.

A single AMF was present in 66 (82.5%) left and right sides of the mandibles. Two foramina were present in the 12 (15%) left and right sides of the mandible. Triple foramina were observed in the two (2.5%) sides of the mandibles.

Conclusion: Knowledge of the presence of the AMF can help to prevent the neurovascular complications during various procedures involving mandibular ramus.

Keywords: Foramen, Incidence, Inferior alveolar nerve, Lower Jaw

INTRODUCTION

The mandible is the largest, strongest and the only movable bone of the facial skeleton. It consists of a body and a pair of rami. The body is 'U' shaped and two halves of it are united anteriorly in the midline forming symphysis menti. Ramus is the quadrilateral plate of the bone extending upwards from the posterior aspect of the body [1,2]. The mandibular foramen is present on the medial surface of the ramus of the mandible. It is oval or at times, irregular [3] in shape and anteromedial margin of it is guarded by the thin, sharp, triangular tongue like projection called as the lingula which provide attachment to the lower end of the speno-mandibular ligament from the spine of sphenoid in the base of the skull [1-3]. Mandibular canal which extends downwards and forwards from the mandibular foramen within the ramus and body of the mandible, transmit the inferior alveolar nerve and vessels; the former is a branch of the posterior division of the mandibular nerve and the latter is the branch of 1st part of maxillary artery and vein being the tributary of the maxillary vein [1,2]. Inferior alveolar nerve supplies the molar and pre-molar teeth and is divided into mental and incisive branches; the latter one supplies the canine and incisor teeth [1-3].

There are several variations which are encountered in the anatomy of the inferior alveolar nerve within the canal. The inferior alveolar nerve may constitute a single trunk or may be divided into two unequal branches; the larger branch often emerges through the mental foramen whereas the smaller one after supplying the molar and pre-molar teeth continues as the incisive nerve. The inferior alveolar nerve may also give separate branches for the molar, pre-molar, canine and incisor teeth as well as for the mental foramen near its entry into the mandibular foramen [4]. The inferior alveolar nerves and vessels provide somatic sensations and vascular supply to the teeth of the lower jaw, dental papilla and periodontal ligaments as well as alveolar osseous tissue [5]. The mandibular foramen is an

important anatomical and surgical landmark for the maxillofacial surgeon to give the inferior alveolar nerve block for procedures like extraction of the third molar or wisdom teeth, dental implants, sagittal split osteotomies for correction or reposition of the mandible in prognathism and retrognathia [6]. The complications which may occur during these techniques are somatosensory impairment during and after surgery, haemorrhage, injury to the neurovascular bundle, undesired fractures and bone necrosis because of improper inferior alveolar block [5]. Failure rates are high because of the inaccurate localisation [6-8] and the presence of the accessory foramina around the mandibular foramen transmitting the branches of the inferior alveolar nerve [6,9].

Any opening in the mandible other than mandibular foramen, sockets of teeth, mental foramen and lingual foramen are described as AMF [5,6,9-11] or Conduct of Serres [9]. The AMF are observed commonly on the medial surface of ramus of mandible above or below the mandibular foramen [9,12,13]. The AMF usually leads to the accessory mandibular canal which may permit the branches of nerve and vessels related to the mandible i.e., the inferior alveolar nerve, inferior alveolar vessels, facial nerve, mylohyoid nerve, buccal nerve and transverse cervical cutaneous nerve [1,10,11,14]. It may result in failure of the inferior alveolar nerve block when the anatomical variations of this nerve passes through these foramina and provide additional supply to the teeth of the lower jaw [9]. The rupture of the accessory vessels contained in them, may result in difficulty in controlling intra-osseous haemorrhage [9]. The AMF also provide an easy route for the spread of infection and tumour cells after radiotherapy [10,12,13,15]. Accessory foramina and overlying periosteum may directly communicate with the cancellous bone of the mandible. This may play an important role in bone invasion of the medial surface of the mandible especially in the irradiated ones. This can be attributed to the fact that radiotherapy decreases the

ability of the periosteum to act as a barrier in the spread of a tumour [5]. The anatomical presence of the AMF may permit the unusual passage of nerves and vessels of the lower jaw and the neighbouring region; they are therefore clinically significant in dentistry, surgical, anaesthetic and clinical procedures.

Therefore, the present study was conducted with the objectives to evaluate the incidence, the site/location, whether unilateral and/or bilateral and the number of the AMF in dry adult human mandibles.

MATERIALS AND METHODS

This cross-sectional observational study was carried out after obtaining permission from the Institutional Ethical Committee (PU-IECHR/Letter/Approval/2020-2021/09), in Parul Institute of Medical Sciences and Research, Parul University, Vadodara from December 2018 to July 2020.

For estimation of sample size, the incidence of the previously conducted studies was enumerated and the median incidence was computed which was 32%. Now utilising the same as the incidence in the formula for sample size (n); $n = z^2pq/d^2$ where (z = value of standard normal deviate at 95 % confidence interval which is 1.98, p = prevalence/incidence, q = 100 – p, d = maximum allowable error which is 5%) which equals $(1.98)^2 \times 32 \times 68/25 = 344.67$ which is almost equal to 345. Due to limitation of number of dry specimens available in the department and stated time duration, it was decided to study 40% of this sample size for the current study. This came to 138 and was rounded off at 140 dry adult human mandibles.

The specimens were numbered accordingly and were examined for the presence of the AMF. A magnifying glass was used to have a clear view of the foramina as and when necessary. A simple/ordinary flexible steel wire of 1-2 mm diameter was used to check its patency and presence of the accessory mandibular canal.

Inclusion criteria: Dry adult mandibles with socket for third molar teeth irrespective of age and sex and accessory foramina present on the ramus which formed accessory mandibular canal.

Exclusion criteria: Dry adult mandibles having marked deformities, asymmetry and fracture or presence of blind foramina present on the ramus i.e., which did not form or lead to accessory mandibular canal.

Incidence of the AMF, unilateral or bilateral presence, site/location of the AMF with respect to the mandibular foramen (whether above or below the mandibular foramen). number of the AMF (whether above or below the mandibular foramen) on either side of mandible were studied for all the specimens.

STATISTICAL ANALYSIS

Photographs were taken. The findings were recorded, tabulated, analysed and stated using descriptive statistics.

RESULTS

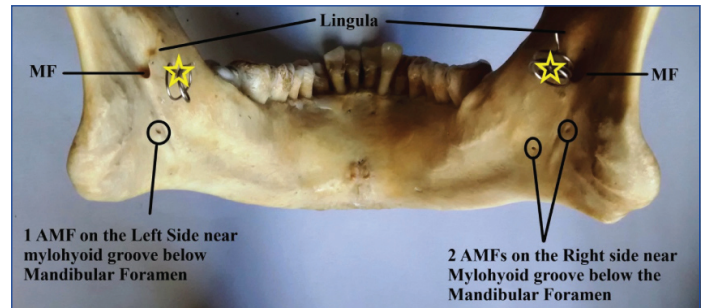
AMF were present in 44 (31.42%) mandibles out of 140 dry specimens. Out of these, 26 (18.57%) mandibles were having the bilateral presence of AMF and in 18 (12.85%) they were present unilaterally. Their distribution is shown in [Table/Fig-1,2]. The position and number of the AMF with respect to the mandibular foramen is depicted in [Table/Fig-3,4].

DISCUSSION

Restoration of form and functions without violating the important anatomical structure is a fundamental goal in the surgical management of the patient. The anatomical presence and position of the accessory mandibular foramina should be considered because it may result in clinical complications if not properly identified [12]. The presence of the accessory mandibular foramina

Presence of accessory mandibular foramina		Number of mandibles	Percentage (%)
Bilaterally present		26	18.57 %
Unilaterally present	Right	8	5.71 %
	Left	10	7.14 %
Absent		96	68.57 %

[Table/Fig-1]: Incidence of the Accessory Mandibular Foramina (AMF) in dry adult human mandibles.



[Table/Fig-2]: Bilateral presence of the Accessory Mandibular Foramina (AMF) below the mandibular foramen near mylohyoid groove.

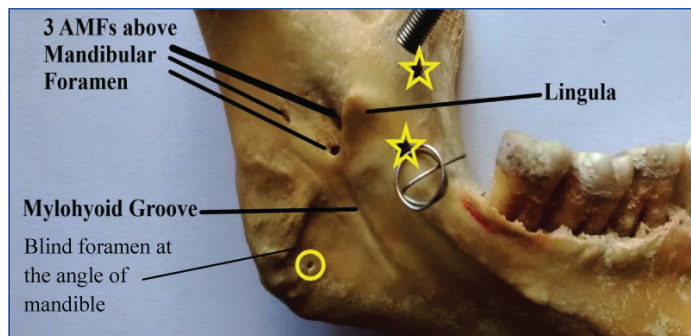
AMF: Accessory Mandibular Foramina, MF: Mandibular Foramen, * show an spring and artificial foramen drilled for passage of spring which could not be removed without causing damage to the specimen

may lead to the unusual course of the nerves and blood vessels, thereby making it difficult to anaesthetise the inferior alveolar nerve during various dental procedures like extraction of the lower third molar teeth, flap lifting, autologous bone grafting, division of the mandibular ramus in the sagittal split osteotomy, etc., [7,13]. Because of the presence of the accessory mandibular canal, it may lead to inadequate anaesthesia during the inferior alveolar nerve block [8,16]. Hence, it is obvious that the knowledge of the presence of the accessory mandibular foramina is important for achieving successful inferior alveolar nerve block. Gow-Gates technique is recommended by the authors where anaesthesia can be given at the level of the neck of mandible into the trunk of the mandibular nerve before its bifurcation into two divisions in order to achieve the desired goal [5,16]. In a study it, was found that the neurovascular bundle passing through AMFs supplied the root of the third molar tooth [7,16]. In another study, there were presence of accessory mandibular foramina in 300 human mandibles both internally and externally, which were traversed by additional sensory fibers from the facial nerve and the mylohyoid nerve [12,15]. Galdames IC et al., reported 100 % presence of the accessory mandibular foramina in the age group of 0 to 2 years [14]. They were present mainly behind the mandibular foramen and led to a canal, directed anteroinferiorly and is known as Conduct of Serres [14]. Presence of the accessory mandibular foramina in the fetuses have been reported and these foramina are connected with the mandibular canal [9,13]. The comparison in the findings of various authors is tabulated in [Table/Fig-5] [5-21].

The occurrence of the accessory mandibular foramina may be due to the developmental remodelling processes, starting from the medial surface of the mandible in the Meckel's cartilage [9]. Variation in the number and the presence of the accessory mandibular foramina can be due to the fact that in the early embryogenesis, three different, inferior alveolar nerves supply the anterior teeth group (incisor and canine), pre-molar and molar teeth separately. Due to the rapid prenatal growth and remodelling in the mandibular ramus, there is a spread of intramembranous ossification that eventually forms the single mandibular canal and gradually these three inferior alveolar nerves get fused to form a single trunk of inferior alveolar nerve which then enters through mandibular foramen. The incomplete fusion of these three nerves leads to the development of double or triple accessory mandibular canals which may lead to damage of branches of the inferior alveolar nerve and vessels passing through them and produce various complications like haemorrhage, paraesthesia, bone

Site of accessory mandibular foramina in relation to mandibular foramen	Numbers of specimens (n=140)						Total
	One		Two		Three		
	Right	Left	Right	Left	Right	Left	
Above mandibular foramen	26 (32.5%)	27 (33.75)	3 (3.75%)	4 (5%)	1 (1.25%)	1 (1.25%)	62 (77.5%)
Below mandibular foramen	6 (7.5%)	7 (8.75%)	4 (5%)	1 (1.25%)	0	0	18 (22.5%)
Total	32 (40%)	34 (42.5%)	7 (8.75%)	5 (6.25%)	1 (1.25%)	1 (1.25%)	80

[Table/Fig-3]: Site/location and number of the accessory mandibular foramina on the medial surface of ramus around the mandibular foramen.



[Table/Fig-4]: Three accessory mandibular foramina present above the mandibular foramen.

AMF: Accessory mandibular foramina; *: show an spring and artificial foramen drilled for passage of spring which could not be removed without causing damage to the specimen; o: is blind foramen at the angle of mandible which is not leading to the accessory mandibular canal; Hence, not considered as AMF

necrosis and fracture [5-7,9,12,13,15,18,19]. Several researchers have stated that the entire inferior alveolar nerve passes through the mandibular canal in only 60% of the cases [7,9,13,16]. The accessory mandibular foramina so formed relate to the blood supply during the development of primary dentition, which gradually disappears after the birth [12]. In adults, when these canals remain, it is considered as an anatomical variation [12]. Number and distribution of the accessory mandibular foramina on the medial surface of the mandible are important, because they provide a direct route into the cancellous bone and may facilitate the perineural spread of the tumours from the floor of the mouth, and this knowledge is of utmost significance for the radiologist planning for the radiotherapy [5,12,13,15,16]. Chances of spread of the malignancy is higher in the irradiated mandibles in cases of presence of the accessory foramina as it directly communicates with the cancellous bone [5]. Detection of the presence of accessory mandibular foramina in regular skiagrams may be difficult due to their

Authors	No of Mandibles	Presence of AMF (%)	AMF present bilaterally (%)	AMF present unilaterally (Right + Left) (%)	Number of accessory mandibular foramina (AMFs) in relation to the mandibular foramen (MF) (%)					
					One		Two		Three	
					Above MF (R+L)	Below MF (R+L)	Above MF (R+L)	Below MF (R+L)	Above MF (R+L)	Below MF (R+L)
Nayak G et al., (2019) [5]	30	20	13.33	6.67	-	-	-	-	-	-
Pal A et al., (2018) [6]	160	-	-	-	37.5 + 31.25		2.5 + 5		6.25 + 0	
Patra S et al., (2015) [7]	160	73.7	41.8	31.9 (19.4+12.5)	69.3 33+36.3	117.7+3.3	17.6 6.6+11	-	2.2 1.1+1.1	-
Samanta PP & Kharb P (2013) [8]	60	16.66	-	-	10		6.66		-	-
Goyal N et al., (2017) [9]	100	39	12	26	-	-	-	-	1	
Shalini R et al., (2016) [10]	204	32.35	10.3	22.06 (12.25+9.81)	(8.33+ 5.4)		(3.92+ 4.41)		-	-
Mathur S & Joshi P (2018) [11]	100	25	4	21	19		6 (4+2)		-	-
Freire AR et al., (2012) [12]	222	43.24 above MF 27.9 below MF	18.02 above MF 5.85 below MF	25.22 above MF 22.07 below MF	49.55 (21.62+27.93)	32.89 (17.12+15.77)	9.45 (5.40+4.05)	0.45 (0+0.45)	1.35 (0.45+0.9)	-
Gupta S et al., (2013) [13]	50	48	18	30 (22+8)	-	-	-	-	-	-
Galdames IC et al., (2009) [14]	256	42.6	19.1	23.4 (11.3+12.1)	-	-	-	-	-	-
Singh A et al., (2014) [15]	28	39.28	21.43	17.86	21.43 + 28.57		3.57 + 3.57		3.57 + 0	
Murli Manju BV et al., (2011) [16]	67	16.4	7.5	8.9 (4.45+4.45)	13.43		2.99		-	-
Narayana K & Prashanthi N (2003) [17]	335	0.3	-	-	-	-	-	-	-	-
Padmavathi G et al., (2014) [18]	65	41.5	12.3	29.2 (12.3+16.9)	-	-	-	-	-	-
Raghavendra VP & Benjamin W (2015) [19]	100	9	-	-	6		3		-	-
Gopalakrishna K et al., (2016) [20]	100	18	-	-	-	-	-	-	-	-
Sultana Q et al., (2016) [21]	100	-	13	47 (24+23)	-	-	-	-	-	-
Present study	140	31.42	18.57	12.85 (5.7+7.14)	66.25 (32.5+33.75)	16.25 (7.5+8.75)	8.7 (3.75+5)	6.25 (5+1.25)	2.5 (1.25+1.25)	-

[Table/Fig-5]: Comparisons of studies by various authors [5-21].

AMF: Accessory mandibular foramina; MF: Mandibular foramen; R: Right; L: Left

minute size. Routine radiographic interpretations may be misleading at times due to resultant distortion or overlapping which create a false interpretation of the anatomical structures [22]. Though Cone Beam Computed Tomography (CBCT) is a better technique, the higher cost and high levels of radiation exposure associated with CBCT has limited its usage in routine clinical practice [22,23]. Knowledge of the presence of the accessory mandibular foramina during various dental procedures and also for the orthodontic and anthropological evaluation of normal and pathological mandibles is therefore very essential.

Limitation(s)

Since this study was done on isolated specimens of dry adult human mandibles, clinical correlation of the presence of the accessory mandibular foramina with presenting signs and symptoms could not be ascertained. Secondly, actual anatomical configuration of nerves and blood vessels passing through these foramina is more of a gesticulation in the present scenario.

CONCLUSION(S)

The present study shows that the presence of accessory mandibular foramina is significant enough to consider them in the planning and execution of the various dental procedures by maxillofacial surgeons, oncologists and radiologists, especially during the inferior alveolar nerve block. By identifying these anatomical variations; the complications like pain, haemorrhage, numbness, discomfort, and paraesthesia can be prevented significantly. The authors recommend further studies to be conducted with larger sample size taking the above mentioned parameters into consideration. Further, this study can be conducted with the help of the radiological interventions like CBCT and/or 3-D scan of the mandible in live volunteers especially in those undergoing dental procedures of the lower jaw requiring anaesthesia of the inferior alveolar nerve, in order to ascertain the incidence of accessory mandibular foramina and further correlate the signs and symptoms arising because of them.

REFERENCES

- [1] Standing S. Gray's Anatomy. Anatomical basis of Clinical Practice: Infratemporal and pterygopalatine fossae and temporomandibular joint. 41st ed. London: Elsevier Churchill Livingstone, 2016;537-47
- [2] Datta AK. Essentials of Human Anatomy: Head and Neck. 5th Ed. Kolkata: Current Books International, 2010; 40-44.
- [3] Yu SK, Kim S, Kang SG, Kim JH, Lim KO, Hwang SI, et al. Morphological assessment of the anterior loop of the mandibular canal in Koreans. *Anat Cell Bio.* 2015;48(1):75-80.
- [4] Rodella LF, Buffoli B, Labanca M, Rezzani R. A review of the mandibular and maxillary nerve supplies and their clinical relevance. *Arch Oral Biol.* 2012;57(4):323-34.
- [5] Nayak G, Sahoo N, Panda S. Accessory mandibular foramina and bifid mandibular canals-an anatomical study. *Eur J Anat.* 2019;23(4):261-66.
- [6] Pal A, Mandal T, Ghosal AK. Mandibular accessory mandibular foramen-an anatomical study in dry adult human mandibles of eastern India. *Ind J Basic Applied Med Res.* 2018;8(1):7-12.
- [7] Patra S, Nayak S, Pradhan S, Bara D, Mohapatra C. Incidence and localisation of accessory mandibular foramen in east Indian population-a single centre experience. *Indi J Applied Res.* 2015;5(7):664-66.
- [8] Samanta PP, Kharb P. Morphometric analysis of mandibular foramen and incidence of accessory mandibular foramina in adult human mandibles of an Indian population. *Revista Argentina de Anatomía Clínica.* 2013;5(2):60-66.
- [9] Goyal N, Sharma M, Miglani R, Garg A, Gupta PK. Clinical significance of accessory foramina in adult human mandible. *Int J Res Med Sci.* 2017;5(6):2449-53.
- [10] Shalini R, RaviVarman C, Manoranjitham R, Veeramuthu M. Morphometric study on mandibular foramen and incidence of accessory mandibular foramen in mandibles of south Indian population and its clinical implications in inferior alveolar nerve block. *Anat Cell Bio.* 2016;49(4):241-48.
- [11] Mathur S, Joshi P. A Study of incidence of accessory mandibular foramina in dry human mandibles of Rajasthan state. *Inter J Res Review.* 2018;5(8):1-6.
- [12] Freire AR, Rossi AC, Prado FB, Caria PH, Botacin PR. Incidence of the mandibular accessory foramina in Brazilian population. *J Morphol Sci.* 2012;29(3):171-73.
- [13] Gupta S, Soni A, Singh P. Morphological study of accessory foramina in mandible and its clinical implication. *Ind J Oral Sci.* 2013;4(1):12-16.
- [14] Galdames IC, Matamala DA, Smith RL. Is the conduct of Serres an anatomical variation in adults? *Int J Morphol.* 2009;27(1):43-47.
- [15] Singh A, Zaidi SHH, Gupta R. A study of accessory mandibular foramina in north Indian mandibles. *Inter J Rec Trends Sci Tech.* 2014;13(2):448-51.
- [16] Murlimanju BV, Prabhu LV, Prameela MD, Ashraf CM, Krishnamurthy A, Kumar CG. Accessory mandibular foramina: prevalence, embryological basis and surgical implications. *J of Clin Diagnostic Res.* 2012;5(6):1137-39.
- [17] Narayana K, Prashanthi N. Incidence of large accessory mandibular foramen in human mandibles. *Eur J Anat.* 2003;7(3):139-42.
- [18] Padmavathi G, Tiwari S, Varalakshmi KL, Roopashree R. An anatomical study of mandibular and accessory mandibular foramen in dry adult human mandibles of south Indian origin. *IOSR J Dent Med Sci.* 2014;13:83-88.
- [19] Raghavendra VP, Benjamin W. Position of mandibular foramen and incidence of accessory mandibular foramen in dry mandibles. *Int J Pharm Bio Sci.* 2015;6(1):282-88.
- [20] Gopalakrishna K, Deepalaxmi S, Somashekara SC, Rathna BS. An anatomical study on the position of mandibular foramen in 100 dry mandibles. *Int J Anat Res.* 2016;4(1):1967-71. <https://www.ijmhr.org/ijar.4.1/IJAR.2016.122.pdf>
- [21] Sultana Q, Shariff MH, Avadhani R. Study of surgical landmarks of mandibular foramen for inferior alveolar nerve block: An Osteological study. *Ind J Clin Anat Physio.* 2016;3(1):37-40.
- [22] Pancer B, Garaicoa-Pazmiño C, Bashutski JD. Accessory mandibular foramen during dental implant placement: case report and review of literature. *Implant Dentistry.* 2014;23(2):116-24.
- [23] Haas LF, Dutra K, Porporatti AL, Mezzomo LA, De Luca Canto G, Flores-Mir C, et al. Anatomical variations of mandibular canal detected by panoramic radiography and CT: a systematic review and meta-analysis. *Dentomaxillofacial Radio.* 2016;45(2):20150310.

PARTICULARS OF CONTRIBUTORS:

1. Assistant Professor, Department of Anatomy, Parul Institute of Medical Sciences and Research, Vadodara, Gujarat, India.
2. Professor, Department of Anatomy, Parul Institute of Medical Sciences and Research, Vadodara, Gujarat, India.
3. Professor and Head, Department of Anatomy, Parul Institute of Medical Sciences and Research, Vadodara, Gujarat, India.

NAME, ADDRESS, E-MAIL ID OF THE CORRESPONDING AUTHOR:

Jaba Rajguru,
G3 Shapath Residency Karamsad Vidyanagar Road Anand, Anand, Gujarat, India.
E-mail: hibiscusemily@yahoo.com

AUTHOR DECLARATION:

- Financial or Other Competing Interests: None
- Was Ethics Committee Approval obtained for this study? Yes
- Was informed consent obtained from the subjects involved in the study? NA
- For any images presented appropriate consent has been obtained from the subjects. NA

PLAGIARISM CHECKING METHODS: [Jain H et al.]

- Plagiarism X-checker: Jul 15, 2020
- Manual Googling: Oct 23, 2020
- iThenticate Software: Dec 23, 2020 (15%)

ETYMOLOGY: Author Origin

Date of Submission: Jul 14, 2020
Date of Peer Review: Sep 17, 2020
Date of Acceptance: Nov 05, 2020
Date of Publishing: Jan 01, 2021