

Laparoscopy Assisted Percutaneous Nephrolithotomy in Patients with Ectopic Pelvic Kidneys: Experience in 24 Patients

SACHIN PATIL¹, ASHISH YEVALE², NITIN PINGALE³, DEVENDRA KUMAR JAIN⁴

ABSTRACT

Introduction: Pelvic ectopic kidney with stones is relatively uncommon urological abnormality. Limited literature is available for surgical management of such cases. Because of abnormal anatomy, endoscopic surgery can be a challenging task.

Aim: To evaluate the safety and efficacy of laparoscopy assisted Percutaneous Nephrolithotomy (PCNL) in patients with pelvic ectopic kidneys with nephrolithiasis.

Materials and Methods: This was a retrospective study conducted from May 2015 to July 2019. All patients with pelvic ectopic kidneys with nephrolithiasis were screened and patients who underwent laparoscopy assisted PCNL were enrolled. The variables studied were age, sex, side of the pelvic kidney, stone size, tract size, duration of surgery, duration of nephrostomy tube, duration of abdominal drain and duration of hospital stay. Complications reported or observed during intraoperative or postoperative period were also noted. Descriptive statistics was used.

Results: The mean age of the patient was 36.5 ± 9.3 (Mean \pm SD) years. Fifteen patients were males and nine were females. The mean size of stone was 17.9 ± 3.2 (Mean \pm SD) mm and in 17 (70.8%) patients, stone was located on right side. The mean tract size was 23.1 ± 1.2 (Mean \pm SD) French and the mean duration of surgery was 127.8 ± 12.5 (Mean \pm SD) minutes. The stone clearance rate was 100%. The mean duration of nephrostomy tube, abdominal drain, and hospital stay was 2.2 ± 0.4 (Mean \pm SD) days, 3.5 ± 0.8 (Mean \pm SD) days, and 3.8 ± 1.0 (Mean \pm SD) days, respectively. Two patients reported complications (ileus and fever).

Conclusion: In patients with pelvic ectopic kidney with stones laparoscopy assisted PCNL is safe and effective procedure. Further prospective, randomised studies with large sample size are required to clearly establish the role of laparoscopy assisted PCNL.

Keywords: Anomalous kidney, Calculus, Kidney stone

INTRODUCTION

A pelvic ectopic kidney is one of the common congenital urological abnormalities reported worldwide with a prevalence of 1 in 2200 to 3000 births [1]. Nephrolithiasis in patients with pelvic ectopic kidney is relatively uncommon. Several anatomic and metabolic factors may play a significant role in the development of calculi in ectopic kidneys [2]. Anatomical abnormalities like different kidney location, anomalous blood supply and the altered ureteral course may increase complexity and challenges in the management of nephrolithiasis [3,4].

Various options have been explored till date for the management of nephrolithiasis like open renal surgery, Extracorporeal Shock Wave Lithotripsy (ESWL), PCNL, Retrograde Intrarenal Surgery (RIRS) each having its own limitations [5-7]. Generally, PCNL is the preferred treatment option in orthotopic kidneys with nephrolithiasis with large stones (especially >1.5 cm) [8]. The stone clearance of PCNL in the ectopic kidney is also better than ESWL [9,10]. Laparoscopy assisted PCNL in pelvic ectopic kidney was first described by Eshghi AM et al., [11]. However, there is limited literature available on the use of laparoscopy assisted PCNL in these unusual pelvic ectopic kidney stones. Most of the available studies are in the form of case study or small case series [12-18]. This paper reports the safety and efficacy of laparoscopy assisted PCNL in ectopic kidneys with nephrolithiasis.

MATERIALS AND METHODS

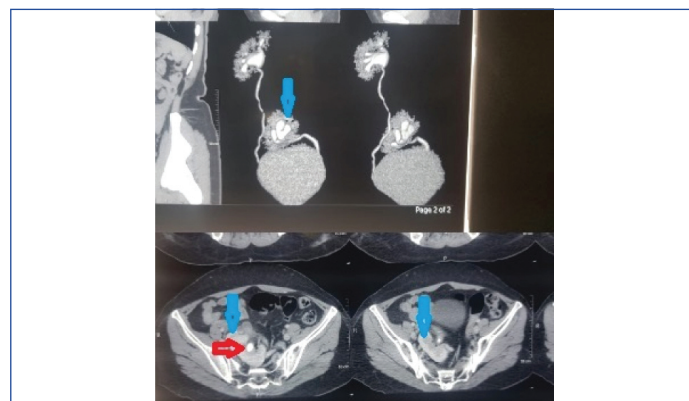
This was a retrospective, descriptive, observational study conducted at the Department of Urology, Bharati Hospital, Pune, Maharashtra, India, from May 2015 to July 2019. Ethical committee approval was taken (IEC approval number –BVDUMC/IEC/116). All patients with pelvic ectopic kidneys with nephrolithiasis were screened. Details of disease and treatment were noted from the hospital database. A total of 42

patients of pelvic kidney with nephrolithiasis were screened. A total of 24 patients underwent laparoscopy assisted PCNL. Nine patients underwent RIRS, seven patients underwent ESWL and two patients underwent open surgery. Of these only those patients who underwent laparoscopy assisted PCNL were enrolled for further study.

Inclusion criteria: Patients with ectopic pelvic kidney with nephrolithiasis with stone size more than 1 cm.

Exclusion criteria: Patients with ectopic pelvic kidney with nephrolithiasis with stone size less than 1 cm, patients with bleeding diathesis or patients who were unfit for surgery were excluded from study.

As a part of routine care, all the patients were evaluated including detailed medical history, clinical examination, routine haematological and urine investigations. Additionally, all the patients underwent Ultrasonography (USG) of Kidney, Ureter and Bladder (KUB) and Computed Tomography (CT) urography [Table/Fig-1].

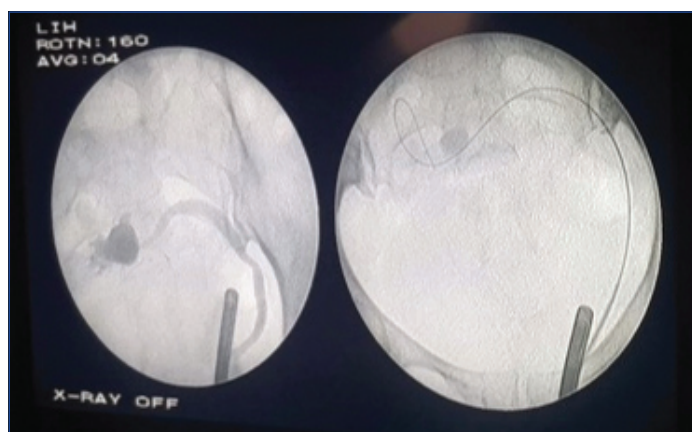


[Table/Fig-1]: Computed tomography (CT) urography showing left ectopic kidney (blue arrow) with stone in renal pelvis (red arrow).

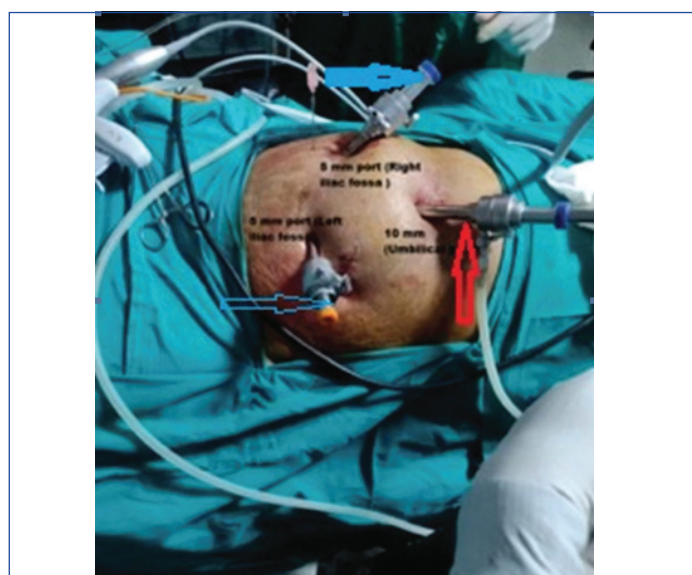For the purpose of this study following details were collected from hospital data base: age, sex, side of the pelvic kidney, stone size, tract size, duration of surgery, duration of nephrostomy tube, duration of abdominal drain and duration of hospital stay. Complications reported or observed during intraoperative or postoperative period were also noted.

General Surgical Procedure in Included Patients

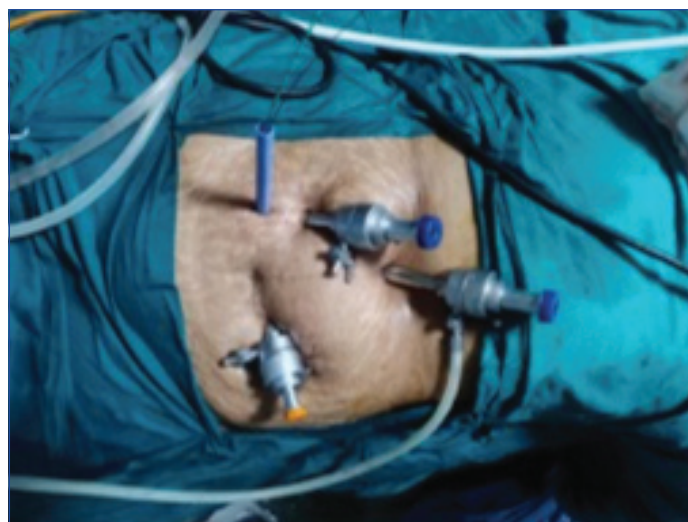After general anaesthesia, 6Fr ureteral catheter was placed in lithotomy position. Retrograde pyelogram was then performed to know the location of the kidney [Table/Fig-2]. A 10 mm umbilical port was inserted first for telescope followed by two 5mm working ports in both iliac regions [Table/Fig-3]. Reflection of the colon was then carried out to assess the anatomy of the kidney, blood vessels and ureter. The abdominal pressure was then reduced. The desired calyceal puncture (Transperitoneal percutaneous) was done after contrast pyelogram using 18G initial puncture needle. The 0.035-inch guide wire was then inserted and the tract was dilated using Alken's serial metal dilators. The tract was dilated up to 22Fr to 26Fr depending on the dilatation of the pelvicalyceal system and size of the stone. Amplatz sheath of appropriate size was then inserted [Table/Fig-4]. Dresden nephroscope was then used for nephroscopy. Stones were fragmented using pneumatic lithoclast and fragments were retrieved using forceps. At the end of procedure Double J stent was placed in antegrade manner, nephrostomy tube was placed transperitoneally and then abdominal drain was placed. Postoperative X-ray KUB was done to assess stone clearance [Table/Fig-5]. Nephrostomy tube was removed first followed by foley catheter. The abdominal drain was removed once drain output dropped to less than 50 mL in 24 hour. Double J stent was removed after four weeks.



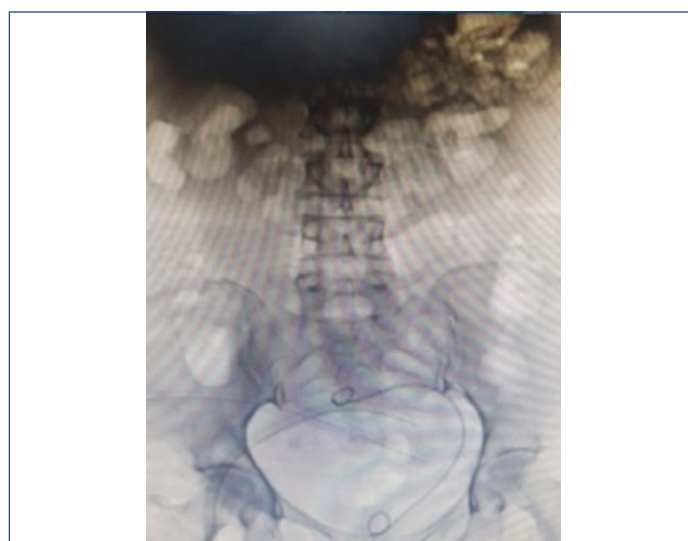[Table/Fig-2]: Retrograde pyelogram.



[Table/Fig-3]: Port position (Thick blue arrow- 5mm port in right iliac fossa; Thin blue arrow- 5 mm port in left iliac fossa; Red arrow- 10 mm umbilical port).



[Table/Fig-4]: Amplatz sheath in place.



[Table/Fig-5]: Postoperative X-ray KUB.

STATISTICAL ANALYSIS

Analysis was done in Statistical Package for the Social Sciences (SPSS) version 25. Descriptive statistics were used to describe the data. Mean and the standard deviation were used for quantitative variables. Frequency and percentage were used for qualitative variables.

RESULTS

The mean age of the patient was 36.5 ± 9.3 (Mean \pm SD). In 70.8% of patients stone was located on the right side and in 29.2% of patients it was on the left side. The mean size of stone was 17.9 ± 3.2 (Mean \pm SD) [Table/Fig-6].

Characteristic	n=24
Age (years)	36.5 \pm 9.3 (Mean \pm SD)
Sex	Male-15 (62.5%)
	Female-9 (37.5%)
Side	Right- 17 (70.8%)
	Left- 7 (29.2%)
Stone size (mm)	17.9 \pm 3.2 (Mean \pm SD)

[Table/Fig-6]: Demographic and preoperative details.

The mean tract size was 23.1 ± 1.2 (Mean \pm SD) French and the mean duration of surgery was 127.8 ± 12.5 (Mean \pm SD) minutes. Overall, the stone clearance rate was 100%. The mean duration of nephrostomy tube, abdominal drain, and hospital stay was 2.2 ± 0.4 (Mean \pm SD) days, 3.5 ± 0.8 (Mean \pm SD) days, and 3.8 ± 1.0 (Mean \pm SD) days, respectively [Table/Fig-7].

Characteristic	Mean±SD (n=24)
Tract size (french)	23.1±1.2
Duration of surgery (minutes)	127.8±12.5
Nephrostomy tube duration (days)	2.2±0.4
Abdominal drain duration (days)	3.5±0.8
Hospital stay (days)	3.8±1.0
Complications	n = 2 (ileus and fever)

[Table/Fig-7]: Intraoperative and postoperative details.

Out of 24 patients, two patients reported complications. One patient had ileus (Clavien-Dindo Classification Grade1) [19] and was treated conservatively with fluid and electrolyte management. Another patient had fever (Clavien-Dindo Classification Grade 2) in the postoperative period which was managed with antibiotics according to urine culture sensitivity.

DISCUSSION

In the present study, the safety and efficacy of laparoscopy-assisted PCNL was evaluated in ectopic kidneys with nephrolithiasis. Results from present study demonstrated that laparoscopy-assisted PCNL is safe procedure with 100% stone clearance rate. The present study was a retrospective evaluation of 24 cases demonstrating clinical benefits and adding data to the literature. Also, our technique of reducing intra-abdominal pressure during tract dilatation and nephroscopy will encourage surgeons to do this procedure with standard amplatz sheaths which are 17 cm in length without any requirement of extra-long amplatz sheaths (which are 22 cm in length). Comparison of study results against published literature is seen in [Table/Fig-8] [12-14].

Patwardhan SK et al., studied outcomes of laparoscopy assisted PCNL in three patients with ectopic pelvic kidney with chronic renal disease [12]. Duration of nephrostomy tube and duration of abdominal drain was more compared to present study. All three patients in their study developed paralytic ileus whereas in present study only one patient developed paralytic ileus. They found significant peri-nephrostomy leakage of urine in peritoneal cavity in all patients leading to prolonged duration of nephrostomy tube and ultimately prolonged duration of drain. Urine leak in peritoneal cavity also resulted in paralytic ileus in all three patients. Authors attributed prolonged drain output and paralytic ileus to impaired wound healing in patients with chronic kidney disease. None of the patient in present study had deranged renal function. This can explain differences observed in both studies.

D'Souza N et al., studied outcomes of laparoscopy assisted mini PCNL in patients of ectopic pelvic kidney [13]. As they performed mini PCNL, tract size was smaller (15 fr). They performed tubeless procedure (no nephrostomy tube) except in one patient. They did not observe paralytic ileus in any of their patient. As tract size is small in mini PCNL, chances of urine leak and ultimately chances of developing paralytic ileus were very less. This was probably the reason that they did not experience any complications related to urinary leakage despite doing tubeless procedures. In present study, there was only one patient who had paralytic ileus. Nephrostomy and abdominal drain was used in all patients. This resulted in very low incidence of paralytic ileus in present study. Stone clearance was less in the study conducted by D'Souza N et al., compared to present study. This is possibly because one of their patients had

large stone burden with stones in inaccessible calyx. They had to do re look PCNL through same nephrostomy tract using flexible nephroscope. In present study, patients had with stones in renal pelvis only. As we used larger tract, big stones could be removed in single sitting.

Mousavi-Bahar SH et al., studied outcomes of laparoscopy assisted PCNL in patients of ectopic pelvic kidney [14]. Their results were comparable to present study. They had only three patients in their study whereas we studied 24 patients adding more weightage to present study. Soylemez H et al., assessed outcomes of different techniques while doing laparoscopy assisted PCNL in patients with pelvic ectopic kidney [6]. They employed two different laparoscopic techniques like mesocolon dissection and transmesocolic, and few different percutaneous procedures such as standard-PCNL, mini-PCNL and micro-PCNL. In contrast to this study, same technique was used in present study while doing laparoscopy and percutaneous stone removal for all patients. Hence, direct comparison and interpretation was not justified. But in their study they concluded that laparoscopy assisted PCNL is safe and effective for stones in ectopic pelvic kidneys. Ugurlu IM et al., studied outcomes of RIRS for stones in patients with ectopic kidneys. They found it to be technically difficult due to malrotation of the pelvicalyceal system, tortuous high insertion of the ureter and large stone bulk [7].

This study will act as guide for urologists at least for initial few cases in their practice. Incidence of stone in ectopic pelvic kidney is low. Most urologists are not expert in handling such cases immediately after their training. We have clearly described our technique with photographs showing position of abdominal ports and amplatz sheath. This will help in allaying apprehension of performing procedure. Also, routine use of nephrostomy and abdominal drain will help in reducing complications like ileus.

Limitation(s)

This was a retrospective study which has its inborn limitations. As the present series has limited sample size, care must be taken while generalising the results. However, this study adds data to the literature on this unusual occurrence.

CONCLUSION(S)

Laparoscopic assisted PCNL is safe and has excellent results in patients with stones in ectopic pelvic kidney. It helps in achieving good stone clearance with minimum morbidity. Prospective, randomised studies with large sample size are required to clearly establish the role of laparoscopy assisted PCNL in management of stones in ectopic kidneys.

REFERENCES

- [1] Zafar FS, Lingeman JS. Value of laparoscopy in the management of calculi complicating renal malformations. *J Endourol.* 1996;10:379-83.
- [2] Cinman NM, Okeke Z, Smith AD. Pelvic kidney: Associated diseases and treatment. *J Endourol.* 2007;21:836-42.
- [3] Maheshwari PN, Bhandarkar DS, Andankar MG, Shah RS. Laparoscopically guided transperitoneal percutaneous nephrolithotomy for calculi in pelvic ectopic kidneys. *Surg Endosc.* 2004;18:1151.
- [4] Matlaga BR, Kim SC, Watkins SL, Kuo RL, Munch LC, Lingeman JE. Percutaneous nephrolithotomy for ectopic kidneys: Over, around, or through. *Urology.* 2006;67:513-17.
- [5] Paterson RF, Lifshitz DA, Kuo RL, Siqueira TM, Jr, Lingeman JE. Shock wave lithotripsy monotherapy for renal calculi. *J Urol.* 2002;28:291-301.

Study	Stone size (mm)	Tract size (Fr)	Duration of surgery (minutes)	Nephrostomy tube duration (days)	Duration of drain (days)	Complications	Stone clearance
Patwardhan SK et al., [12]	40	28.6	119	4.6	6.6	Paralytic ileus in 3 patients	100%
D'Souza N et al., [13]	18	15	90	Tubeless (except 1 patient)	No drain	Residual stones requiring relook	88.9%
Mousavi-Bahar SH et al., [14]	30	28	126.67	2	3.6	Urine leakage 1 patient	100%
Present study	17.9	23.9	127.84	2.2	3.54	Ileus fever	100%

[Table/Fig-8]: Published literature where PCNL was done for stones in pelvic ectopic kidneys [12-14].

- [6] Soylemez H, Penbegül N, Utangac MM, Dede O, Çakmakçı S, Hatipoglu NK. Laparoscopy assisted percutaneous stone surgery can be performed in multiple ways for pelvic ectopic kidneys. *Urolithiasis*. 2016;4(4):345-52.
- [7] Ugurlu IM, Akman T, Binbay M, Tekinarslan E, Yazici Ö, Akbulut MF, et al. Outcomes of retrograde flexible ureteroscopy and laser lithotripsy for stone disease in patients with anomalous kidneys. *Urolithiasis*. 2015;43:77-82.
- [8] Ramakumar S, Segura JW. Renal calculi. Percutaneous management. *Urol Clin North Am*. 2000;27(4):617-22.
- [9] Marcovich R, Smith AD. Renal pelvic stones: Choosing shock wave lithotripsy or percutaneous nephrolithotomy. *Int Braz J Urol*. 2003;29(3):195-207.
- [10] ElSheemy MS, Daw K, Habib E, Aboulela W, Fathy H, Shouman AM, et al. Lower calyceal and renal pelvic stones in preschool children: A comparative study of mini-percutaneous nephrolithotomy versus extracorporeal shockwave lithotripsy. *Int J Urol*. 2016;23(7):564-70.
- [11] Eshghi AM, Roth JS, Smith AD. Percutaneous transperitoneal approach to a pelvic kidney for endourological removal of staghorn calculus. *J Urol*. 1985;134:525-27.
- [12] Patwardhan SK, Shelke UR, Patil BP, Pamecha YR. Laparoscopic assisted percutaneous nephrolithotomy in chronic kidney disease patients with ectopic pelvic kidney. *Urol Ann*. 2017;9(3):257-60.
- [13] D'souza N, Verma A, Rai A. Laparoscopic-assisted mini percutaneous nephrolithotomy in the ectopic pelvic kidney: Outcomes with the laser dusting technique. *Urol Ann*. 2016;8(1):87-90.
- [14] Mousavi-Bahar SH, Amir-Zargar MA, Gholamrezaie HR. Laparoscopic assisted percutaneous nephrolithotomy in ectopic pelvic kidneys. *Int J Urol*. 2008;15(3):276-78.
- [15] Resorlu B, Karakan T, Kilinc MF, Kabar M, Doluoglu OG. Laparoscopic-assisted percutaneous nephrolithotomy in malrotated and ectopic pelvic kidneys: calyceal or direct pelvic access? *Ren Fail*. 2015;37(4):742-43.
- [16] Prakash G, Sinha RJ, Jhanwar A, Bansal A, Singh V. Outcome of percutaneous nephrolithotomy in anomalous kidney: Is it different? *Urol Ann*. 2017;9(1):23-26.
- [17] Goel R, Yadav R, Gupta NP, Aron M. Laparoscopic assisted Percutaneous Nephrolithotomy (PCNL) in ectopic kidneys: Two different techniques. *Int Urol Nephrol*. 2006;38(1):75-78.
- [18] Aquil S, Rana M, Zaidi Z. Laparoscopic assisted Percutaneous Nephrolithotomy (PCNL) in ectopic pelvic kidney. *J Pak Med Assoc*. 2006;56(8):381-83.
- [19] Dindo D, Demartines N, Clavien PA. Classification of surgical complications: A new proposal with evaluation in a cohort of 6336 patients and results of a survey. *Ann Surg*. 2004;240:205-13.

PARTICULARS OF CONTRIBUTORS:

1. Assistant Professor, Department of Urology, Bharati Vidyapeeth University Medical College and Hospital, Pune, Maharashtra, India.
2. Senior Resident, Department of Urology, Bharati Vidyapeeth University Medical College and Hospital, Pune, Maharashtra, India.
3. Senior Resident, Department of Urology, Bharati Vidyapeeth University Medical College and Hospital, Pune, Maharashtra, India.
4. Professor and Head, Department of Urology, Bharati Vidyapeeth University Medical College and Hospital, Pune, Maharashtra, India.

NAME, ADDRESS, E-MAIL ID OF THE CORRESPONDING AUTHOR:

Dr. Sachin Patil,
Department of Urology, Bharati Vidyapeeth University Medical College and Hospital, Dhankawadi, Pune-411043, Maharashtra, India.
E-mail: drsachin.uro@gmail.com

PLAGIARISM CHECKING METHODS: [Jain H et al.]

- Plagiarism X-checker: Sep 07, 2020
- Manual Googling: Oct 08, 2020
- iThenticate Software: Dec 23, 2020 (9%)

ETYMOLOGY: Author Origin**AUTHOR DECLARATION:**

- Financial or Other Competing Interests: None
- Was Ethics Committee Approval obtained for this study? Yes
- Was informed consent obtained from the subjects involved in the study? Yes
- For any images presented appropriate consent has been obtained from the subjects. Yes

Date of Submission: **Aug 28, 2020**Date of Peer Review: **Sep 24, 2020**Date of Acceptance: **Oct 08, 2020**Date of Publishing: **Jan 01, 2021**