

Evaluation of Coccyx Variability using Multislice Computed Tomography- A Cross-sectional Study

SR RAGHU¹, K SHANKARA², T SACHIN³, BR SHASHIKIRAN⁴



ABSTRACT

Introduction: Coccyx is the terminal vestigial segment of human spine. There is a lack of data on the structure of coccyx causing hindrance in the treatment aspect of coccydynia.

Aim: To determine type of coccyx, number of coccygeal segments, prevalence of sacrococcygeal, intercoccygeal fusion and coccygeal spicule of human adult coccyx using pelvic Computed Tomography (CT) scans.

Materials and Methods: A cross-sectional study of 49 adult patients who underwent CT scans for benign clinical conditions like ureteric colic, abdominal pain evaluation in Hassan Institute of Medical Sciences, Hassan, Karnataka, India. The coccyx bone was evaluated for number of segments, sacrococcygeal and intercoccygeal fusion and prevalence of spicules and configured as types I-IV according to Postacchini F and

Massobrio M classification. Chi-square test was used to find association of the type of coccyx with age and gender.

Results: Type I coccyx (32, 65.3%) was the most common type followed by type II (9, 18.3%). Majority had four coccygeal segments (39, 79.6%). The sacrococcygeal fusion was seen in 13 (26.5%) and intercoccygeal fusion was observed in 41 (83.7%) patients. Coccygeal spicule was seen in 21 (42.9%) subjects. The tip of coccyx was retroverted in only 3 (6.1%) patients. The terminal coccygeal segment showed ventral angulation in 8 (16.3%) cases.

Conclusion: In present study, Type I coccyx was most common with four coccygeal segments. Intercoccygeal fusion was more commonly seen than sacrococcygeal fusion. Comprehension of in vivo structure of coccyx through CT scans will help in care of patients with coccydynia.

Keywords: Coccyx anatomy, Morphology, Sagittal computed tomography

INTRODUCTION

The coccyx is the terminal segment of human vertebrae [1]. It is also referred as the tailbone. It is considered the vestigial part of human spine [2]. The term coccyx has its origin from a Greek word for cuckoo because of its resemblance to the bird's curved beak appearance [3]. The structure of coccyx acts as an attachment site for various muscles and ligaments that forms the perineal floor [4]. The coccyx comprises of 3-5 individual vertebrae and four segments in majority of the population [5]. The first coccygeal bone is usually the largest and articulates with the distal part of the sacral vertebra or becomes fused in few people [6]. There are very few studies on the human adult coccyx morphology and morphometry in vivo, much of the data is obtained from disarticulated skeleton [3,4,7]. This paucity of information is of value not only for academic research purpose but also to know the aetiology of idiopathic coccydynia. Development of pain around coccyx is referred as coccydynia or coccygodynia [8]. Postacchini F and Massobrio M radiologic classification has divided coccyx into four types: Type 1: slight curve forward with its apex directed downward and caudally; Type 2: marked forward curve and forward-pointing apex; Type 3: sharp forward angle between first and second segment of coccyx; Type 4: anterior subluxation of one or more segments [6].

In this study, the aim was to determine the type of coccyx, number of coccygeal segments, prevalence of sacrococcygeal, intercoccygeal fusion and coccygeal spicule of human adult coccyx in vivo using pelvic CT scans.

MATERIALS AND METHODS

This was a cross-sectional study in which 49 adult patients underwent CT scans in the Department of Radiology, Hassan Institute of Medical Sciences, Hassan, Karnataka, India for other benign clinical indications like ureteric colic, abdominal pain evaluation. The CT scans were acquired between the duration January 2020 to April 2020 were

studied. Approval for the research was granted by the Institutional Ethical Committee (IEC/HIMS/RR65/21-05-2019). The pelvic CT scans of the adult patients routinely done for non-orthopaedic indications like ureteric colic, abdominal pain evaluation in supine position was included in the study. CT scans done for other than pelvic region, with a history of surgery and pelvic mass causing distortion was excluded. Philips 16 slice CT scanner was used for obtaining the scans. The coccyx bone was evaluated and configured as types I-IV according to Postacchini F and Massobrio M classification [6]. Also, number of coccygeal segments, sacrococcygeal and intercoccygeal joint fusion, coccygeal spicules were assessed by viewing sagittal images in Multi Slice Computed Tomography (MSCT).

STATISTICAL ANALYSIS

Evaluation copy of statistical software such as SPSS 17/Systat was used for statistical analysis. Categorical variables were associated using Chi-square test. A p-value <0.05 was considered statistically significant.

RESULTS

In this study, 49 patients including 26 (53.1%) males and 23 (46.9%) females. The average age of the subjects was 46 years (ranging between 20-70 years) with SD value of 16.5. The most common type of coccyx observed was type I (32, 65.3%), followed by type II (9, 18.3%). Types III and IV were 7 (14.3%) and 1 (2%) respectively. The relation between coccyx type and gender was not significant with p-value 0.088 using chi-square test [Table/Fig-1]. Type I coccyx was seen most commonly in the age group 45-60 years. The relation between coccyx type and age group was not significant with p value of 0.92 through Chi-square test [Table/Fig-2,3].

The number of coccygeal vertebral segments i.e., 4 were observed in (39, 79.6%), 3 were seen in (9, 18.4%) and 2 in (1, 2%) [Table/Fig-4]. The sacrococcygeal fusion was seen in 13 (26.5%) and intercoccygeal

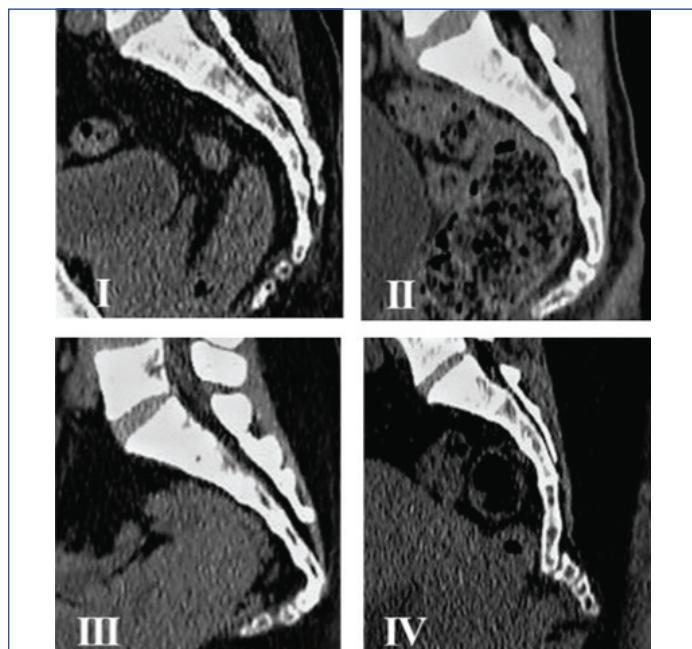
fusion was observed in 41 (83.7%) patients [Table/Fig-5,6]. Coccygeal spicule was seen in 21 (42.9%) subjects [Table/Fig-7]. The tip of coccyx was retroverted in only 3 (6.1%) patients [Table/Fig-8]. The terminal sacral segment showed ventral angulation in 8 (16.3%) cases [Table/Fig-9]. The relation of age group with sacrococcygeal fusion and intercoccygeal fusion was not significant with p-value of 0.47 and 0.84, respectively. The relation of gender with prevalence of sacrococcygeal fusion, intercoccygeal fusion and coccygeal spicule was not significant with p-value of 0.47, 0.55 and 0.50, respectively.

	Type of coccyx				Total
	I	II	III	IV	
Female	13	3	6	1	23
Male	19	6	1	0	26

[Table/Fig-1]: Relation of gender with type of coccyx.

Age group (years)	Type I	Type II	Type III	Type IV	Total
<30	8	3	2	0	13
31-45	8	1	1	1	11
46-60	11	3	1	0	15
>60	5	2	3	0	10
Total	32	9	7	1	49

[Table/Fig-2]: Relation of age group with type of coccyx.



[Table/Fig-3]: Sagittal section of CT images showing coccyx types.

	Number of coccyx segments				Total
	1	2	3	4	
Female	0	1	4	18	23
Male	0	0	5	21	26

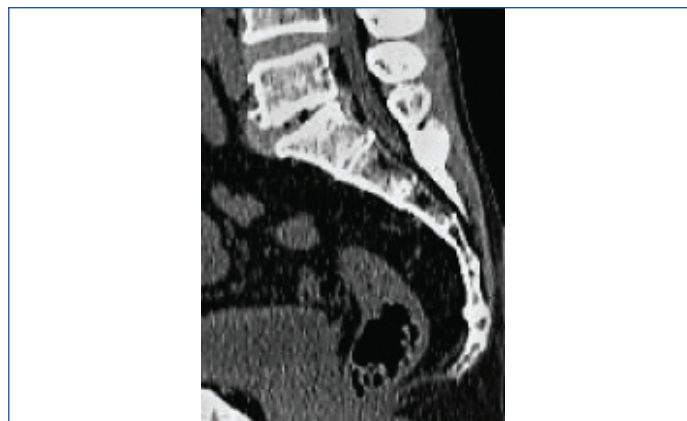[Table/Fig-4]: Relation of gender with number of coccygeal segments.

Age group (years)	Sacrococcygeal fusion	Intercoccygeal fusion
<30	2	11
31-45	2	10
46-60	5	12
>60	4	8
Total	13	41

[Table/Fig-5]: Relation of age with sacrococcygeal and intercoccygeal fusion.

DISCUSSION

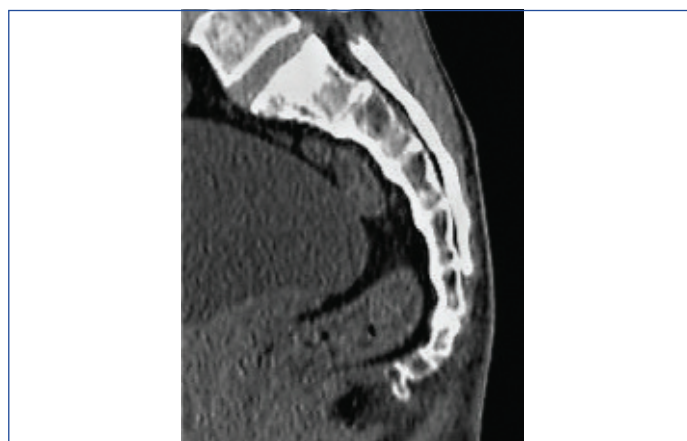It is essential to comprehend the variations in the anatomy of the coccyx to understand the aetiology of coccydynia. The research articles have been increased in recent times with new advances in radiological



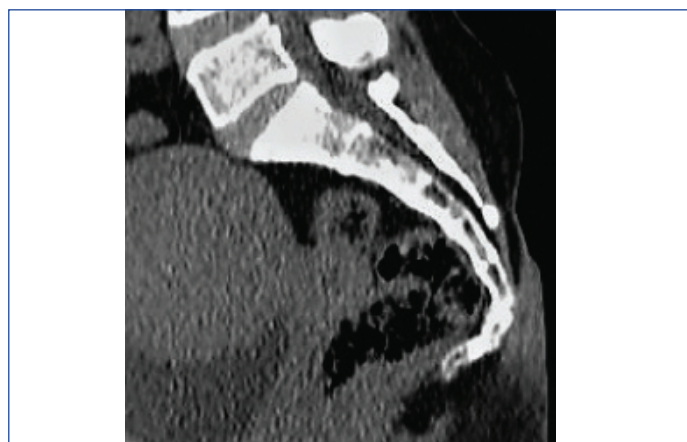
[Table/Fig-6]: Sagittal section of CT image showing sacrococcygeal and intercoccygeal fusion.

Type of coccyx	Intercoccygeal fusion			Sacrococcygeal fusion			Spicules		
	Male	Female	Total	Male	Female	Total	Male	Female	Total
1	15	13	28	5	3	8	7	9	16
2	5	3	8	2	0	2	2	1	3
3	1	3	4	1	1	2	1	1	2
4	0	1	1	0	1	1	0	0	0
Total	21	20	41	8	5	13	10	11	21

[Table/Fig-7]: Gender wise distribution of intercoccygeal, sacrococcygeal fusion and spicules in different types.



[Table/Fig-8]: Sagittal section of CT image showing retroverted tip of coccyx.



[Table/Fig-9]: Sagittal section of CT image showing ventral angulation of terminal sacral segment.

imaging techniques. In present study, the normal adult coccygeal structure and measurements through MSCT were investigated.

The results of present study showed that type I was the most common type of coccyx followed by type II, according to Postacchini F and Massobrio M classification. This observation was in consonance with Indiran V et al., and Tetiker et al., (43.6%) studies [1,9]. The same was noted in few more studies by Woon JT et al., (64%)

Shalaby S et al., (41%), [Table/Fig-10] [3,4] and Kerimoglu U et al. [10]. This finding can be attributed to the common custom of sitting on the floor in these population. But Karayol SS et al., and Yoon MG et al., studied that type II was seen in majority of the people i.e., 45.4% and 51%, respectively [2,8]. Przybylski P et al., also found that type II was the most common type followed by type III in a study done in Polish population [11].

	Indiran V et al., [1]	Shalaby S et al., [4]	Woon JT et al., [3]	Yoon MG et al., [8]	Current study
Type of coccyx	Type I (43.6%)	Type I (41%)	Type I (64%)	Type II (51%)	Type I (65.3%)
Coccyx segments	4 (64.3%)	3 (68.3%)	4 (76%)	4 (64.8%)	4 (79.6%)
Sacrococcygeal fusion	43.66%	-	57%	33.4%	26.5%
Intercoccygeal fusion	90.6%	-	89%	-	83.7%
Coccyx spicule	8.45%	-	23%	-	42.9%

[Table/Fig-10]: Comparison of current study with other studies [1,3,4,8].

In the current study, majority had four coccygeal segments. Similarly, Woon JTK et al., reported four vertebrae being present in most individuals (76%) [3], as was the case with Indiran V et al., (64.3%) and Karayol SS et al., (54.2%) [1,2]. A study on Korean population by Yoon MG et al., also remarked the same with 64.8% of the public had four segments comparable to Europeans [8,12]. However, Shalaby S et al., and Przybylski P et al., studies were in discordance with present study [4,11]. In these analyses done on Egyptian and Polish population independently three segments were found in the maximum subjects. The most frequent number of coccygeal vertebral segments of Arabs also was three [13].

The frequency of sacrococcygeal fusion in the present study was in concurrence with the study by Yoon MG et al., (33.4%) [8]. There was no significant relationship between the sacrococcygeal fusion and gender in present study. No difference was found between males and females in the prevalence of sacrococcygeal fusion by Tague RG [14]. The presence of fusion in sacrococcygeal joint was noted to be more frequent with increasing age (>45 years) in the current study analogous to Yoon MG et al., and Tague RG [8,14]. Sacrococcygeal joint fusion was predominantly seen in type I coccyx (61.5%) in present study, in contrast to the study by Indiran V et al., where it was seen most commonly in type II and least commonly in type I coccyxes [Table/Fig-3].

Intercoccygeal fusion was present in 83.7% of the cases, in concurrence with Indiran V et al., (90.6%) and Woon JT et al., (89%) [1,3]. The relationship of intercoccygeal fusion with age and sex displayed no significance. Alike sacrococcygeal fusion, intercoccygeal fusion was chiefly observed in type I coccyx (68.3%) in the present study. This was discordant with Indiran V et al., study as intercoccygeal fusion was the most common in type II coccyxes, followed by type I [1].

In present study, coccygeal spicule was seen in 42.9% with equal distribution between men and women and with preponderance in type I coccyx. Coccygeal spicules of 23% prevalence were reported by Woon JTK et al., [3] and 8.4% by Indiran V et al., [1] which was low in comparison with present study.

In summary, there are a few differences and similarities between numerous ethnicities and our Indian population. In present study, Type I coccyx was common as in other Asian studies. The number of coccygeal vertebrae was similar to Korean and European studies as were the prevalence of sacrococcygeal and intercoccygeal fusion. Further detailed studies can be profitable to relate coccygeal morphology and coccydynia.

Limitation(s)

One of the main limitations of present study is that the representative population in present study did not have coccydynia to correlate the findings with the cause of coccydynia. Other limitations were lack of information regarding patient's body mass index and CT scans restricted to supine posture, which could have been additional factors to find the aetiology of coccydynia.

CONCLUSION(S)

To summarise, in present study MSCT was used to determine the variations and relations of coccyx morphology with various other parameters. Type I coccyx was most common with four coccygeal segments. Intercoccygeal fusion was more commonly seen than sacrococcygeal fusion. Coccygeal spicules were seen in approximately half of the group. We hope this knowledge will be helpful to understand coccydynia better and thus will benefit in management of patients.

REFERENCES

- [1] Indiran V, Sivakumar V, Maduraimuthu P. Coccygeal morphology on multislice computed tomography in a tertiary hospital in India. *Asian Spine J.* 2017;11(5):694-99.
- [2] Karayol SS, Karayol KC, Dokumaci DC. Anatomic and morphometric evaluation of the coccyx in the adult population. *Journal of Harran University Medical Faculty.* 2019;16(2):221-26.
- [3] Woon JTK, Perumal V, Maigne JY, Stringer MD. CT morphology and morphometry of the normal adult coccyx. *Eur Spine J.* 2013;22:863-70.
- [4] Shalaby S, Eid EM, Allam OA, Ali AM, Gebba MA. Morphometric study of the normal Egyptian coccyx from (Age 1-40 Year). *International Journal of Clinical and Developmental Anatomy.* 2015;1:32-41.
- [5] Duncan G. Painful coccyx. *Arch Surg.* 1937;34:1088-104.
- [6] Postacchini F, Massobrio M. Idiopathic coccygodynia. Analysis of fifty-one operative cases and a radiographic study of the normal coccyx. *J Bone Joint Surg Am.* 1983;65:1116-24.
- [7] Woon JTK, Stringer MD. Clinical anatomy of the coccyx: A systematic review. *Clin Anat.* 2012;25:158-67.
- [8] Yoon MG, Moon MS, Park BK, Lee H, Kim DH. Analysis of sacrococcygeal morphology in Koreans using computed tomography. *Clinics in Orthopedic Surgery.* 2016;8(4):412-19.
- [9] Tetiker H, Koşar M, Çullu N, Canbek U, Otağ I, Taştımur Y. MRI-based detailed evaluation of the anatomy of the human coccyx among Turkish adults. *Niger J Clin Pract.* 2017;20(2):136-42.
- [10] Kerimoglu U, Dagoglu MG, Ergen FB. Intercoccygeal angle and type of coccyx in asymptomatic patients. *Surg Radiol Anat.* 2007;29:683-87.
- [11] Przybylski P, Pankowicz M, Bockowska A, Czekajka-Chehab E, Staśkiewicz G, Korzec M, et al. Evaluation of coccygeal bone variability, intercoccygeal and lumbo-sacral angles in asymptomatic patients in multislice computed tomography. *Anat Sci Int.* 2013;88:204-11.
- [12] Woon JT, Maigne JY, Perumal V, Stringer MD. Magnetic resonance imaging morphology and morphometry of the coccyx in coccydynia. *Spine (Phila Pa 1976).* 2013;38(23):1437-45.
- [13] Marwan YA, Al-Saeed OM, Esmaeel AA, Kombar OR, Bendary AM, Azeem ME. Computed tomography-based morphologic and morphometric features of the coccyx among Arab adults. *Spine (Phila Pa 1976).* 2014;39(20):1210-19.
- [14] Tague RG. Fusion of coccyx to sacrum in humans: prevalence, correlates, and effect on pelvic size, with obstetrical and evolutionary implications. *Am J Phys Anthropol.* 2011;145:426-37.

PARTICULARS OF CONTRIBUTORS:

1. Assistant Professor, Department of Radiology, Hassan Institute of Medical Sciences, Hassan, Karnataka, India.
2. Consultant Orthopedic Surgeon, Department of Orthopedics, Hassan Institute of Medical Sciences, Hassan, Karnataka, India.
3. Senior Resident, Department of Radiology, Hassan Institute of Medical Sciences, Hassan, Karnataka, India.
4. Senior Resident, Department of Radiology, Hassan Institute of Medical Sciences, Hassan, Karnataka, India.

NAME, ADDRESS, E-MAIL ID OF THE CORRESPONDING AUTHOR:

Dr. SR Raghu,
No 135, Lakshmiranga Nilaya, Hunsinkere Extension, Hassan-573201, Karnataka, India.
E-mail: drraaghasan@gmail.com

AUTHOR DECLARATION:

- Financial or Other Competing Interests: None
- Was Ethics Committee Approval obtained for this study? Yes
- Was informed consent obtained from the subjects involved in the study? Yes
- For any images presented appropriate consent has been obtained from the subjects. Yes

PLAGIARISM CHECKING METHODS: [Jain H et al.]

- Plagiarism X-checker: Jun 18, 2020
- Manual Googling: Sep 21, 2020
- iThenticate Software: Oct 20, 2020 (01%)

ETYMOLOGY: Author Origin

Date of Submission: Jun 17, 2020
Date of Peer Review: Aug 15, 2020
Date of Acceptance: Sep 21, 2020
Date of Publishing: Jan 01, 2021