

Treatment of Large Hepatocellular Carcinoma using Transarterial Chemoembolisation Combined with Sorafenib

SD MADHU¹, FANAI LALSAWMPUII², B HARISH³, NILESH SURYAVAMSHI⁴, KN LOKESH⁵, LK RAJEEV⁶, AMRITHAM USHA⁷



ABSTRACT

Introduction: Hepatocellular Carcinoma (HCC) is the most common primary malignant tumour of liver, accounts for 90% of all primary hepatic tumours, with second most common cause for cancer related deaths worldwide. Majority of HCC will present in Barcelona Clinic Liver Cancer (BCLC) intermediate stage (B), for which Trans Arterial Chemoembolisation (TACE) is the most commonly available treatment. Even though overall prognosis of these locally advanced tumours is poor, significant improvement can still be made in overall survival and recurrence free survival with locoregional therapy like TACE.

Aim: To assess the efficiency, safety and limitations of TACE in large HCC with specific focus on importance of appropriate patient selection.

Materials and Methods: The study was conducted on 30 histopathologically-proven cases of HCC with BCLC intermediate stage. All cases underwent TACE followed by repeat TACE or

treated with Sorafenib depending on their response and clinical status. Treatment related complications, treatment response, recurrence free survival was assessed.

Results: Of the 30 cases, 6 cases had lesion size less than 5 cm, 6 cases with lesion size 5-10 cm and remaining 18 cases had lesion size more than 10 cm, with the largest lesion being 16 cm. Twenty-one cases had elevated Alfa Fetoprotein (AFP), chronic liver disease was seen in 10 cases, with 5 cases having at least 2 lesions. Total 50% of cases with lesion less than 5 cm showed complete response at 15 months, 4 of 6 cases with lesion size of 5-10 cm showed partial response at 15 months, other 2 cases were lost for follow-up. Cases with lesion size more than 10 cm showed mixed response, at 15 months follow-up, 10 cases showed stable response, 6 cases showed progressive disease and 2 patients died due to liver dysfunction.

Conclusion: TACE combined with Sorafenib prolonged the overall survival in selected large tumours with high disease burden status.

Keywords: Child Pugh criteria, Liver, Malignancy

INTRODUCTION

The HCC is the fifth most common tumour and second most common cause for cancer-related deaths worldwide [1]. The frequency of HCC has increased as a result of rising cases of cirrhosis and chronic hepatitis [2-4]. Though there is a major progress in the cancer screening protocols, diagnosis and treatment, the prognosis of HCC remains poor with a 5-year survival rate of less than 5% [5]. The incidence to mortality ratio of liver cancer was assessed to be as high as 95% according to World Health Organisation (WHO) in 2012 [6].

Heterogeneity and complexity are one of the major challenges in treating HCC. The prognosis of HCC depends on remaining liver reserve, underlying liver disease and tumour load which includes tumour size, number of lesions and presence of portal vein invasion. Application of these anatomical factors is imperative in culling the relevant treatment modalities [7-9]. Currently, Barcelona Clinic Liver Cancer (BCLC) system is proposed and validated in the management of HCC. It is used for tumour characterisation and for assessment of the factors influencing long term prognostication, thus assisting the clinicians to adopt the right treatment for specific patients [1,10-12].

In case of early HCC, potential curative management strategies like surgical resection, hepatic transplant or ablation therapies can be employed with a good 5-year survival of 60-70%. Despite the advancement in screening, detection of early HCC is rare. Majority of the HCC is diagnosed in intermediate or advance stage of the disease with compromised liver function [13], thereby only eligible for palliative care. TACE [14-16] is the most common bridge therapy offered (>70%), for patients with HCC waiting for liver transplant

[17,18]. It is a locoregional therapy widely recommended as first line treatment option for a patient with intermediate-stage HCC (BCLC stage B) [1,11]. For patients with BCLC stage A, curative treatment like surgical resection, ablation or liver transplantation is used. In case of advanced HCC with BCLC stage C, only systemic therapy with oral Sorafenib tablet and supportive care is used [1,11]. The present study aimed at assessing the efficiency, safety, limitations and consequence of TACE on liver function in large HCC with specific focus on importance of appropriate patient selection.

MATERIALS AND METHODS

A prospective, cross-sectional observational study was performed in the Department of Radiodiagnosis and Interventional Radiology at Kidwai Memorial Institute of Oncology, Bangalore from January 2017 to December 2018 for over two years with follow-up to February 2020. Approval (KCI/MEC/015/JAN.2017) was taken from the Institutional Scientific Review Committee and Ethical Committee. Written consent was procured from the patient for considering their data for the study. All the cases were discussed in a multidisciplinary meeting which involved medical oncologist, surgical oncologist and pathologist along with interventional radiologist.

Inclusion Criteria

Patients only aged between 18-75 years were considered for the study. Patients with Child-Pugh class A or B, Eastern Cooperative Oncology Group (ECOG) performance status of 0-1, number of lesions less than three, (with a size of the lesion 3-15 cm), no obvious main portal vein or opposite portal vein invasion or hepatic vein invasion on imaging and no extrahepatic disease were included in the study.

Exclusion Criteria

Patients with a previous history of any treatment for HCC including TACE, systemic therapy and ablation, serious medical comorbidities, deranged Renal Function Test (RFT), deranged coagulation profile, other malignancies, ECOG score of more than 2 or Child-Pugh class C or BCLC advanced disease were excluded from the study.

Patient's details including age, sex, clinical presentation, associated comorbidities, laboratory information including AFP levels and imaging details were collected.

TACE Procedure

TACE was conducted by an interventional Radiologist with more than five years of experience. Proper assessment of triphasic Computed Tomography (CT) scan was performed in all the cases to identify the celiac artery, SMA anatomy, anatomical variations if any, and to look for any extrahepatic feeders particularly from phrenic artery, Internal Mammary artery, intercoastal artery, and from Superior Mesenteric Artery (SMA) branches, as their assessment will help the interventional radiologist to plan to embolise these vessels. After puncturing the femoral artery with Seldinger's technique, 5F sheath was introduced. A 4F cobra diagnostic glide catheter was used to cannulate celiac axis and celiac artery angiogram was performed followed by SMA angiogram to look for any additional feeders. In difficult cannulation of the celiac axis, 4F Simmons 1 or 4 French Yashiro glide catheter was used. A 2.8F microcatheter was used further to super selectively cannulate the feeding arteries. Emulsion of Lipiodol and Doxorubicin in 3:1 ratio was prepared and injected into feeding arteries. Total of 5-20 mL of Lipiodol was used and a maximum of 50 mg of Doxorubicin was used in powder form which was diluted depending on the amount of Lipiodol used. Finally, the feeding vessels were embolised using gel foam slurry mixed with contrast, with the endpoint being stasis of contrast. After the embolisation, an angiogram was performed to look for occlusion of feeding artery and to look for any additional feeding vessels.

All patients were monitored with Liver Function Test (LFT), Renal Function Test (RFT) and Complete Blood Count (CBC) on day 1, 3 and 7 after the procedure to assess the post embolisation syndrome and for derangement of liver functions. Patients with refractory disease, or progressive disease, or not tolerating TACE were referred to Medical Oncologist for systemic therapy with Sorafenib. These patients were treated with Sorafenib 400 mg BD, 1 hour before or 2 hours after food. Dose titration was done based on the adverse effects like diarrhoea, hand-foot syndrome, fatigue, nausea vomiting, hypertension and rarely pancytopenia.

All patients were followed-up after 1 month with detailed clinical history, physical examinations, laboratory data including AFP and triphasic CT or MRI to assess the treatment response. Tumour responses of patients to the procedure was classified according to the Modified Response Evaluation Criteria in Solid Tumours for HCC (mRECIST) as either complete response, partial response, stable disease or progressive disease. In case of complete response achieved after 1st TACE patients were started with Sorafenib 400mg BD and were followed up after 3 months and 6 months with the same investigation. In case of stable disease or partial response, repeat TACE was done and further started with sorafenib. Several repeat TACE were performed depending on the tumour response and patient's acceptability, and upto 3 repeat TACE were done in this study. Sorafenib was continued if the patient tolerated the medication. In the case of liver dysfunction or any other adverse effects, the chemotherapy was discontinued. Most of our cases tolerated Sorafenib well with tolerable adverse effects.

STATISTICAL ANALYSIS

Normally distributed data were expressed as mean±standard deviation (SD), while non-normally distributed data were expressed as median (range), and enumeration data were expressed as n (%). Differences in tumour responses and post-treatment complications

between the patients with different tumour sizes were assessed for significance using independent-samples χ^2 tests. The p-value <0.05 was considered as statistically significant. Patients lost to follow-up were excluded from the final analysis.

RESULTS

Overall, 50 patients of HCC were considered for TACE in this study. Of these patients, 20 patients were excluded, as they did not meet the inclusion criteria.

Detailed patient baseline characteristics are depicted in [Table/Fig-1]. In this study group, 25 (83.33%) were males and 5 (16.67%) were females with a mean age of 56.28±10.69 years. Of the total, majority {10 (33.3%)} had alcoholic liver disease, and at least 5 cases with AFP levels more than 50,000 ng/mL among 21 elevated AFP levels. Total 17 (81%) out of 21 patients with increased AFP levels had lesion size more than 10 cm. Most of the cases in this study belonged to Child Pugh's class B (20,66.7%) with 80% of patients did not had any ascites. Majority of the patients (83%, 25) had single lesion. Among 18 patients with lesion size more than 10 cm, at least two cases had multiple lesions and 5 cases had vascular invasion with tumour thrombus in segmental portal vein branches. In this study, 6 patients had vascular invasion in which 5 had segmental portal vein thrombus and 1 had partial thrombus extending into the main portal vein. All these patients underwent TACE with feeding artery embolisation.

Factors		number of patients (n) (%)
Gender	Male	25 (83.33)
	Female	5 (16.67)
Age (mean±SD)		56.28±10.69
Cause for liver disease	Hepatitis B, n (%)	10 (33.33)
	Hepatitis C, n (%)	3 (10.00)
	HIV, n (%)	2 (6.67)
	Alcohol, n (%)	12 (40.00)
	Others, n (%)	3 (10.00)
Liver Cirrhosis	Yes, n (%)	10 (33.33)
	No, n (%)	20 (66.67)
Child PUGH class	A	10 (33.33)
	B	20 (66.67)
Ascites	Yes, n (%)	6 (20.00)
	No, n (%)	24 (80.00)
Liver with portal vein Hypertension	Yes, n (%)	7 (23.33)
	No, n (%)	23 (76.67)
Tumour diameter (cm)	<5, n (%)	6 (20.00)
	5-10, n (%)	6 (20.00)
	>10, n (%)	18 (60.00)
Number of lesions	1	25 (83.33)
	2-3	2 (20.00)
	>3	3 (10.00)
Vascular Invasion	Yes, n (%)	6 (20.00)
	No, n (%)	24 (80.00)
Arteriovenous (AV) fistula	Yes, n (%)	10 (33.33)
	No, n (%)	20 (66.67)
Pseudoaneurysm	Yes, n (%)	4 (13.33)
	No, n (%)	26 (86.67)
AFP (ng/mL)*	Median (range)	2359 (27.5, 5858)
	<400, n (%)	9 (30.00)
	≥ 400, n (%)	21 (70.00)

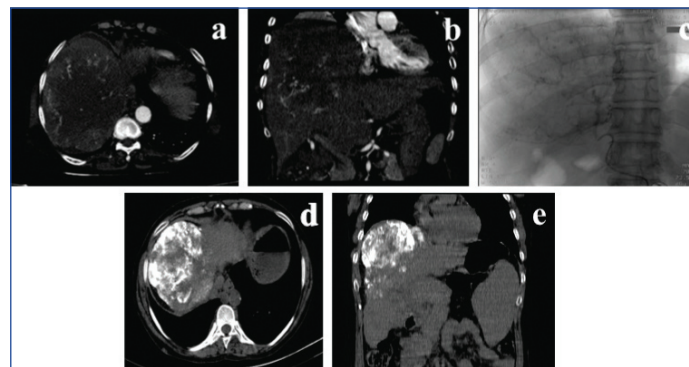
[Table/Fig-1]: Baseline characteristics of the study patients (n=30).

*AFP α -fetoprotein

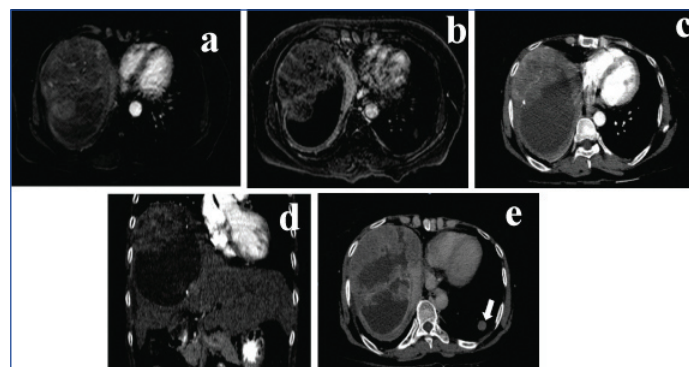
Among 30 cases, selective catheterisation was performed using microcatheter in 23 cases, out of which in 7 cases 4F glide

diagnostic catheter was enough to cannulate the feeding artery, as the right hepatic artery was supplying the entire tumour. AFP was used for follow-up of cases after TACE, as elevated AFP indicates presence of active disease [Table/Fig-2]. Of 21 cases with elevated AFP, after 1st TACE, 10 cases showed significant reduction in AFP values (<400ng/mL), rest showed elevated AFP with average value of 5000 ng/mL with all these cases at 1 month follow-up showing residual disease. Among the cases with size larger than 10 cm, after 1st TACE, 5 cases were in stable disease, eleven cases showed partial response and remaining 2 cases showed progressive disease with appearance of new small lesions. The cases with progressive disease had elevated AFP more than 50,000 ng/mL, cirrhotic background, low albumin, and high Child Pugh score of 8. In this study, 4 well-defined capsulated lesions at CT scan showed complete response at 1 and 3 months follow-up [Table/Fig-3]. Two lesions which were ill-defined at CT scan showed partial response at 1st month follow-up, which underwent second TACE at the 2nd month. At the end of 3rd TACE and follow-up at 6th month, 2 cases with lesion size of 6 cm showed complete response, 2 cases were lost for follow-up and another two cases had partial response [Table/

Fig-4]. Rest of the cases underwent 2nd TACE after 1 month and on further follow-up after a month, of the 5 cases with stable disease, 1 patient showed progressive disease and rest of the cases showed partial response [Table/Fig-5,6]:



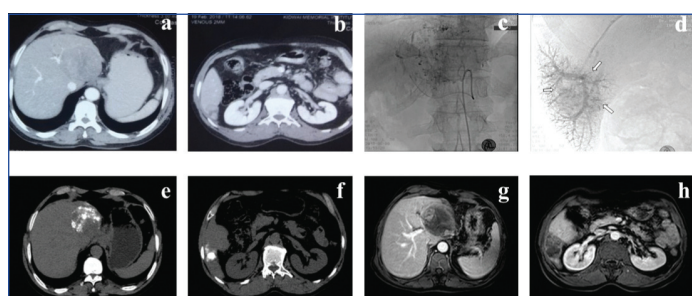
[Table/Fig-5]: Depicting large HCC in right lobe (a, b) measuring 14 cm. Angiography images show Lipiodol doxorubicin deposition during TACE (c). Post TACE follow-up CT scan showing Lipiodol deposition (d, e).



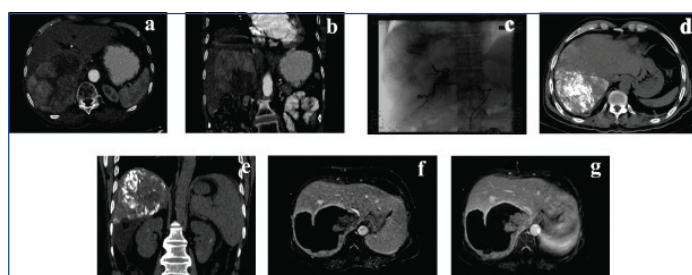
[Table/Fig-6]: Follow-up MRI after 2nd TACE showing partial response (a, b). Follow-up CT scan showing recurrent lesion with extra hepatic supply from Right Internal Mammary Artery (RIMA) and intercostal arteries (c, d). Patient was put on Sorafenib as this was a refractory case even after three TACE procedures. Follow-up scan at 15 months shows progressive lesion (e) (Scans of same patient shown in [Table/Fig-4]).

AFP (ng/mL)*		1 month (n=30)	3 months (n=30)	6 months (n=30)	12 months (n=26)
Total	Median (range)	350 (21, 1200)	200 (14, 1860)	132.5 (14.2, 1665)	55 (11.25, 325)
	<400, n (%)	14 (50.00)	16 (53.33)	17 (56.67)	18 (80.77)
	≥400, n (%)	16 (50.00)	14 (46.67)	13 (43.33)	8 (19.23)
<400 ng/mL, n (%)	<5 cm diameter	3 (10.00)	5 (16.67)	6 (20.00)	6 (23.08)
	5-10 cm diameter	6 (20.00)	6 (20.00)	6 (20.00)	7 (26.92)
	>10 cm diameter	5 (16.67)	5 (16.67)	5 (16.67)	5 (19.23)
≥400 ng/mL, n (%)	<5 cm diameter	3 (10.00)	1 (3.33)	0 (0)	0 (0)
	5-10 cm diameter	3 (10.00)	3 (10.00)	3 (10.00)	2 (7.69)
	>10 cm diameter	10 (33.33)	10 (33.33)	10 (33.33)	6 (23.08)

[Table/Fig-2]: AFP values at 1st, 3rd, 6th and 12th month follow-up for patients post TACE. *AFP α-fetoprotein



[Table/Fig-3]: Depicting multicentric lesions in both right (a) and left lobe (b) measuring less than 5 cms. Angiography images showing Lipiodol doxorubicin deposition during TACE (c, d). Post TACE follow-up CT scan showing Lipiodol deposition (e, f). follow-up MRI after 2nd TACE showing complete response (g, h).



[Table/Fig-4]: Depicting large HCC in right lobe measuring 9 cm (a, b) measuring less than 5 cm. Angiography images showing Lipiodol doxorubicin deposition during TACE (c). Post TACE follow-up CT scan showing Lipiodol deposition (d, e). follow-up MRI after 2nd TACE showing complete response (f, g).

In [Table/Fig-7] overall tumour responses of patients at 1, 3, 12 and 15-month follow-up were listed and at the end of 6 months, 4 patients were lost to follow-up.

Tumour response	1 month (n=30)	3 months (n=30)	6 months (n=30)	12 months (n=26)	15 months (n=24)
Complete response, n (%)	4 (13.33)	4 (13.33)	3 (10.00)	5 (19.23)	4 (16.67)
Partial response, n (%)	19 (63.33)	18 (60.00)	6 (20.00)	11 (42.30)	7 (29.17)
Stable disease, n (%)	5 (16.67)	5 (16.67)	10 (33.33)	2 (7.69)	2 (8.33)
Progressive disease, n (%)	2 (6.67)	3 (10.00)	6 (20.00)	2 (7.69)	2 (8.33)
Recurrence, n (%)	0 (0)	0 (0)	5 (16.67)	2 (7.69)	9 (37.5)
Death, n (%)	0 (0)	0 (0)	0 (0)	2 (7.69)	0 (0)

[Table/Fig-7]: Overall Tumour response at 1,3,12 and 15 months in patients.

Tumour responses of patients at 15-month follow-up were compared based on the initial size of the tumours (<5 cm, 5-10 cm and >10 cm) and shown in [Table/Fig-8]. It was observed that tumour response among the patients with different sizes of tumour differed significantly (p-value=0.018).

Postembolisation syndrome was the most common complication encountered in this study with n=12 is not 60% developing symptoms within a week after the procedure. In all cases the symptoms were self-limiting and were treated with antiemetics and anti-inflammatory drugs. Of the 30 patients treated with TACE, none of the patient developed any major complication after the 1st TACE. After 2nd TACE procedure, two patients died within 8 months due to chronic liver dysfunction who had larger tumour diameter (>10 cm diameter) with

cirrhosis. One patient with large tumour size and with Child Pugh score 8 developed acute liver failure signs after 1st TACE however responded well to medical management. Rest of the patients were on follow-up for 15 months from the date of 1st TACE. Ten patients who had signs of cirrhosis at the time of diagnosis developed worsening Child Pugh score with increasing ascites. Three of the six HBV positive cases that had high viral load at the time of 1st TACE showed worsening of liver function; however they were managed conservatively and were shifted to systemic therapy after stabilising the liver functions. All the patients tolerated the Sorafenib well with tolerable side effects. One of the patients had lesion in segment V developed cholecystitis, however he responded well to medical line of treatment. Treatment related complications in the patients at 15 months follow-up were compared based on the initial size of the tumours (<5 cm, 5-10 cm and >10 cm) and shown in [Table/Fig-9]. Comparison of complications between all the patients with different tumour sizes did not show any statistically significant differences (p-value=0.764).

Tumour response	Tumour size (cm)			p-value*
	<5 (n=6)	5-10 (n=6)	>10 (n=18)	
Complete response, n (%)	3 (50.00)	1 (16.67)	0 (0)	0.018
Partial response, n (%)	0 (0)	2 (33.33)	0 (0)	
Stable disease, n (%)	0 (0)	0 (0)	2 (11.11)	
Progressive disease, n (%)	0 (0)	0 (0)	2 (11.11)	
Recurrence, n (%)	3 (50.00)	1 (16.67)	8 (44.44)	
Death, n (%)	0 (0)	0 (0)	2 (11.11)	

[Table/Fig-8]: Comparison of tumour responses at 15 months for patients with different tumour.

*Statistically significant

Complications	Tumour size (cm)			p-value
	<5 (n=6)	5-10 (n=6)	>10 (n=18)	
Postembolisation syndrome, n (%)	1 (16.67)	3 (50.00)	8 (44.44)	0.764
Acute hepatic failure, n (%)	0 (0)	0 (0)	1 (5.56)	
Cholecystitis, n (%)	0 (0)	1 (16.67)	0 (0)	
Chronic liver dysfunction, n (%)	0 (0)	1 (16.67)	2 (11.11)	

[Table/Fig-9]: Comparison of complications related to treatment at 15th month for patients with different tumour diameters.

DISCUSSION

As the treatment of sorafenib in combination with TACE in advanced HCC has proven to be more-effective [19], the present study was carried out to evaluate the efficiency, safety and limitations of TACE in large HCC and to identify the consequence of TACE on liver function in case of very large tumours. Overall, 50 patients received combined therapy. Of these patients, 20 patients were excluded from the study. Out of 20 excluded cases, 8 patients already underwent repeat TACE elsewhere, 7 patients had significant main portal vein thrombus and 5 patients had the extrahepatic disease at the time of presentation. In total, 30 patients met the inclusion criteria and considered for the evaluation in the present study.

In this study, it was observed in the baseline characteristics 18 out of 30 cases TACE was performed for patients with tumour size more than 10 cm. Since there is a dearth of information in English literature on TACE in HCC larger than 10 cm, the current study remains unique. Tumour size is an important factor in deciding the outcome of TACE. Even though there is no cut-off above which TACE cannot be done, large lesions will leave small normal residual liver, which makes prognosis poor [20]. Patients with large tumours carry worst prognosis compared to patients with tumour size less than 5 cm [19,20]. The same was observed in the current study where it was seen that smaller the tumour size then the complete

response was highest (50% for <5 cm diameter) and as the tumour size increased there was a reduction in response (16.67% for 5-10 cm diameter and 0% for >10 cm diameter). For larger tumour (>10 cm diameter), 11% patient each had disease progression and death which was completely absent in tumour <5 cm in diameter. In a different study Peng ZW et al., reported use of TACE with RFA for lesion around 7 cm with a good outcome, compared to TACE alone [21]. However due to non availability of RFA in this institute, this method was not employed, however, all of the cases received Sorafenib after TACE. Even if the TACE achieves good local necrosis, high recurrence rates in these large tumours inhibit overall survival rates. Tumour revascularisation with blood supply from extrahepatic circulation after TACE along with HCC cell proliferation may accelerate tumour recurrence or progression [22-27]. Additionally, Sorafenib may block HCC proliferation by inducing tumour cell apoptosis in malignant cells that remain after TACE, which may increase recurrence-free survival [28]. In the present study though 28% Patient had segmental portal vein thrombus; it did not affect the tumour responses after the treatment. Similar results reported by Chan LL et al., who determined that segmental portal vein thrombus in HCC did not affect the overall outcome [20].

The AFP is an important prognostication factor and its level is associated with tumour activity in HCC and its increasing level after TACE is associated with recurrence or residual disease [29]. In this study, 70% (21 of the 30 cases) of cases had elevated AFP (>400 ng/mL). Of these, 14% cases with size less than 5 cm and 10% cases with size 5-10 cm showed recurrence at 6 months, rest of the 76% cases with size more than 10 cm, showed partial response in 9% cases, progressive disease in 29% cases, stable disease in 29% cases and death in 9% cases at the end of 15 months. These results confirmed that higher AFP levels are associated with poor prognosis. Current conclusion is in the same line with the outcome of a study carried out by Zhu K et al., where they have observed that cases with elevated AFP >400 ng/mL, carried worse overall median survival compared to those with normal AFP [19].

The hypoxia induced by TACE may activate Hypoxia Inducible Factor-1alpha (HIF-1alpha)/Vascular Endothelial Growth Factor A (VEGFA) pathway [22,24]. However, Sorafenib has been reported to suppress HIF-1alpha/VEGFA expression [28], and thus suppresses the rapid progression of residual HCC cells [23,25], increasing the overall recurrence free survival in patients taking Sorafenib. The present study showed that combination of Sorafenib with TACE in patients with large tumour was safe with minimal tolerable side effects and is comparable with previous studies [30-32].

None of the cases in this study developed on the table or immediate postprocedure complications. Even though the majority of the case were having tumour more than 10 cm, none of the cases developed hepatic dysfunction due to the procedure. This is attributed to selective infusion of chemotherapy emulsion into feeding vessels only, sparing the vessels supplying the normal liver.

Limitation(s)

The option of using RFA for larger cases was not available. There was no adequate information supporting the utilisation of TACE alone or TACE with Sorafenib in tumours bigger than 10 cm. There is no standard treatment protocol to be used for follow-up cases, the decision on the treatment option was according to the patient condition, ECOG status, Child Pugh score and tumour response on imaging. Finally, for the study patients were followed-up for only 15 months.

CONCLUSION(S)

Present study demonstrated that sorafenib combined with TACE significantly improved the outcome in patients with advanced HCC without any unexpected side effects. It was also seen that tumour

burden plays significant role along with elevated AFP (> 400 ng/mL), in post treatment responses. In conclusion, TACE and Sorafenib are an effective treatment option in patients with large tumours. Along with Sorafenib it prolongs the overall survival and, in some cases, increases the recurrence free survival. However, prospective randomised control trials are needed to show the effect of TACE with Sorafenib in comparison to Sorafenib alone in larger tumours.

REFERENCES

- [1] EASL-EORTC clinical practice guidelines: management of hepatocellular carcinoma. *J Hepatol.* 2012;56:908-43.
- [2] World Health Organization: Cancer: Fact Sheet (February 2017). <http://www.who.int/mediacentre/factsheets/fs297/en/> (accessed May 5, 2017).
- [3] El-Serag HB, Rudolph KL. Hepatocellular carcinoma: epidemiology and molecular carcinogenesis. *Gastroenterology.* 2007;132(7):2557-76.
- [4] Jemal A, Murray T, Samuels A, Tiwari RC, Ghafoor A, et al. Cancer statistics, 2005. *CA Cancer J Clin.* 2005;55(1):10-30.
- [5] El-Serag HB. Hepatocellular carcinoma. *N Engl J Med.* 2011;365:1118-27.
- [6] McGuire S. World Cancer Report 2014. Geneva, Switzerland: World Health Organization, International Agency for Research on Cancer, WHO Press, 2015. Adv Nutr. 2016;7:418-19.
- [7] Zhong JH, Rodriguez AC, Ke Y, Wang YY, Wang L, Li LQ. Hepatic resection as a safe and effective treatment for hepatocellular carcinoma involving a single large tumour, multiple tumours, or macrovascular invasion. *Medicine (Baltimore).* 2015;94:e396.
- [8] Chan SL, Chong CC, Chan AW, Poon DM, Chok KS. Management of hepatocellular carcinoma with portal vein tumour thrombosis: review and update at 2016. *World J Gastroenterol.* 2016;22:7289-300.
- [9] Forner A, Gilabert M, Bruix J, Raoul JL. Treatment of intermediate-stage hepatocellular carcinoma. *Nat Rev Clin Oncol.* 2014;11:525-35.
- [10] National Comprehensive Cancer Network: NCCN Clinical Practice Guidelines in Oncology. Hepatobiliary Cancers. Version 3.2017. (7)
- [11] Bruix J, Sherman M. Management of hepatocellular carcinoma: an update. *Hepatology.* 2011;53:1020-22.
- [12] Llovet JM, Brú C, Bruix J. Prognosis of hepatocellular carcinoma: The BCLC Staging Classification. *Semin Liver Dis.* 1999;19:329-38.
- [13] Davila JA, Duan Z, McGlynn KA, El-Serag HB. Utilisation and outcomes of palliative therapy for hepatocellular carcinoma: a population-based study in the United States. *J Clin Gastroenterol.* 2012;46:71-77.
- [14] Garcia-Tsao G, Lim JK. Members of Veterans Affairs Hepatitis C Resource Center Program. Management and treatment of patients with cirrhosis and portal hypertension: recommendations from the Department of Veterans Affairs Hepatitis C Resource Center Program and the National Hepatitis C Program. *Am J Gastroenterol.* 2009;104:1802-29.
- [15] Sherman M, Bruix J, Porayko M, Tran T. AASLD Practice Guidelines Committee. Screening for hepatocellular carcinoma: the rationale for the American Association for the Study of Liver Diseases recommendations. *Hepatology.* 2012;56:793-96.
- [16] Shah SA, Smith JK, Li Y, Ng SC, Carroll JE, Tseng JF. Underutilization of therapy for hepatocellular carcinoma in the medicare population. *Cancer.* 2011;117:1019-26.
- [17] Thuluvath PJ, Guidinger MK, Fung JJ, Johnson LB, Rayhill SC, Pelletier SJ. Liver transplantation in the United States, 1999-2008. *Am J Transplant.* 2010;10:1003-19.
- [18] Bruix J, Llovet JM. Prognostic prediction and treatment strategy in hepatocellular carcinoma. *Hepatology.* 2002;35:519-24.
- [19] Zhu K, Huang J, Lai L, Huang W, Mi C, Zhou J, et al. Medium or large hepatocellular carcinoma: sorafenib combined with transarterial chemoembolisation and radiofrequency ablation. *Radiology.* 2018;288:300-07.
- [20] Chan LL, Chan SL. Treatment of high-burden hepatocellular carcinoma: an oncologist perspective. *Hepatoma Res.* 2018;4:5.
- [21] Peng ZW, Zhang YJ, Chen MS, Xu L, Liang H, Lin X, et al. Radiofrequency ablation with or without transcatheter arterial chemoembolisation in the treatment of hepatocellular carcinoma: a prospective randomised trial. *J Clin Oncol.* 2013;31(4):426-32.
- [22] Kong J, Kong J, Pan B, Ke S, Dong S, Li X, et al. Insufficient radiofrequency ablation promotes angiogenesis of residual hepatocellular carcinoma via HIF-1 α /VEGFA. *PLoS One.* 2012;7(5):e37266.
- [23] Takada Y, Kurata M, Ohkohchi N. Rapid and aggressive recurrence accompanied by portal tumour thrombus after radiofrequency ablation for hepatocellular carcinoma. *Int J Clin Oncol.* 2003;8(5):332-35.
- [24] Kong J, Kong L, Kong J, Ke S, Gao J, Ding X, et al. After insufficient radiofrequency ablation, tumour associated endothelial cells exhibit enhanced angiogenesis and promote invasiveness of residual hepatocellular carcinoma. *J Transl Med.* 2012;10(1):230.
- [25] Shiozawa K, Watanabe M, Takahashi M, Wakui N, Iida K, Sumino Y. Analysis of patients with rapid aggressive tumour progression of hepatocellular carcinoma after percutaneous radiofrequency ablation. *Hepatogastroenterology.* 2009;56(96):1689-95.
- [26] Lee HY, Rhim H, Lee MW, Kim Y, Choi D, Park MJ et al. Early diffuse recurrence of hepatocellular carcinoma after percutaneous radiofrequency ablation: analysis of risk factors. *Eur Radiol.* 2013;23(1):190-97.
- [27] Yoshida S, Kornek M, Ikenaga N, Schmelzle M, Masuzaki R, Csizmadia E, et al. Sublethal heat treatment promotes epithelial-mesenchymal transition and enhances the malignant potential of hepatocellular carcinoma. *Hepatology.* 2013;58(5):1667-80.
- [28] Liu L, Cao Y, Chen C, Zhang X, McNabola A, Wilkie D, et al. Sorafenib blocks the RAF/MEK/ERK pathway, inhibits tumour angiogenesis, and induces tumour cell apoptosis in hepatocellular carcinoma model PLC/PRF/5. *Cancer Res.* 2006;66(24):11851-58.
- [29] Li P, Wang SS, Liu H, Li N, McNutt MA, Li G, et al. Elevated serum alpha fetoprotein levels promote pathological progression of hepatocellular carcinoma. *World J Gastroenterol.* 2011;17(41):4563-71.
- [30] Cheng AL, Kang YK, Chen Z, Tsao C, Qin S, Kim JS, et al. Efficacy and safety of sorafenib in patients in the Asia-Pacific region with advanced hepatocellular carcinoma: a phase III randomised, double-blind, placebo-controlled trial. *Lancet Oncol.* 2009;10(1):25-34.
- [31] Llovet JM, Ricci S, Mazzaferro V, Hilgard P, Gane E, Blanc J, et al. Sorafenib in advanced hepatocellular carcinoma. *N Engl J Med.* 2008;359(4):378-90.
- [32] Pawlik TM, Reyes DK, Cosgrove D, Kamel IR, Bhagat N, Geschwind JF. Phase II trial of sorafenib combined with concurrent transarterial chemoembolisation with drug-eluting beads for hepatocellular carcinoma. *J Clin Oncol.* 2011;29(30):3960-67.

PARTICULARS OF CONTRIBUTORS:

1. Associate Professor, Department of Radiodiagnosis, Kidwai Memorial Institute of Oncology, Bangalore, Karnataka, India.
2. Postgraduate, Department of Radiodiagnosis, Kidwai Memorial Institute of Oncology, Bangalore, Karnataka, India.
3. Associate Professor, Department of Nuclear Medicine, Kidwai Memorial Institute of Oncology, Bangalore, Karnataka, India.
4. Postgraduate, Department of Radiodiagnosis, Kidwai Memorial Institute of Oncology, Bangalore, Karnataka, India.
5. Associate Professor, Department of Medical Oncology, Kidwai Memorial Institute of Oncology, Bangalore, Karnataka, India.
6. Associate Professor, Department of Medical Oncology, Kidwai Memorial Institute of Oncology, Bangalore, Karnataka, India.
7. Associate Professor, Department of Pathology, Kidwai Memorial Institute of Oncology, Bangalore, Karnataka, India.

NAME, ADDRESS, E-MAIL ID OF THE CORRESPONDING AUTHOR:

Dr. SD Madhu,
No 51044, Building 5, Prestige Falcon City, Near Konanakunte Cross, Kanakapura Road, Bangalore-560062, Karnataka, India.
E-mail: sdmadhudoc@gmail.com

PLAGIARISM CHECKING METHODS: [Jain H et al.]

- Plagiarism X-checker: Jun 10, 2020
- Manual Googling: Sep 04, 2020
- iThenticate Software: Oct 20, 2020 (06%)

ETYMOLOGY: Author Origin

AUTHOR DECLARATION:

- Financial or Other Competing Interests: None
- Was Ethics Committee Approval obtained for this study? Yes
- Was informed consent obtained from the subjects involved in the study? Yes
- For any images presented appropriate consent has been obtained from the subjects. Yes

Date of Submission: Jun 09, 2020

Date of Peer Review: Jun 25, 2020

Date of Acceptance: Sep 10, 2020

Date of Publishing: Jan 01, 2021