

Morphometric Study of Foramina Transversaria in Cervical Vertebrae and Its Clinical Significance

GYATA MEHTA¹, VARSHA MOKHASI²

ABSTRACT

Introduction: The characteristic feature of the cervical vertebrae is the presence of Foramen Transversarium (FT) in the transverse process. This foramen usually contains vertebral artery (except in C7 vertebra), veins and sympathetic plexus. The deformity and variations of this foramen may result in derangement of neurovascular structures passing through it, which may lead to various symptoms. The aetiology of morphological variations is related to developmental factors, mechanical stress and variations in the course of vertebral artery. Some studies have been done on accessory FT, but few give detailed analysis of morphometric variations of FT in cervical vertebrae.

Aim: The aim of the study was to examine the morphological and morphometric variations in the FT of cervical vertebrae (typical and atypical).

Materials and Methods: This was a retrospectively designed osteological observational study. The duration of the study was six months, from Dec 2019 to May 2020. The study was conducted on 750 cervical vertebrae (265 typical and 485 atypical). In each cervical vertebrae, the FT was observed for the following parameters; shape, size, maximum antero-posterior

diameter, maximum transverse diameter, area and number. Digital Vernier caliper was used for morphometric measurements. Photographs were taken and archived. Descriptive analysis and evaluation was done with SPSS statistics programme.

Results: In 300 (40%) vertebrae, shape of the FT was bilaterally symmetrical and in 450 (60%) vertebrae, it was asymmetrical on both sides. It was observed that maximum antero-posterior diameter and transverse diameter were seen in C1 vertebrae. There was no significant statistical difference between the mean diameters of the left and right side. Maximum area was also seen in C1 vertebrae, with values of 34.76 mm² on left and 34.84 mm² on right. Out of the 750 cervical vertebrae, 113 (15%) showed an accessory FT in the transverse process. Amongst these, in 30 (4%) cervical vertebrae, the accessory FT were present bilaterally and in 83 (11%) seen on one side only.

Conclusion: The present study demonstrates that different cervical vertebrae (typical and atypical) show considerable morphological variations in terms of shape, size, area and number of FT. Awareness of such variations is of significance to anatomists, clinicians and surgeons.

Keywords: Foramen transversarium, Morphometry, Variations

INTRODUCTION

The cervical vertebrae are seven in number, and all have one characteristic feature; presence of Foramen Transversarium (FT) affecting each transverse process. In typical cervical vertebrae, the transverse process has dorsal and ventral bars around the FT which terminate laterally as corresponding tubercles. These are connected lateral to the FT by costal or intertubercular lamella. The dorsal and ventral tubercles and the intertubercular lamella represent morphologically the capitulum, tubercle and neck of a cervical costal element. The morphological transverse process is represented by the attachment of the dorsal bar to the pediculo-laminar junction [1]. Foramen Transversarium gives passage to vertebral artery, vertebral vein and sympathetic plexus from inferior cervical ganglion while C7 vertebra transmits only the vein [2]. The vertebrae of the cervical part and the proximal thoracic part of the human vertebral column are the area undergoing the most intense transformation during phylogeny, leading to many anatomical variations [3]. Many factors are involved in causing morphological variations of foramen transversarium, including developmental factors, mechanical stress, size and number of anatomical structures passing through [4]. The deformity and variations of this foramen may affect the anatomical course of vascular and neural structures and consequently cause pathological conditions [5]. It may cause vertebro-basilar insufficiency as a result of neck movements. The developmental variants of cervical vertebrae, especially C1 and C2 may produce a series of disorders such

as headache, vertigo, buzzing in ears, paresis or paralysis of extremities [6]. The anatomic variations of the FT may be associated with variations of the vertebral artery. This is of great importance to spine surgeons, as injury to vertebral artery may occur in both anterior and posterior approach of the cervical spine. Thorough investigation of such variations is necessary for proper preoperative planning. Knowledge of these variations is useful for radiologists for interpreting the MRI and CT and specially CT angiographies of the cervical spine with relevance to cervical surgery.

In literature, many studies have been done on variations in number of Foramen Transversarium [7-11] but very few depict morphometric details of FT. Hence, the need of the study arose, and this is one of the few studies in the state of Karnataka (India) to give detailed morphometric analysis of FT of all the cervical vertebrae. The findings are academically significant and will add to literature. Thus the aim of the study was to examine the morphological and morphometric variations in the Foramen Transversarium of the cervical vertebrae and highlight its clinical significance.

MATERIALS AND METHODS

This was a retrospectively designed osteological observational study. Ethical clearance was not applicable as it was an osteological study. Sample size was determined by the availability of bony specimens. All the specimens available during the six months were included in the study. The duration of the study was six months from Dec 2019 to May 2020.

Cervical vertebrae were collected from the Department of Anatomy, Department of Forensic medicine and Department of Orthopedics of Vydehi Institute of Medical Sciences and Research Centre, Bangalore. Total of 750 cervical vertebrae were collected, of which 265 were typical and 485 were atypical cervical vertebrae. The age and sex of the vertebrae were unknown and vertebrae with deformities and damaged foramen transversarium were excluded from the study.

In each cervical vertebra, the foramen transversarium was observed for the following parameters: shape, size, maximum antero-posterior diameter, maximum transverse diameter, area and number. According to the shape and direction of the main diameter, the foramen transversarium was classified into five types, using the criteria by Taitz C et al [12] as seen in [Table/Fig-1].

Type I- Round

Type II- Elliptical with main diameter antero-posterior

Type III- Elliptical with main diameter transverse

Type IV- Elliptical with main diameter oblique from right to left

Type V- Elliptical with main diameter oblique from left to right

Digital Vernier calipers of 0.01 mm precision were used for morphometric measurements. Photographs were taken and archived.

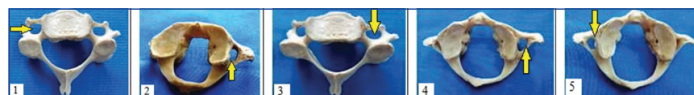STATISTICAL ANALYSIS

The data was compiled in Microsoft excel software. Descriptive analysis and evaluation was done with SPSS statistics programme (version 19). Independent sample t test was performed to compare the mean values of antero-posterior diameter, transverse diameter and area of FT between Right and Left side. The p value was found to be >0.05, which signifies that no effect was observed. This implies that there was no statistical difference in the parameters of the FT of the two sides.

RESULTS

Morphology and Morphometry

(1) **Shape of FT-** Shape of the foramen transversarium was found to be bilaterally symmetrical in 300 vertebrae (40%) and asymmetrical in 450 vertebrae (60%). In vertebrae with bilaterally symmetrical shape of FT, Type III (47%) had the highest frequency. In vertebrae with asymmetrical shape of FT on both sides, Type V had the highest frequency (64.6%) on the left side, and Type IV (64%) on the right side. Further details of variants of shape of FT of all the cervical vertebrae as classified into five types is seen in [Table/Fig-2,3].



[Table/Fig-1]: Classification of types of Foramen Transversarium. 1-Type I(round), 2- TypeII (oval), 3-TypeIII(elliptical); 4-TypeIV (oblique with main axis right to left), 5-TypeV (oblique with main axis left to right).

Type of shape FT	C1 n=40	C2 n=70	C7 n=44	Typical CV n=146	Total no. n=300/750	Percentage 40%
I	4	48	7	48	107	36
II	36	9	4	4	53	17
III	-	13	33	94	140	47
IV	-	-	-	-	-	-
V	-	-	-	-	-	-

[Table/Fig-2]: Variations in shape of bilaterally symmetrical foramen transversarium in cervical vertebrae. CV- Cervical vertebrae

(2) **Antero-posterior diameter-** It was observed that maximum antero-posterior diameter was seen in C1 vertebrae with a mean value of 7.30 mm on left and 7.23 mm on right. Refer to [Table/Fig-4] for details.

(3) **Transverse diameter-** The widest range of transverse diameter was seen in C1 vertebrae with a mean value of 5.96 mm on left and 5.90 on right. Refer to [Table/Fig-5] for details.

(4) **Area-** Maximum area was seen in C1 vertebrae, with values of 34.76 mm² on left and 34.84 mm² on right. Refer to [Table/Fig-6] for details.

(5) **Number of FT:** Accessory FT was seen in 113 (15%) vertebrae and it varied with the level of cervical vertebrae. Maximum number of accessory FT was seen in typical cervical vertebrae 73 (64.6%). Refer to [Table/Fig-7&8] for details.

DISCUSSION

The cause of morphological variations in FT in the transverse process of cervical vertebrae is not well known. It may be developmental or related to the variations in the course of vertebral artery. In nearly 90% of cases, vertebral artery enters into the FT of C6 vertebrae, but it may also enter the cervical vertebral column through C1 (15%), C4 (2%), C5 (5%) or C7 (2%) [13]. The vertebral vessels are considered as a factor in the formation of the FT, hence, variations in the presence and course of the vessels will be manifested in changes of FT. Conversely, variations of the FT can be useful for estimating changes or variations of the vessels and accompanying nerve structures [12]. In C7 vertebrae, large size FT may be due to big veins or simple connective tissue.

Taitz C et al [12] studied the different types of FT in each side of the vertebrae and showed that C1 and C7 vertebrae had the highest frequency of Type 4 and 5 on the right and left FT respectively. In C2, the lateral aperture was predominantly Type I and inferior aperture was predominantly Type 4 and 5. The typical cervical vertebrae showed high frequency of Type I and Type III. The present morphological study revealed variations in shape of the FT, which were classified into five types. In 300 vertebrae (40%) the shape of FT was bilaterally symmetrical and in 450 vertebrae (60%) the FT was asymmetrical on both sides. A comparison of studies [14-16] of variations in the shapes of FT is depicted in [Table/Fig-9].

In the present study, the maximum antero-posterior diameter of FT was found in C1 vertebrae with a mean value of 7.3 mm on left and 7.23 mm on the right side. The maximum transverse diameter was also found in C1 vertebrae with a mean value of 5.96 mm on left and 5.90 mm on the right side. There was no significant statistical difference between the mean diameters of the two sides. These findings are in consistence with the study of Taitz C et al [12], which showed that for length of FT, C1 had the highest value of 7.23 mm on left and 7.26 mm on the right side. The maximum breadth was also found in C1 vertebrae with mean value of 5.76 mm on left and 5.52 mm on the right side. He observed that left FT was generally larger than the right.

Another study had similar findings with maximum length seen in C1 vertebrae with a mean value of 7.42 mm on left and 7.44 mm on right and also maximum breadth seen in C1 vertebrae with a mean value of 6.03 mm on left and 5.95 mm on the right side [17]. Another morphometric study of FT showed that antero-posterior diameter of left side had a mean value of 5.26 mm and right side 5.21 mm. Same study showed the transverse diameter had a mean value of 5.84 mm on left and 5.78 mm on the right side [13]. A study on typical cervical vertebrae observed that FT showed a wide difference in diameter in individual vertebrae. The antero-posterior diameter had a mean value of 5.13 mm on left and 5.17 mm on the right side and the transverse diameter had a mean value of 5.87 mm on left and 5.69 mm on the right side [18].

It was analysed that mean diameter of FT of left and right side showed wide range of variations in individual cervical vertebrae from C1 to C7, but when compared between the two sides, these changes were found to be statistically insignificant. Jaffar AA et al., [4] studied the area of FT at different levels of cervical vertebrae and analysed that maximum area of FT was seen in C1 vertebrae

Type of shape FT	Right side						Left side					
	C1 120	C2 135	C7 76	Typical CV- 119	Total no- 450/750	Percentage -60	C1 120	C2 135	C7 76	Typical CV-119	Total no-450/750	Percentage 60
I	4	16	4	13	37	8.2	6	16	-	12	34	7.5
II	4	12	-	2	18	4.2	4	4	4	3	15	3.6
III	2	8	8	13	31	6.8	-	15	-	10	25	5.5
IV	110	96	12	70	288	64	-	4	57	24	85	18.8
V	-	3	52	21	76	16.8	110	96	15	70	291	64.6

[Table/Fig-3]: Variations in shape of bilaterally asymmetrical foramen transversarium in cervical vertebrae.
CV- Cervical vertebrae

Cervical vertebra	Right side				Left side				p-value
	Range-mm	Mean-mm	SD	V	Range-mm	Mean-mm	SD	V	
C1	5.17-10.29	7.23	0.816	0.816	4.85-9.68	7.30	0.925	0.856	>.05
C2	3.62-8.75	5.76	0.872	0.761	3.29-8.67	5.64	0.816	0.666	>.05
C7	2.30-8.16	5.62	1.17	1.38	2.30-9.03	5.49	1.50	2.25	>.05
Typical	3.06-8.79	5.41	0.853	0.727	2.69-8.37	5.59	1.00	1.08	>.05

[Table/Fig-4]: Independent sample t test was performed to compare the mean values of Antero-posterior diameters of FT of Right & Left sides.
FT: Foramen transversarium; SD: Standard Deviation; V: Coefficient of variation

Cervical vertebra	Right side				Left side				p-value
	Range-mm	Mean-mm	SD	V	Range-mm	Mean-mm	SD	V	
C1	4.30-8.37	5.90	0.752	0.574	4.65-9.01	5.96	0.755	0.570	>.05
C2	3.75-8.01	5.24	0.803	0.645	3.43-8.15	5.35	0.870	0.758	>.05
C7	2.30-8.16	5.62	1.17	1.38	2.62-9.14	5.90	1.43	2.04	>.05
Typical	3.06-8.71	5.41	0.853	0.727	2.72-8.88	5.80	0.993	0.917	>.05

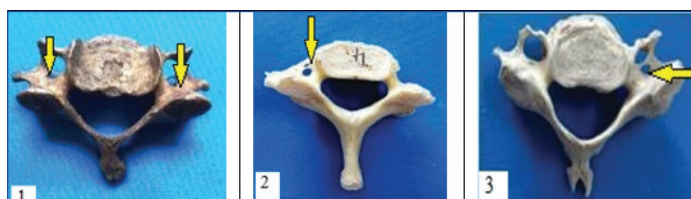
[Table/Fig-5]: Independent sample t test was performed to compare the mean values of Transverse diameters of FT of Right & Left sides.
FT: Foramen transversarium; SD: Standard Deviation; V: coefficient of variation

Cervical vertebra	Right side		Left side		p-value
	Area (mm) ²	SD	Area (mm) ²	SD	
C1	34.84	6.66	34.76	7.76	>.05
C2	24.06	6.66	23.96	6.02	>.05
C7	27.37	8.82	26.13	10.41	>.05
Typical	26.57	6.53	27.97	8.10	>.05

[Table/Fig-6]: Independent sample t test was performed to compare the mean values of Area of FT of Right & Left sides.
FT: Foramen transversarium; SD: Standard deviation

Cervical vertebra with Accessory FT	Accessory FT present Bilaterally	Accessory FT present Unilaterally		
		Right side	Left side	Total
C1-3	-	-	3	3
C2- 2	-	2	-	2
C7- 35	6	11	18	29
Typical- 73	24	27	22	49
Total -113(15%)	30(4%)	40	43	83(11%)

[Table/Fig-7]: Frequency of accessory foramen transversarium in cervical vertebrae.



[Table/Fig-8]: Presence of Accessory Foramen Transversarium in Cervical vertebrae. 1-Accessory FT present bilaterally, 2- Accessory FT present on left, 3- Accessory FT present on right

with mean values of 31.8 mm² on the left and 32.9 mm² on the right side. The distortion of the vertebral artery and its largest caliber at the level of first cervical vertebrae could be considered as a mechanical factor for the maximum area of FT in C1 vertebrae. The findings of the present study were in consistence with the previous studies showing maximum area of FT in the C1 vertebrae,

Author	Type of shape FT	Percentage on right side	Percentage on left side	Percentage Total
Vasuki M. AK et al., [14]	1	22	21.6	43.6
	2	0.8	1.6	2.4
	3	12	10.8	22.8
	4	6.4	8.4	14.8
	5	8.0	7.2	15.2
Abdul RS et al [15]	A	26.19	29.37	55.56
	B	3.97	1.59	5.56
	C	9.52	12.70	22.22
	D	15.87	8.73	4.6
	E	8.73	14.29	23.02
Ambali MP, Jadhav SD [16]	Others	34.91	31.75	66.6
	1	20.24	22.69	42.93
	2	8.5	9.2	17.7
	3	6.13	5.52	11.65
	4	21.47	23.31	44.78
	5	19.63	19.01	38.64
Present study	Others	23.90	20.23	44.13
	I	8.2	7.5	15.7
	II	4	3.3	7.3
	III	6.8	5.5	12.3
	IV	64	18.8	82.8
V	16.8	64.6	78.4	

[Table/Fig-9]: Comparison of studies of variations in shapes of FT in cervical vertebrae.
FT- Foramen transversarium

amongst all specimens of cervical vertebrae. This exhibits that the FT on both sides enclose comparable neurovascular and connective tissue masses.

Accessory FT is considered when the FT is anatomically divided by a fibrous or bony ridge and the smaller posterior part is called

the accessory FT [19]. Ambiguity persists about the content of this accessory FT, whether it is occupied by the vertebral vein, vertebral nerves or by a duplicate vertebral artery or both. The relations of these structures are of surgical importance in the posterior approach of the cervical spine. The embryogenesis of the vertebral arteries occurs between day 32 and 40 of gestation. The paired vertebral arteries arise from longitudinal branches that link together to form a longitudinal vessel and secondarily lose their intersegmental connections to the aorta [20]. It has been speculated that persistence of a portion of the primitive dorsal aorta with two intersegmental arteries may give rise to vertebral artery duplication. Failure on the regression of the intersegmental arteries can also result in vertebral artery fenestration [21]. This fenestration may contribute to the development of double FT.

Studies on accessory FT have been undertaken earlier. The occurrence rate ranged from 1.5% [22] to 26.25% [23]. The findings of the present study were consistent with the previous studies. Triple FT was seen by Taitz C et al., [12] in 0.2% vertebrae unilaterally and absent FT was reported by Nayak S [24] in C1 vertebra. A comparison of studies of Accessory FT is shown in [Table/Fig-10].

Study	Total No. of CV	CV with Accessory FT	Percentage
Kaya S et al., [5]	22	5	22.7 %
Chaudhari ML et al., [7]	133	22	23.15%
Gonsai V et al., [8]	200	40	20%
Akhtar MJ et al., [9]	174	25	14.36%
Sumalatha T et al.[10]	148	17	11.48%
Aghera BR et al., [11]	175	24	13.7%
Sharma A et al., [19]	200	16	8%
Das S et al., [22]	132	2	1.5%
Singh AP et al., [23]	240	63	26.25%
Present study	750	113	15%

[Table/Fig-10]: Comparison of studies on incidence of Accessory FT in cervical vertebrae.
CV-Cervical Vertebrae, FT-Foramen Transversarium

The study depicted various morphometric details of FT in cervical vertebrae. These variations are important findings as they may be associated with variations of the vertebral artery, which may be asymptomatic or have various clinical manifestations. Vertigo, cervical myelopathy, and ischemic events caused by occlusion and dissection of the vertebral artery have been attributed to variations of its course [25]. An unexpected course of these vessels may lead to injury and cerebral vascular disturbance. Knowledge of these variations is important in spinal procedures, especially during posterior instrumentation of the upper cervical spine or anterior corpectomy. There is a higher risk in posterior procedures, such as lateral mass and pedicle screw fixation, laminoplasty and foraminotomy [26]. A complete preoperative assessment could be used as a prevention technique.

Limitation(s)

Age, sex and race of the bony specimens were not known. This limits the applications of this study. Future studies may focus on vertebrae from same vertebral column to examine the individual typical and atypical cervical vertebrae precisely for variations in FT, with comparison between males and females.

CONCLUSION(S)

The present morphological study of FT highlights many different parameters and morphometric variations in 750 cervical vertebrae (typical and atypical). Shape, size, area and number in FT were examined and analysed. Knowledge of variations of FT is clinically

significant, as it may affect the course of vascular bundle and nerves causing symptoms to patients. Any variation found during radiological investigations of FT, should be co-related with vertebral artery variation or vice versa, as both generally co-exist.

This study strongly helps in increasing the awareness of variations in FT, which will help the surgeons for better preoperative planning thereby reducing intraoperative complications. It will also be beneficial in the interpretation of CT and MRI for diagnostic purposes. Thus, the impact of the study will be of value to anatomists for academic purpose and to radiologists, neurophysicians and neurosurgeons who deal with intervention in FT for various clinical conditions and investigations.

REFERENCES

- [1] Standring S, Gray H. Gray's Anatomy, 40th ed. Edinburg: Churchill Livingstone/Elsevier, London. 2008. Pp:718-720
- [2] Ellis H. Clinical Anatomy, 11th ed. Miami, MA, Blackwell pub. 2006. pp:325-28
- [3] Bailey RW. The cervical spine. Lea & Febiger, Philadelphia 1974. Pp:47-74
- [4] Jaffar AA, Mobarak HJ, Najm SA. Morphology of the Foramen Transversarium A Correlation with Causative Factors. Al-Kindy Col Med. J 2004;2:61-64.
- [5] Kaya S et al. Double Foramen Transversarium Variation in Ancient Byzantine Cervical Vertebrae: Preliminary Report of an Anthropological Study. Turkish Neurosurgery 2011;21:534-38.
- [6] Wysocki J, Bubrowski M, Reymond J, Kwiatkowski J. Anatomical variants of the cervical vertebrae and the first thoracic vertebra in man. Folia Morphol. 2003;62(4):357-63.
- [7] Chaudhari ML, Maheria PB, Bachuwar SP. Double Foramen Transversarium in Cervical Vertebra: Morphology and Clinical importance. Indian Journal of Basic & Applied Medical Research. 2013;8(2):1084-88.
- [8] Gonsai V, Jadav J, Shah HR. Variations in Transverse Foramina of Cervical Vertebrae: Morphology & Clinical Importance. B J Kines-NJBAS. 2015;7(2):06-09.
- [9] Akhtar MJ, Madhukar PM, Rahman S, Kashyap N. A morphometric study of foramen transversarium of dried cervical vertebrae. International Journal of Research in Medical Sciences. 2015;3(4):912-16.
- [10] Sumalatha T, Manasa B. Variations in Foramen Transversarium of Cervical Vertebrae- An Observational Study. International Journal of Anatomy, Radiology and Surgery. 2018;7(3):13-17.
- [11] Aghera BR, Ahmed S, Parmar A, Agarwal G C, Singel T C. Morphological study of anatomical variation of foramen transversarium in cervical vertebrae and its clinical implication. Indian Journal of Clinical Anatomy and Physiology. 2018;5(2):170-172.
- [12] Taitz C, Nathan H, Arensburg B. Anatomical observations of the foramina Transversaria. Journal of Neurology, Neurosurgery and Psychiatry. 1978;41:170-76.
- [13] Gupta M, Agarwal S. Morphometric study of Foramina Transversaria and the incidence of Accessory Foramina in Cervical Spine of Indian Population. Journal of Clinical and Diagnostic Research. 2019;13(3):07-11.
- [14] Vasuki A.K.M et al. An osteological study of foramen transversarium of cervical vertebrae and its clinical significance. International Journal of Anatomy and Research. 2018;6(1.2):4906-13.
- [15] Abdul RS, Lazarus L, Rennie C, Satyapal KS. The foramen transversarium of typical and atypical cervical vertebrae: Morphology and morphometry. Int. J. Morphol 2018;36(4):1439-46.
- [16] Ambali MP, Jadhav SD. Anatomical variations in foramen transversarium of typical cervical vertebrae and its clinical significance. International journal of Anatomy and Research. 2017;5(1):3426-29.
- [17] Maqbool A, Hameed O, Athar Z. Study of native foramina transversaria in the cervical spine. JSZMC 2015;6(1):746-49.
- [18] Sangari SK, Dossous PM, Heineman T, Mtui EP. Dimensions and Anatomical Variants of the Foramen Transversarium of Typical Cervical Vertebrae. Anatomy Research International. 2015;01-05.
- [19] Sharma A, Singh K, Gupta G, Srivastava S. Double foramen transversarium in cervical vertebrae an osteological study. J Anat. Soc. India. 2010;59:229-231.
- [20] William J Larsen. Development of vasculature. Human Embryology. 3rd ed. Churchill Livingstone, London. Pp:179-181
- [21] Sim E, Vaccaro AR, Berzlanovich A, Thaler H, Ullrich CG. Fenestration of the extracranial vertebral artery: Review of the literature. Spine. 2001;26:139-142.
- [22] Das S, Suri R, Kapur V. Double Foramen Transversaria: An osteological study with clinical implications. Int Med J. 2005;12:311-13.
- [23] Singh AP, Anand C, Singh S. A Study of Anatomical Variations in Transverse Foramen of Cervical Vertebrae for Morphological and Clinical Importance. IJCMR. 2019;6(6):9-11.
- [24] Nayak S. Bilateral absence of foramen transversarium in atlas vertebra: A case report. Neuroanatomy. 2007;6:28-29.
- [25] Zibis A et al. Variations of transverse foramina in cervical vertebrae: What happens to the vertebral artery? European Spine Journal 2018; <https://doi.org/10.1007/s00586-018-5523-2>
- [26] Lunardini DJ et al. Vertebral artery injuries in cervical spine surgery. Spine J. 2014;14(14):1520-25.

PARTICULARS OF CONTRIBUTORS:

1. Associate Professor, Department of Anatomy, Vydehi Institute of Medical Sciences and Research Centre, Bangalore, Karnataka, India.
2. Professor and Head, Department of Anatomy, Vydehi Institute of Medical Sciences and Research Centre, Bangalore, Karnataka, India.

NAME, ADDRESS, E-MAIL ID OF THE CORRESPONDING AUTHOR:

Gyata Mehta,
Apartment No.9146 Prestige Shantiniketan Whitefield ITPL Main Road Bangalore-
560048, Karnataka, India.
E-mail: drgyatamehta@gmail.com

PLAGIARISM CHECKING METHODS: [Ujan H et al.1](#)

- Plagiarism X-checker: Jul 03, 2020
- Manual Googling: Sep 16, 2020
- iThenticate Software: Oct 08, 2020 (02%)

ETYMOLOGY: Author Origin**AUTHOR DECLARATION:**

- Financial or Other Competing Interests: None
- Was Ethics Committee Approval obtained for this study? NA
- Was informed consent obtained from the subjects involved in the study? NA
- For any images presented appropriate consent has been obtained from the subjects. NA

Date of Submission: **Jul 02, 2020**
Date of Peer Review: **Aug 01, 2020**
Date of Acceptance: **Sep 19, 2020**
Date of Publishing: **Jan 01, 2021**