

# Scimitar Sign-Interesting Radiology

GOVINDARAJ VISHNUKANTH<sup>1</sup>, DHARM PRAKASH DWIVEDI<sup>2</sup>, CHELLAMUTHU SELVARAJA<sup>3</sup>,  
VIJAYARANGAM NARENCHANDRA<sup>4</sup>, KOTTAISAMY RAMASUBRAMANIAM<sup>5</sup>



**Keywords:** Anomalous pulmonary vein, Turkish sword, Venolobar syndrome

A 16-year-old girl presented with streaky haemoptysis and recurrent respiratory tract infections since childhood. She had no prior anti tubercular treatment or known coagulopathies. Her chest X-ray showed a curved, tubular opacity adjacent to the right side of the heart and extending toward the diaphragm resembling a sword [Table/Fig-1]. A possibility of scimitar sign was considered and a Contrast CT chest was performed which showed right pulmonary vein draining into Inferior vena cava. There was also associated right lung lower lobe hypoplasia. Echocardiography revealed an atrial septal defect. The clinical features and radiological investigations confirmed a diagnosis of Scimitar syndrome. She was operated and the scimitar vein was rerouted to left atrium via right atrium [Table/Fig-2]. Currently, the patient is on regular follow-up and is doing well till the last contact six months back.

Scimitar syndrome is popularly also called venolobar syndrome or hypogenetic lung syndrome. This congenital abnormality has few unique features like pulmonary hypoplasia, cardiac dextroposition, pulmonary artery hypoplasia, and systemic arterial supply to the lung [1]. The term scimitar was first used by Halasz and subsequently Neil and associates described the 'scimitar syndrome' in 1960 [2].

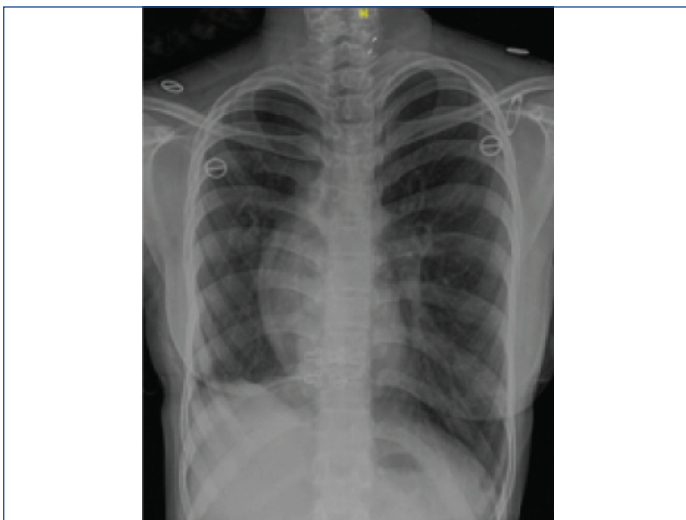
Scimitar sign is a curved, tubular opacity adjoining to right of heart and reaching towards the diaphragm. The anomalous pulmonary vein that drains the major part of the right lung is the major cause of the appearance of this sign. The curved opacity runs close to the right heart border and extends from the level of the hilum to the diaphragm progressively widening along its course giving an appearance of a Turkish sword (Scimitar refers to a Persian sword with a curved blade). The vein usually traverses the diaphragm and drains into the Inferior Vena Cava (IVC). Rarely, it may drain into the hepatic or portal vein or the right atrium [1]. In the present case, the anomalous vein drained into the IVC.

The scimitar sign can also occur in Anomalous Single Pulmonary Vein (ASPV) where the entire lung is drained by a single pulmonary vein with an anomalous course, but draining normally into the left atrium [3]. In scimitar syndrome, as the anomalous vein drains into the IVC or right atrium, there is usually a left to right shunt whereas there is no shunt in ASPV. Scimitar syndrome is believed to be caused by failure of integration of primitive pulmonary venous plexus with the common pulmonary vein, resulting in communication with cardinal or umbilical veins, whereas ASPV is understood to be due to hypoplasia or atresia of one of the pulmonary veins before pulmonary segmentation. ASPV is sometimes referred as pseudoscimitar sign [4].

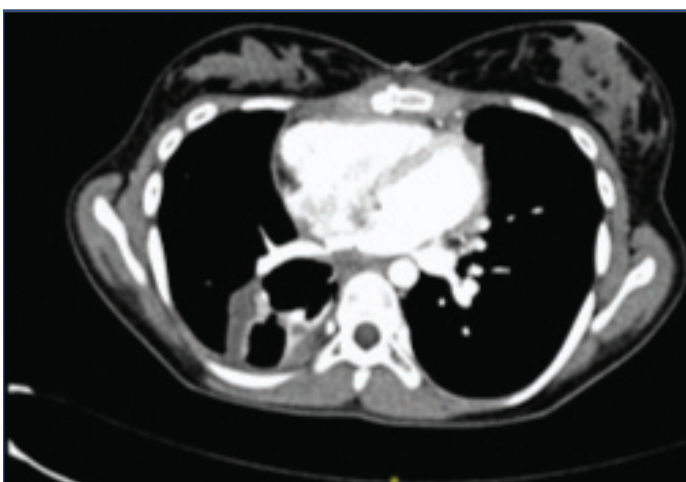Scimitar syndrome more often presents in infancy with symptoms of failure to thrive, pulmonary hypertension and heart failure symptoms. Adults are typically asymptomatic and are incidentally revealed on routine chest radiograph. Most patients with isolated Scimitar syndrome have excellent prognosis [4,5].

Though usually made out on chest X-ray, a computed tomography or a Magnetic Resonance Imaging (MRI) is required to make out the associated anomalies. CT also helps to delineate the vascular supply and is helpful to prevent torrential bleeding at surgery. Demonstration of the anomalous pulmonary venous return requires a contrast study to identify the feeding artery. Echocardiography should be done to rule out associated cardiac anomalies especially atrial septal defect [4].

Differential diagnosis for scimitar sign includes a pulmonary sequestration, pulmonary venous varix, and pulmonary nodule. Pulmonary sequestration and scimitar syndrome can be differentiated by lung ultrasound prenatally. The former shows hyperechogenic lung and the latter dextrocardia [6].



**[Table/Fig-1]:** Chest X-ray PA view showing a curvilinear opacity on the right side of the heart extending toward the diaphragm.



**[Table/Fig-2]:** Post operative CT image (mediastinal cut) showing rerouting of scimitar vein to left atrium.

Treatment is needed for symptomatic scimitar syndrome patient and requires surgical repair of the anomalous venous return or excision of the involved lung. A pneumonectomy of the hypoplastic lung may also be needed in some cases [5].

Scimitar syndrome represents a complex system of anomalies. A simple chest X-ray can raise a suspicion of this syndrome and an early diagnosis in this potentially treatable condition.

## REFERENCES

- [1] Wang CC, Wu ET, Chen SJ, Frank Lu, Huang SC, Wang JK, et al Scimitar syndrome: incidence, treatment and prognosis. *Eur J Pediatr.* 2008;167(2):155-60.
- [2] Bourassa MG. The scimitar syndrome: report of two cases of anomalous venous return from a hypoplastic right lung to the inferior vena cava. *Can Med Assoc J.* 1963;88(3):115-20.
- [3] Morgan JR, Forker AD. Syndrome of hypoplasia of the right lung and dextroposition of the heart: "Scimitar sign" with normal pulmonary venous drainage. *Circulation.* 1971;43:27-30.
- [4] Nazarian J, Kanne JP, Rajiah P. Scimitar Sign. *J Thorac Imaging.* 2013;28(4):61.
- [5] Assoignon M, Christiaens P, Laleman W. Correction of the scimitar syndrome, a rare cardiac venous anomaly, leading to Budd–Chiari syndrome: a case report. *Journal of Medical Case Reports.* 2014;8:273.
- [6] Bhide A, Murphy D, Thilaganathan B, Carvalho JS. Prenatal findings and differential diagnosis of scimitar syndrome and pulmonary sequestration. *Ultrasound in Obstetrics & Gynecology: the Official Journal of the International Society of Ultrasound in Obstetrics and Gynecology.* 2010;35(4):398-404.

### PARTICULARS OF CONTRIBUTORS:

1. Associate Professor, Department of Pulmonary Medicine, JIPMER, Puducherry, India.
2. Associate Professor, Department of Pulmonary Medicine, JIPMER, Puducherry, India.
3. Junior Resident, Department of Pulmonary Medicine, Gorimedu, Puducherry, India.
4. Junior Resident, Department of Pulmonary Medicine, Gorimedu, Puducherry, India.
5. Senior Resident, Department of Pulmonary Medicine, JIPMER, Puducherry, India.

### NAME, ADDRESS, E-MAIL ID OF THE CORRESPONDING AUTHOR:

Dr. Govindaraj Vishnukanth,  
JIPMER, D Nagar Gorimedu, Pondicherry, India.  
E-mail: vishnu1429@yahoo.com

### PLAGIARISM CHECKING METHODS: [Jan H et al.]

- Plagiarism X-checker: Jun 29, 2020
- Manual Googling: Aug 24, 2020
- iThenticate Software: Oct 06, 2020 (20%)

### ETYMOLOGY: Author Origin

### AUTHOR DECLARATION:

- Financial or Other Competing Interests: None
- Was Ethics Committee Approval obtained for this study? No
- Was informed consent obtained from the subjects involved in the study? NA
- For any images presented appropriate consent has been obtained from the subjects. NA

Date of Submission: **Jun 28, 2020**  
Date of Peer Review: **Jul 27, 2020**  
Date of Acceptance: **Aug 26, 2020**  
Date of Publishing: **Jan 01, 2021**