

# Patellar Thickness and its Implication on Patellar Resurfacing

S VIJAYAMOHAN<sup>1</sup>, NIJITH OMPEDATHIL GOVINDAN<sup>2</sup>, ARJUN PADMALAYAN<sup>3</sup>

## ABSTRACT

**Introduction:** Total Knee Arthroplasty (TKA) is a successful and highly satisfactory surgery, nonetheless some patients remain dissatisfied. A major reason for this is anterior knee pain, caused due to inappropriate addressal of patellar issues during TKA. There are numerous studies comparing the functional outcome between the patellar resurfaced knee and non resurfaced knee. Patella has the thickest cartilage in the body due to high level of force in the patello-femoral joint. Normal patellar thickness in western studies is between 22-26 mm. After resurfacing, a minimum bony thickness of 12-15 mm is necessary to avoid fracture.

**Aim:** To measure the thickness of patella intraoperatively and to identify whether patella can be resurfaced, with respect to the thickness of patella.

**Materials and Methods:** A cross-sectional study was conducted on 78 knees in a consecutive series of 49 patients,

between March to November 2019. The thickness of patella was measured intraoperatively using vernier callipers in patients with tricompartmental osteoarthritis knee undergoing TKA.

**Results:** The average thickness of patella recorded in females was 21.7 mm, in males was 23.85 mm and total average was 22.05 mm. Percentage of the sample with patellar thickness below 23 mm was 82% and percentage of patellar thickness below 20 mm was 15.4%. There was statistically significant difference between the patellar thickness of males and females ( $p$ -value  $< 0.05$ ). There was however no significant difference between the right and left patella among both the genders. Maximum thickness of patella recorded in the study was 26 mm while the minimum was 17 mm.

**Conclusion:** The average patellar thickness, measured intraoperatively, in this study was  $22.05 \pm 1.87$  mm. Patellar resurfacing must be undertaken only on a selective basis with respect to the thickness of patella.

**Keywords:** Anterior knee pain, Patelloplasty, Patellar morphometry, Total knee arthroplasty

## INTRODUCTION

The TKA is a common surgical procedure associated with long term clinical success. Anterior knee pain remains one of the reasons for dissatisfaction following a TKA. There are reports of incidence of anterior knee pain following TKA upto 8% [1]. Numerous studies have evaluated various factors that contribute to anterior knee pain which includes patello-femoral design, surgical technique, patient characteristic and degree of chondromalacia [2-4]. Resurfacing of the patella remains a highly controversial subject. A selective primary patellar resurfacing has become more popular approach among knee surgeons [5]. The National Joint Replacement Registry 2010, Australia concluded that the rate of early revision was higher in non resurfaced patellar group (4%) when compared to the resurfaced group (3.1%) at five year follow-up [6].

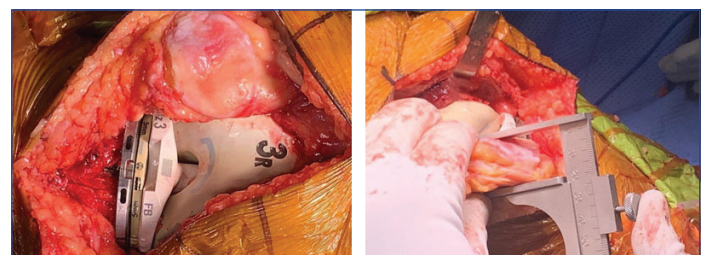
Patella acts as a mobile fulcrum increasing the mechanical advantage of extensor mechanism throughout the knee range of motion. Patello-femoral contact pressure is maximum at around  $120^\circ$  knee flexion. The patella has the thickest cartilage in the body due to high level of forces in the patello-femoral joint. TKA further increases these force by three times, exposing the patella to super-physiological loads. The normal patellar thickness lies between 22-26 mm. Given that, most patellar components are 8-10 mm in thickness, a minimum bony thickness of 12-15 mm after resection is necessary to avoid fracture and loosening [7]. The goal in resurfacing is to restore the native patellar thickness of that particular patient. Over or under restoration of patellar thickness is one of the cause for patella related complication in resurfaced patella [8]. Best results for patellar resurfacing include maximising size of patella button without over hang, placing component slightly superior to avoid patella baja, slightly medialised to improve tracking, inlay fixation is better than onlay fixation [9].

The present study was aimed to identify whether it is feasible to resurface Indian patella as there is significant difference in the thickness of patella between the Asian and Caucasian population.

## MATERIALS AND METHODS

This was a cross-sectional study conducted in a single centre between March to November 2019. The study population comprised of a consecutive series of patients with tricompartmental osteoarthritis knee, diagnosed clinico-radiologically and undergone TKA in Aster Medcity, Kochi, Kerala, India. Cases of post traumatic arthritis, postseptic arthritis knee and Revision TKA were excluded from the study. The study received approval from the Institutional Ethical Committee (Ref No. AM/EC/100-2019). Written informed consents from participants were obtained prior to the TKA.

The thickness of patella was measured using vernier calliper intraoperatively during TKA [Table/Fig-1]. The maximum thickness of patella between the anterior and posterior surfaces was measured before patelloplasty; and otherwise the surgical procedure was not altered. The measurement was recorded on the surgical note.



**[Table/Fig-1]:** Intraoperative image of patellar undersurface with trial implants in-situ and measurement of patellar thickness with vernier calliper

## STATISTICAL ANALYSIS

All of the statistical analysis was performed using IBM SPSS Statistics 20 version and Microsoft Office Excel. The power of the study was kept at 80% for the purpose of sample size calculation. The sample size was calculated as N=66 for a power of the study 80%. The present study has included 78 samples since these were a consecutive series of 78 knees in 49 patients who underwent TKA within the study time period. Descriptive statistics were computed on variables such as age, right knee-patellar thickness and left knee-patellar thickness. Independent sample t-test were used to compare mean difference between male and female groups. A p-value less than 0.05 show the statistical significance. A bar chart was used to compare average patellar thickness.

## RESULTS

The thickness of patella was measured, intraoperatively, from 78 knees in 49 patients of whom 29 patients underwent bilateral TKA. There were 12 unilateral left TKA and 8 unilateral right TKA cases. The study sample included 38 females and 11 males. The average thickness of patella recorded in females was 21.7 mm, males were 23.85 mm [Table/Fig-2] and total average was 22.05 mm with a standard deviation of 1.87; and median value being 22 mm for bilateral patella [Table/Fig-3]. There was statistically significant difference between the patellar thickness of males and females ( $p$ -value<0.05) (independent sample t-test) [Table/Fig-4]. There was however no significant difference between the right and left patella among both the genders. Maximum thickness of patella recorded in the study was 26 mm while the minimum was 17 mm. Percentage of the sample with patellar thickness below 23 mm was 82% and percentage of patellar thickness below 20 mm was 15.4% [Table/Fig-5].

Variables	Male (11)	Females (38)	p-value
Total average thickness (mm)	23.85±1.83	21.7±1.76	<0.05 *
Right knee-Patellar Thickness (mm)	23.44±1.87	21.75±2.10	<0.05 *
Left knee-Patellar Thickness (mm)	22.9±1.85	21.65±1.45	<0.05 *
Age (in years)	72.63±4.41	63.63±8.37	<0.05 *

[Table/Fig-2]: Gender-wise comparison of patellar thickness.

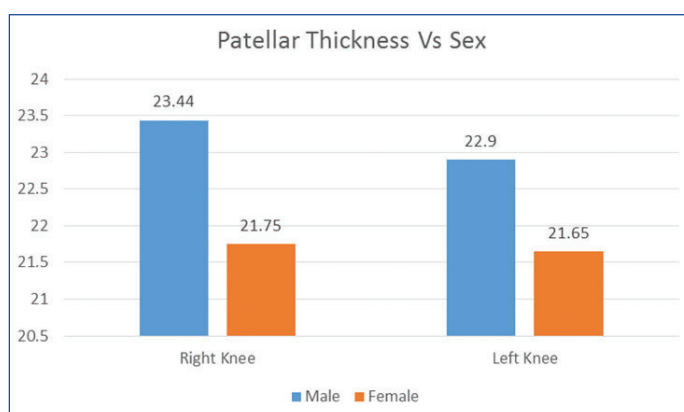
Statistical test: Independent Sample t-test

\* Highly significant statistically

Descriptive Statistics							
Variables	Number	Range	Minimum	Maximum	Mean	Std. Deviation	Median
Age	49	36.00	49.00	85.00	65.6531	8.51604	65
Right knee-Patellar Thickness (mm)	36	9.00	17.00	26.00	22.1806	2.15855	22
Left knee-Patellar Thickness (mm)	42	9.00	17.00	26.00	21.9524	1.62229	22
Total	78	9	17	26	22.05	1.87	Overall median = 22 mm

[Table/Fig-3]: Baseline characteristics and outline of data

From the study, it was also identified that TKA in females was undertaken at a younger age group (average age 63.63 years compared to 72.63 years in males, value <0.05) and demographically more females have undergone TKA than males.



[Table/Fig-4]: Bar chart for gender wise comparison of patellar thickness

Variables	Frequency	%
Percentage of sample with thickness below 23 mm*	64	82% (64/78)†
Percentage of sample with thickness below 20 mm*	12	15.4% (12/78)

[Table/Fig-5]: Distribution of Indian patellar thickness with respect to critical thickness for resection

\* The critical thickness for resection was calculated based on the minimum thickness of 12-15 mm of patella to avoid risk of future fracture added with a patellar button size of 8 mm

† 82% (64/78) of the sample patella was below 23 mm and therefore care needs to be taken while considering patellar resurfacing in those patients.

p-value: <0.001(Statistically Significant)

## DISCUSSION

There are three different approaches to address patella in TKA: systematic resurfacing, selective resurfacing and systematic non resurfacing [10]. Certain studies indicated that systematic resurfacing may be effective in reducing, postoperative anterior knee pain and improving knee function [11-14], whereas systematic non resurfacing seemed to be associated with fewer intraoperative complications, reduced surgical time and comparable clinical outcomes [15,16]. A meta-analysis of patellar resurfacing versus patellar retention in primary TKA identified no significant differences in the functional scores between patellar resurfacing and non resurfacing. However, few pointed to an increase in reoperation/revision in studies with more than five years of follow-up, a result not seen in studies with less than five years follow-up [17]. This is because the problem of wear and tear of patella may increase with time and a shorter follow-up period will not be adequate to capture the issue. Though it is still ambiguous as to how patellar resurfacing will influence the subsequent anterior knee pain and functional scores post TKA, there is a general consensus about the significant reduced risk of reoperation after patellar resurfacing [18,19]. Certain literatures also support a selective resurfacing practice in primary TKA [20,21].

Controversy aside, one must consider with due diligence whether it is feasible to undertake a patellar resurfacing in the Indian population. It is well known that there is significant difference in the morphometry of knee joint between the Asian and Caucasian population, with the Asian knees being generally smaller compared to the Caucasian knees [22]. An in vivo magnetic resonance imaging morphometry of patella in South Indians [23] identified significantly lower values of patellar thickness compared to Western [24], Korean [25], and Chinese population [26]. Though imaging modalities like MRI are able to delineate cartilage boundaries better, an intraoperative measurement of patella is more accurate in planning the patellar implant. As most of the commercially available knee prosthesis for TKA or PFA is designed based on the dimensions from the Caucasians, there were concerns whether these would be suitable for Indians.

This study measured the patellar thickness of 78 knees intraoperatively, and the average thickness was found to be 22 mm. Patella should not be resected to less than 12-15 mm in order to

minimise the risk of future fracture [27]. The all-polyethylene dome patellar component comes in minimum sizes of 8-10 mm; hence if we consider resecting patella leaving behind a safe margin of 15 mm, the average patella should be at least 23 mm thick. However, in this study, 64 of the given 78 sample, that is 82% of the sample falls below 23 mm. If the critical thickness of resection is considered as 12 mm, then the initial patellar thickness ought to be at least 20 mm. According to the data, 12 out of the 78, that is, 15.4% of the sample fell below this value, and in this population patellar resection was not an option. With the given measurements of Indian patella, it might be difficult to achieve the goal of reproducing the thickness of the patella to being equal or 1 mm less than the native patella with the conventional domes. Lately, a manufacturer has come up with a thinner patellar button (6.2 mm) to be used in thinner patella but the long term effects remain unclear [28]. The gender variability of the patellar thickness should also be considered with respect to the implant design as well as the functional outcome after TKA for resurfacing the patella.

### Limitation(s)

This study has many limitations. First is the small sample size as we have taken consecutive patients encountered in a six month study period. Since the study was conducted in a single centre in India, it might not be an adequate representation of the entire Indian population. The study could not comment on the complications of patellar resurfacing because it is not routine practice in the study institution to resurface the patella in TKA.

### CONCLUSION(S)

The average patellar thickness, measured intraoperatively, in this study was  $22.05 \pm 1.87$  mm. There was statistically significant difference in thickness of patella between males and females. However, there was no significant difference between the right and left patella in both genders. Patellar resurfacing must be undertaken only on a selective basis with respect to the thickness of patella.

### REFERENCES

- Petersen W, Rembitzki IV, Brüggemann GP, Ellermann A, Best R, Gösele-Koppenburg A, et al. Anterior knee pain after TKA: a narrative review. *International orthopaedics*. 2014;38(2):319-28.
- Seil R, Pape D. Causes of failure and etiology of painful primary total knee arthroplasty. *Knee Surgery, Sports Traumatology, Arthroscopy*. 2011;19(9):1418.
- Popovic N, Lemaire R. Anterior knee pain with a posterior-stabilized mobile-bearing knee prosthesis: the effect of femoral component design. *The Journal of Arthroplasty*. 2003;18(4):396-400.
- Rodríguez-Merchán EC, Gómez-Cardero P. The outerbridge classification predicts the need for patellar resurfacing in TKA. *Clinical Orthopaedics and Related Research*. 2010;468(5):1254-57.
- Slevin O, Schmid FA, Schiapparelli F, Rasch H, Hirschmann MT. Increased in vivo patellofemoral loading after total knee arthroplasty in resurfaced patellae. *Knee Surgery, Sports Traumatology, Arthroscopy*. 2018;26(6):1805-10.
- Clements WJ, Miller L, Whitehouse SL, Graves SE, Ryan P, Crawford RW. Early outcomes of patella resurfacing in total knee arthroplasty: A report from the Australian Orthopaedic Association National Joint Replacement Registry. *Acta orthopaedica*. 2010;81(1):108-13.
- Abdel MP, Parratte S, Budhiparama NC. The patella in total knee arthroplasty: to resurface or not is the question. *Current Reviews in Musculoskeletal Medicine*. 2014;7(2):117-24.
- Enis JE. Comparison of patellar resurfacing versus non-resurfacing in bilateral total knee arthroplasty. *Clinical Orthopaedics and Related Research*. 1993;(288):310.
- Feucht MJ, Cotic M, Beitzel K, Baldini JF, Meidinger G, Schöttle PB, et al. A matched-pair comparison of inlay and onlay trochlear designs for patellofemoral arthroplasty: no differences in clinical outcome but less progression of osteoarthritis with inlay designs. *Knee Surgery, Sports Traumatology, Arthroscopy*. 2017;25(9):2784-91.
- Schindler OS. The controversy of patellar resurfacing in total knee arthroplasty: Ibisne in medio tutissimus? *Knee Surgery, Sports Traumatology, Arthroscopy*. 2012;20(7):1227-44.
- Kim SH, Lee S, Cho Y, Lee YM, Chung KY, Lee MC. Comparison of patellar resurfacing versus preservation in high flexion total knee arthroplasty. *Knee Surgery, Sports Traumatology, Arthroscopy*. 2015;23(6):1782-90.
- Patel K, Raut V. Patella in total knee arthroplasty: to resurface or not to—a cohort study of staged bilateral total knee arthroplasty. *International Orthopaedics*. 2011;35(3):349-53.
- Johnson TC, Tatman PJ, Mehle S, Gioe TJ. Revision surgery for patellofemoral problems: should we always resurface?. *Clinical Orthopaedics and Related Research*. 2012;470(1):211-19.
- Swan JD, Stoney JD, Lim K, Dowsey MM, Choong PF. The need for patellar resurfacing in total knee arthroplasty: a literature review. *ANZ Journal of Surgery*. 2010;80(4):223-33.
- Panni AS, Cerciello S, Del Regno C, Felici A, Vasso M. Patellar resurfacing complications in total knee arthroplasty. *International Orthopaedics*. 2014;38(2):313-17.
- Pavlou G, Meyer C, Leonidou A, As-Sultany M, West R, Tsiroidis E. Patellar resurfacing in total knee arthroplasty: does design matter?: a meta-analysis of 7075 cases. *JBJS*. 2011;93(14):1301-09.
- Grassi A, Compagnoni R, Ferrua P, Zaffagnini S, Berruto M, Samuelsson K, et al. Patellar resurfacing versus patellar retention in primary total knee arthroplasty: a systematic review of overlapping meta-analyses. *Knee Surgery, Sports Traumatology, Arthroscopy*. 2018;26(11):3206-18.
- He JY, Jiang LS, Dai LY. Is patellar resurfacing superior than nonresurfacing in total knee arthroplasty? A meta-analysis of randomized trials. *The Knee*. 2011;18(3):137-44.
- Chen K, Li G, Fu D, Yuan C, Zhang Q, Cai Z. Patellar resurfacing versus nonresurfacing in total knee arthroplasty: a meta-analysis of randomised controlled trials. *International Orthopaedics*. 2013;37(6):1075-83.
- Antholz CR, Cherian JJ, Elmallah RK, Jauregui JJ, Pierce TP, Mont MA. Selective Patellar Resurfacing: A Literature Review. *Surgical Technology International*. 2015;26:355-60.
- Maradit-Kremers H, Haque OJ, Kremers WK, Berry DJ, Lewallen DG, Trousdale RT, et al. Is selectively not resurfacing the patella an acceptable practice in primary total knee arthroplasty? *The Journal of Arthroplasty*. 2017;32(4):1143-47.
- Yue B, Varadarajan KM, Ai S, Tang T, Rubash HE, Li G. Differences of knee anthropometry between Chinese and white men and women. *The Journal of Arthroplasty*. 2011;26(1):124-30.
- Muhamed R, Saralaya VV, Murlimanju BV, Chettiar GK. In vivo magnetic resonance imaging morphometry of the patella bone in South Indian population. *Anatomy & Cell Biology*. 2017;50(2):99-103.
- Baldwin JL, House CK. Anatomic dimensions of the patella measured during total knee arthroplasty. *The Journal of Arthroplasty*. 2005;20(2):250-57.
- Yoo JH, Yi SR, Kim JH. The geometry of patella and patellar tendon measured on knee MRI. *Surgical and Radiologic Anatomy*. 2007;29(8):623-28.
- Shang P, Zhang L, Hou Z, Bai X, Ye X, Xu Z, et al. Morphometric measurement of the patella on 3D model reconstructed from CT scan images for the southern Chinese population. *Chinese Medical Journal*. 2014;127(1):96-101.
- Malo M, Vince KG. The unstable patella after total knee arthroplasty: etiology, prevention, and management. *JAAOS-Journal of the American Academy of Orthopaedic Surgeons*. 2003;11(5):364-71.
- Jhurani A, Agarwal P, Aswal M, Saxena P, Singh N. Safety and efficacy of 6.2 mm patellar button in resurfacing less than 20 mm thin patella: a matched pair analysis. *Knee Surgery & Related Research*. 2018;30(2):153.

#### PARTICULARS OF CONTRIBUTORS:

- Lead Consultant, Department of Orthopaedics, Aster Medcity, Kochi, Kerala, India
- Consultant Orthopaedic Surgeon, Department of Orthopaedics, Lakshmi Group of Hospitals, Kochi, Kerala, India
- Specialist, Department of Orthopaedics, Aster Medcity, Kochi, Kerala, India.

#### NAME, ADDRESS, E-MAIL ID OF THE CORRESPONDING AUTHOR:

Dr. Nijith Ompedathil Govindan,  
Consultant Orthopaedic Surgeon, Lakshmi Group of Hospitals, Kochi, Kerala-  
682016, India.  
E-mail: nijithgovindan@gmail.com, drnijith@gmail.com

#### AUTHOR DECLARATION:

- Financial or Other Competing Interests: None
- Was Ethics Committee Approval obtained for this study? Yes
- Was informed consent obtained from the subjects involved in the study? Yes
- For any images presented appropriate consent has been obtained from the subjects. No

#### PLAGIARISM CHECKING METHODS: [Jain H et al.]

- Plagiarism X-checker: May 05, 2020
- Manual Googling: Jul 23, 2020
- iThenticate Software: Sep 15, 2020 (18%)

#### ETYMOLOGY: Author Origin

Date of Submission: **May 04, 2020**  
Date of Peer Review: **Jun 09, 2020**  
Date of Acceptance: **Jul 29, 2020**  
Date of Publishing: **Oct 01, 2020**