

Radiation Ulcer in the Epigastric Region: A Rare Case

XU SHUQIA¹, ZHU ZHAOWEI², XU YANGBIN³, LIU XIANGXIA⁴

(CC) BY-NC-ND

ABSTRACT

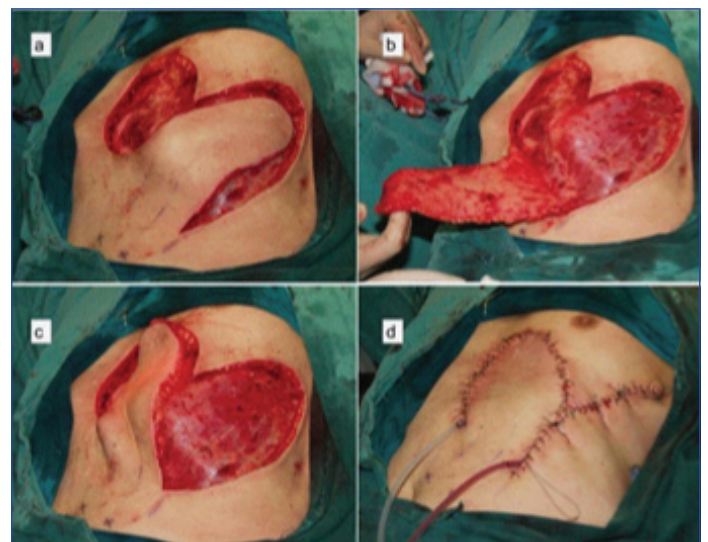
Radiation Therapy (RT) constitutes an integral part of oncological treatment. Skin changes following RT can range from dermatitis to non-healing ulcer. The advances in delivery of radiation like Intensity Modulated Radiotherapy (IMRT) and its further developments have reduced the incidence of these complications. However, patients who had received RT much earlier before the era of IMRT can manifest these complications many years later. We report a 66-year-old male who presented with an ulcer in the epigastric region, which was not healing for more than 10 years. He had Dermatofibrosarcoma Protuberans (DFSP) resection at that area followed by radiation 20 years ago. The ulcerative skin was resected and covered with oblique paraumbilical perforator flap. The histopathology examination done on excised specimen was confirmed as radiation related skin ulcer and was negative for tumour cells. Oblique paraumbilical perforator flap is ideally suited for coverage of epigastric region as done in present case. It has multiple advantages such as good matching skin quality and texture, reliable blood supply and primary closure of the donor site.

Keywords: Abdominal wall, Pedicled flaps, Perforator flap

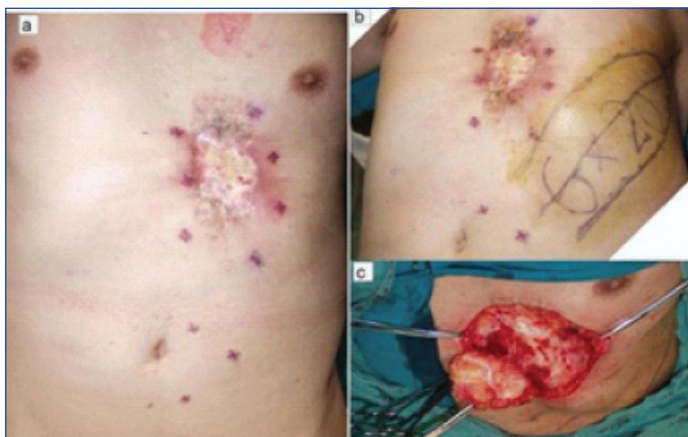CASE REPORT

A 66-year-old male presented with mild pain, itching with purulent discharge and ulcerative skin lesions on the epigastric region, which were present for about 10 years [Table/Fig-1a,b]. Despite multiple wound care management strategies, the wound did not heal. He had undergone resection for DFSP followed by postoperative RT about 20 years ago. On examination there was a central ulcer measuring 5x6 cm surrounded by scar tissue. The lesion was surrounded by hyper pigmented atrophic skin. Due to the bed being already irradiated, excision of the ulcer and reconstruction with vascularised tissue was thought to be the best option to obtain durable coverage.

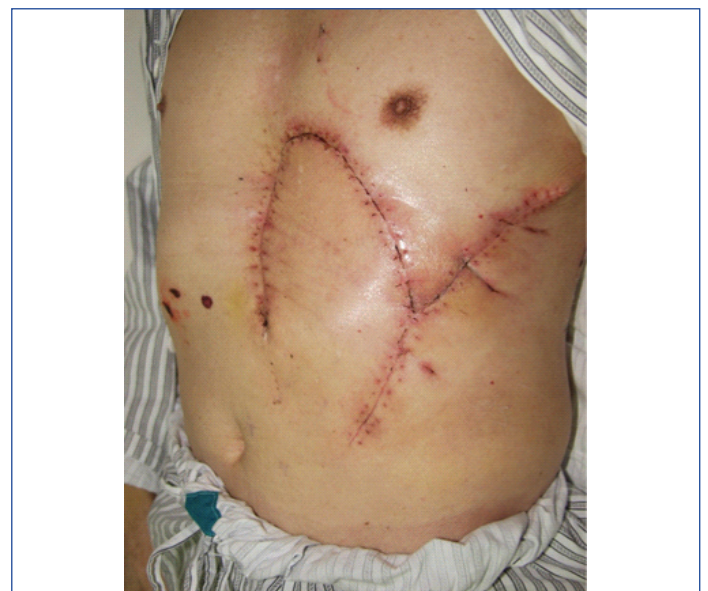The whole lesion was excised with visibly normal margins. The resultant defect measured 8x12 cm [Table/Fig-1c]. Care was taken to ensure the margins extended beyond any fibrous tissue, hallmark of chronic radiation injury. Reconstruction was done using oblique Para umbilical perforator based flap [Table/Fig-2]. The axis was marked by line joining umbilicus to the inferior angle of the scapula. We looked for perforators around the umbilicus and marked the flap based on these perforators. The wound was closed over suction drains. Patient made an uneventful recovery. At 5 year follow-up, he had no complaints of either recurrence or evidence of radiation injury. [Table/Fig-3]. The histopathology examination done on



[Table/Fig-2]: Shows the design (a), elevation (b) and placement (c) of the Pedicled Oblique Paraumbilical Perforator Flap (OPUP). (d) Shows the flap sutured.



[Table/Fig-1]: a) Non-healing epigastric ulcer; b) Shows the ulcer with flap marked for reconstruction; c) Excision of the lesion.



[Table/Fig-3]: Postoperative result showing well settled flap.

excised specimen was consistent with radiation related skin ulcer and was negative for any tumour.

DISCUSSION

RT causes skin changes ranging from dermatitis to full thickness skin necrosis. Based on the severity, National cancer Institute has graded radiation skin injury into four grades beginning from desquamation to full thickness skin necrosis [1].

Acute skin changes following RT are common and reported in up to about 95% patients while chronic skin changes are less common and the incidence is not known [2,3]. Chronic radiation dermatitis is a progressive and irreversible condition. Higher total volume and dose of radiation, single fraction radiotherapy technique without intensity modulation and large fields and postoperative radiotherapy are associated with development of chronic skin changes [3]. Other factors include concurrent chemotherapy, connective tissue disorders and host intolerance [4].

Dermatofibrosarcoma is a rare cutaneous neoplasm. It is slow growing tumour, but has multiple finger-like projections extending well beyond visible tumour [5]. Historically high recurrences were noted to be up to 55% [6]. A wide excision and postoperative RT has been shown to increase disease free survival [7]. However, RT affects each phase of the normal wound healing process—the inflammatory phase, proliferative phase, and remodelling phase. Early effects of radiation on skin include erythema, dry desquamation, hyper pigmentation and hair loss. Late effects include skin atrophy, dryness, telangiectasia, dyschromia, dyspigmentation, fibrosis, and ulcers [8]. Presence of acute skin changes has no bearing on the development of chronic skin changes in the future.

The exact underlying mechanisms leading to cell injuries are still not completely understood. Hypoxia due to progressive microvasculature endarteritis plays a central role in radiation skin injury. RT causes cellular depletion, Extracellular Matrix (ECM) alteration, micro vascular changes, cytokine and growth factor dysregulation. Ionising radiation affects cellular mitosis cellular apoptosis and a decrease in overall cell number. RT also affects collagen content and collagen strength, increase in Matrix Metalloproteinases (MMPs) causing an abnormal degradation of ECM. There is overall decrease in angiogenesis due to reduced Vascular Endothelial Growth Factor (VEGF), basic Fibroblast Growth Factor (bFGF) and Nitric oxide. The pro-inflammatory cytokines Tumour Necrosis Factor alpha (TNF- α), Interferons gamma (IFN- γ), interleukin (IL)-1, IL-6 are increased [2].

Common areas for radiation ulcer include the head, neck, chest wall, lumbar, groin, and sacral areas [9]. This follows the high incidence of radiosensitive head and neck and breast cancers. Radiation to lymph nodes leads to ulceration around the groin, axilla and neck. Grade IV radiation ulcer of the abdomen is rare and only two previous cases have been reported. [10,11], Pridgen JE and Tennisson CW reported a 58-year-old lady who had postradiation ulcer of the hypogastric region which was excised leading to full thickness anterior abdominal wall defect. Reconstruction was performed by tantalum mesh covered by pedicled flaps from lateral thigh after serial delay [10]. Görgün B and Ermiş MI in their series of 52 radiation ulcers managed by flaps, had only one case of lower abdominal wall radiation ulcer [11]. To the best of our knowledge, no case of epigastric radiation ulcer has been reported so far.

Epigastric region presents a challenge in terms of reconstruction. Primary closure is difficult in this area. While skin grafting is always possible, that leads to unaesthetic results [12]. Different flaps options are available. Random flaps can be done for smaller

defects, while larger defects would need free tissue transfer. In this current case, a moderate sized defect with paraumbilical perforator flap was managed.

In the current case, the defect was closed using the paraumbilical perforator flap. This flap and its anatomy has been well described by Naduthodikayil P et al., [13]. The paraumbilical perforators are a set of robust perforators arising from the deep inferior epigastric artery system. They perforate the rectus sheath and travel in a wheel spoke fashion. Superolaterally they travel towards the sub costal region to anastomose with the perforators of the intercostal, sub costal and lumbar perforators [13]. The flap is designed with its axis from umbilicus to the inferior border of the scapula. The flap is centered on this axis with its base at the umbilicus and extended up to anterior axillary line. Constant perforators are present at the base of the flap and routine Doppler examination is not needed [13]. The advantages of this flap include similar quality and texture of skin, robust blood supply and good arc of rotation to cover any defect on the abdominal wall. The donor site can be closed primarily. Some authors have noted hypertrophic scar to be an issue, this was not encountered in the present case [13].

CONCLUSION(S)

Skin ulceration after radiation can be difficult to manage. Full thickness excision to healthy tissues is needed, which often leads to large defects necessitating flap coverage. Radiation ulcer of the abdomen is rare. The management included excision and reconstruction by oblique pedicled paraumbilical perforator flap. This flap is ideally suited for coverage of epigastric defects.

REFERENCES

- [1] Soriano JL, Calpena AC, Souto EB, Clares B. Therapy for prevention and treatment of skin ionizing radiation damage: A review. *Int J Radiat Biol.* 2019;95(5):537-53. doi:10.1080/09553002.2019.1562254
- [2] Manna B, Cooper JS. Radiation therapy induced skin (integument) ulcer. *StatPearls [Internet].* 2019 Dec 8 [Cited 2020 Jan 5]; Available from: <https://www.ncbi.nlm.nih.gov/books/NBK507719/?report=classic>
- [3] Wei J, Meng L, Hou X, Qu C, Wang B, Xin Y, et al. Radiation-induced skin reactions: Mechanism and treatment. *Cancer Manag Res.* 2018;11:167-77. doi: 10.2147/CMAR.S188655.
- [4] Ma X, Jin Z, Li G, Yang W. Classification of chronic radiation-induced ulcers in the chest wall after surgery in breast cancers. *Radiat Oncol.* 2017;12(1):135. doi: 10.1186/s13014-017-0876-y.
- [5] Elston JB, Little A, Weinstein B, Segars KA, Smith PD. Myxoid dermatofibrosarcoma protuberans of the abdomen. *Eplasty [Internet].* 2016 Jan 4 [Cited 2020 Jan 5];16:ic1. Available from <https://www.ncbi.nlm.nih.gov/pmc/articles/PMC4711339/>.
- [6] Rockley PF, Robinson JK, Magid M, Goldblatt D. Dermatofibrosarcoma protuberans of the scalp: A series of cases. *J Am Acad Dermatol.* 1989;21(2 Pt 1):278-83. doi:10.1016/s0190-9622(89)70173-0.
- [7] Du K, Li J, Tang L, Lin X, Kong X, Liao X, et al. Role of postoperative radiotherapy in dermatofibrosarcoma protuberans: A propensity score-matched analysis. *Radiat Oncol.* 2019;14(1):20. doi:10.1186/s13014-019-1226-z.
- [8] Haubner F, Ohmann E, Pohl F, Strutz J, Gassner HG. Wound healing after radiation therapy: Review of the literature. *Radiat Oncol.* 2012;7:162. doi:10.1186/1748-717X-7-162.
- [9] Fujioka M. Surgical reconstruction of radiation injuries. *Adv Wound Care [Internet].* 2014[Cited 2020 Jan 5];3(1):25-37. Available from: <https://www.ncbi.nlm.nih.gov/pmc/articles/PMC3900101/> doi: 10.1089/wound.2012.0405.
- [10] Pridgen JE, Tennisson CW. Reconstruction of the entire anterior abdominal wall in the presence of postradiation changes. *Am J Surg.* 1956;92(1):54-56. doi:10.1016/S0002-9610(56)80011-1
- [11] Görgün B, Ermiş MI. Plastic surgery treatment of radiation induced injuries and tumors. *Eur J Plast Surg.* 1989;12:198-200. doi:10.1007/BF00219480
- [12] Kshirsagar AY, Kanetkar SR, Nikam YP, Vasisth GO. Recurrent dermatofibrosarcoma protuberans over anterior abdominal wall. *J Cutan Aesthet Surg.* 2010;3(3):167-69. doi:10.4103/0974-2077.74494.
- [13] Naduthodikayil P, Bhandari L, Sreedhar SL. Pedicled Oblique Para-Umbilical Perforator (OPUP) flap for upper limb reconstruction. *J Hand Surg Asian Pac.* 2016;21(2):229-33. doi: 10.1142/S2424835516500235.

PARTICULARS OF CONTRIBUTORS:

1. Attending Physician, Department of Plastic Surgery, The First Affiliated Hospital of Sun Yat-sen University, Guangzhou, China.
2. Resident Physician, Department of Plastic Surgery, The First Affiliated Hospital of Sun Yat-sen University, Guangzhou, China.
3. Professor, Department of Plastic Surgery, The First Affiliated Hospital of Sun Yat-sen University, Guangzhou, China.
4. Associate Professor, Department of Plastic Surgery, The First Affiliated Hospital of Sun Yat-sen University, Guangzhou, China.

NAME, ADDRESS, E-MAIL ID OF THE CORRESPONDING AUTHOR:

Dr. Liu Xiangxia,

No. 58 Zhongshan Road II, Guangzhou, Guangzhou, China.

E-mail: liuxsha@mail.sysu.edu.cn

PLAGIARISM CHECKING METHODS: [\[Jain H et al.\]](#)

- Plagiarism X-checker: Mar 24, 2020
- Manual Googling: Jun 08, 2020
- iThenticate Software: Jul 28, 2020 (12%)

ETYMOLOGY: Author Origin

AUTHOR DECLARATION:

- Financial or Other Competing Interests: None
- Was informed consent obtained from the subjects involved in the study? Yes
- For any images presented appropriate consent has been obtained from the subjects. Yes

Date of Submission: **Mar 23, 2020**

Date of Peer Review: **May 07, 2020**

Date of Acceptance: **Jun 11, 2020**

Date of Publishing: **Oct 01, 2020**