

# Morphological and Morphometric Analysis of Hypoglossal Canal and its Variations in Human Dry Skulls of North Karnataka Region

ASHWINI B NUCHHI<sup>1</sup>, SANDHYA V YATAGIRI<sup>2</sup>, SANTOSH B KARJAGI<sup>3</sup>, VIJAYA M SORGANVI<sup>4</sup>, BM BANNUR<sup>5</sup>

## ABSTRACT

**Introduction:** The Hypoglossal Canal (HC) (anterior condylar canal) is situated at the base of skull which transmits important structures. The detailed knowledge of the morphometry of HC and its variations provide important benefits in determining safe zones during surgical procedures.

**Aim:** To evaluate the effectiveness of morphometric analysis of HC, to verify the morphological characteristics for sexual dimorphism of human skull and to study any variations.

**Materials and Methods:** The present osteological analytical cross-sectional study was performed on 200 HC of 100 dry adult human crania using SPSS software 16<sup>th</sup> version. All measurements were recorded in millimeters using Digital Vernier calipers. The parameters considered for the study were: intracranial and extracranial diameters of HC; the distances between extracranial end of HC and other landmarks like basion, opisthion, anterior and posterior tips of occipital condyle; and

lower border of occipital condyle, number of HC, length of HC and relation of HC to occipital condyle on both right and left sides. Statistical analysis was done using Mean±SD, Mann-whitney test and Chi-square test.

**Results:** Extracranial diameter of HC on right side was 4.7±1.3 mm with significant p-value. Distance of extracranial end of HC to posterior end of Occipital Condyle (OC) was 14.7±2.1mm with a significant p-value, distance of extracranial end of HC to lower border of OC was 13.2±1.6mm with a significant p-value. Double HC was seen in 40% of cases -right side 13% and left side 27%. HC is located in relation to middle 1/3<sup>rd</sup> of OC in 59% on right, 66% on left side.

**Conclusion:** The morphometric and morphological parameters of HC are essential for the anthropologists to ascertain different cranial variants to different races and sexes and for the neurosurgeons to plan for various surgical interventions at cranial base.

**Keywords:** Morphological characteristics, Osteological, Surgical procedures

## INTRODUCTION

The Hypoglossal Canal (HC) (anterior condylar canal) is situated above the occipital condyle and lies a little above and antero-lateral to foramina magnum. It transmits hypoglossal nerve, meningeal branch of ascending pharyngeal artery and an emissary vein that links the basilar venous plexus internally to the internal jugular vein externally [1]. Persistent hypoglossal artery is one of the causes for intracanalicular enlargement of HC that also passes through this canal if present [2]. Number of researchers from all over the world has studied various non-metric cranial variants which showed considerable racial, regional and sexual differences which have a basic genetic control. Double HC was one of the important non metric cranial variants studied by Berry [3,4].

Language is regarded as a prerequisite for deliberative thought and action, self-awareness, or even simple sentences which distinguishes humans from other animals. Kay RF et al., and DeGusta D et al., hypothesized that the size of the HC has been associated with the evolution of language and used to date the beginning of human speech to at least 400,000 years back [5,6].

The comprehensive knowledge of the morphometry of HC and its variations provide important benefits in determining safer zones during surgical procedures at cranial base and intracranial lesions via transcondylar, supracondylar and lateral condylar approaches [7-10]. The present study was done with an aim to evaluate the morphological and morphometric analysis of HC and its variations in dry human skull.

## MATERIALS AND METHODS

The present cross-sectional osteological analytical study was performed on 200 HC of 100 dry adult human crania (50 males

and 50 females) obtained from the bone bank of department of Anatomy, BLDEU's Shri BM Patil Medical college with ethical clearance obtained from institution. Only adult skulls were included in the study, adult age was confirmed by closure of spheno-occipital synchondrosis. Skulls with any fracture or deformity in the vicinity of foramen magnum were excluded. The gender of skulls determined by morphological examination of sexually dimorphic traits described by Krogman WM et al., [11]. With mean value of distance of HC from opisthion 33.83±2.82 mm [12] at 99% confidence level, at ±1 margin of error, sample size should be at least 76 as obtained from formula. Hence, 100 skulls were included in this study.

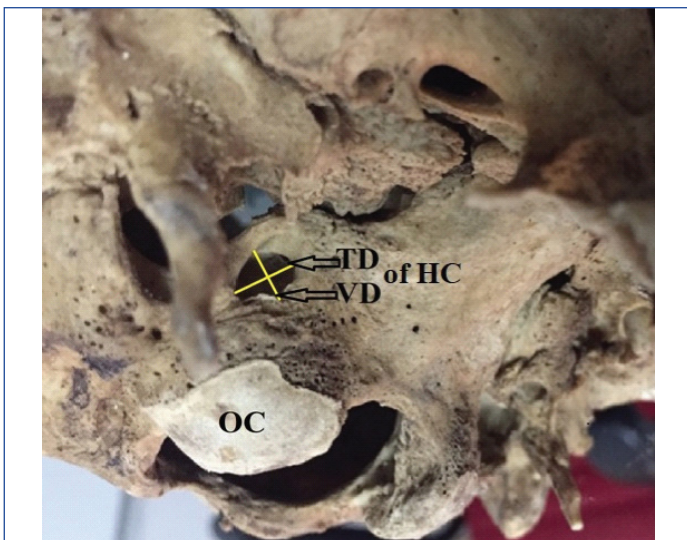All measurements were recorded in millimeters using Digital Vernier calipers.

Morphometric parameters studied:

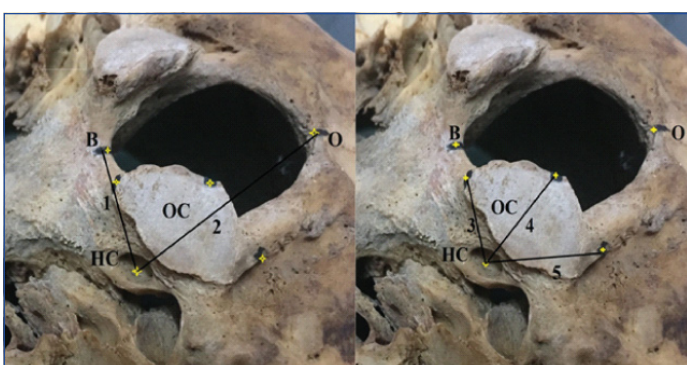
- 1) Diameters of HC at intracranial and extracranial ends [Table/Fig-1];
- 2) Length of HC;
- 3) The distances between extracranial end of HC and other landmarks including basion, opisthion, anterior and posterior tips of occipital condyle and lower border of occipital condyle [Table/Fig-2].

### Morphological Parameters Studied:


- 1) Number of HC [Table/Fig-3];
  - 2) Relation of HC to OC on both right and left sides [Table/Fig-4];
- Statistical analysis was done using SPSS software 16<sup>th</sup> version-Mean±SD, Mann-whitney test and Chi-square test were applied.




[Table/Fig-1]: Shows extracranial end of Hypoglossal canal (HC). TD-Transverse diameter, VD-Vertical diameter OC-Occipital condyle.



[Table/Fig-2]: Shows distances between extracranial end of HC and other landmarks including basion-B, opisthion-O, anterior and posterior tips of Occipital condyle (OC) and lower border of OC. 1-Distance between HC and Basion (B); 2-Distance between HC and Opisthion (O); 3-Distance between HC and anterior end of OC; 4-Distance between HC and lower border of OC; 5-Distance between HC and posterior end of OC.



[Table/Fig-3]: Shows double Hypoglossal canal (HC) and Tripartite (3 canals) HC. 1, 2, 3-no. of canals.



[Table/Fig-4]: Shows relation of HC to OC. 1-right HC; 2-left HC; 3-Foramen magnum.

**RESULTS**

In the present study various morphological and morphometric parameters were studied.

**Morphometric parameters**

The p-value is significant for following parameters-transverse diameter of extracranial end of right HC-p=0.018, distance of HC from posterior end of OC on right side-p=0.030, left-p=0.030, distance of HC from lower border of OC on right side-p=0.013, left-p=0.004 [Table/Fig-5].

| Variables                                     |                           | Mean±SD     | Mann whitney U test | Male Mean±SD | Female Mean±SD |
|---|---------------------------|-------------|---------------------|--------------|----------------|
| Extra cranial end                             | Transverse diameter-Right | 4.7±1.3 mm  | p=0.018*            | 4.9±1.1 mm   | 4.4±1.4 mm     |
|   | Left                      | 4.9±1.2 mm  | p=0.554             | 4.9±1 mm     | 4.7±1.3 mm     |
|   | Vertical diameter-Right   | 3.9±1.2 mm  | p=0.196             | 4.1±0.8 mm   | 3.8±1.8 mm     |
|   | Left                      | 3.8±0.9 mm  | p=0.215             | 3.9±0.8 mm   | 3.6±0.8 mm     |
| Intra cranial end                             | Transverse diameter-Right | 4.8±1.3 mm  | p=0.238             | 5±1.2 mm     | 4.6±1.3 mm     |
|   | Left                      | 4.3±1.5 mm  | p=0.161             | 4.6±1.6 mm   | 4.1±1.1 mm     |
|   | Vertical diameter-Right   | 3.6±1.1 mm  | p=0.893             | 3.6±1.1 mm   | 3.5±1.1 mm     |
|   | Left                      | 3.1±1.1 mm  | p=0.897             | 3.2±1 mm     | 3.1±1.1 mm     |
| Distance of HC from basion-Right              |                           | 16.2±2 mm   | p=0.477             | 16.4±1.2 mm  | 15.9±1.8 mm    |
| Left  |                           | 15.9±1.8 mm | p=0.477             | 16.2±1.7 mm  | 15.7±1.7 mm    |
| Distance of HC from opisthion-Right           |                           | 37.2±2.6 mm | p=0.129             | 37.7±2.5 mm  | 36.6±2.4 mm    |
| Left  |                           | 36.7±2.5 mm | p=0.129             | 37.3±2.4 mm  | 36±2.4 mm      |
| Distance of HC from anterior end of OC-Right  |                           | 11.2±2.2 mm | p=0.314             | 11.4±2.1 mm  | 11±2.4 mm      |
| Left  |                           | 10.9±1.9 mm | p=0.314             | 11.2±1.8 mm  | 10.6±2.1 mm    |
| Distance of HC from posterior end of OC-Right |                           | 14.7±2.1 mm | p=0.030*            | 14.7±2.1 mm  | 14.7±2.1 mm    |
| Left  |                           | 14.1±1.9 mm | p=0.030*            | 14.4±1.9 mm  | 13.9±1.8 mm    |
| Distance of HC from lower border of OC-Right  |                           | 13.3±1.5 mm | p=0.013*            | 13.6±1.4 mm  | 13.0±1.6 mm    |
| Left  |                           | 13.2±1.6 mm | p=0.004*            | 13.6±1.4 mm  | 12.7±1.7 mm    |
| Length of HC-Right                            |                           | 9.2±1.7 mm  | p=0.417             | 9.1±1.7 mm   | 9.2±1.6 mm     |
| Left  |                           | 8.9±1.7 mm  | p=0.666             | 8.8±1.3 mm   | 8.9±1.7 mm     |

[Table/Fig-5]: Shows various morphometric parameters, data was analysed using Mean±SD and Mann-Whitney test. HC-Hypoglossal canal, OC –Occipital condyle. \*Indicates significant value, p-value <0.05 is significant

**Morphological Parameters**

The number of HC and morphological parameters are depicted in [Table/Fig-6]. In 40 HC (20%) there is septa dividing the canal into two, septa may be present at intracranial or extracranial end or present throughout canal. In one of the canals there were two septae present at intracranial end dividing it into three canals as seen in [Table/Fig-3]. HC was most commonly related to middle 1/3<sup>rd</sup> of OC [Table/Fig-7].

**DISCUSSION**

The morphometric and morphological details of HC is essential for the anthropologists to ascertain different cranial variants to different races and sexes [3-5], for the neurosurgeons to plan for various surgical interventions at skull base as it is related to various neural, vascular and bony structures. HC is related superiorly to jugular tubercle, superolaterally to jugular foramen, laterally to sigmoid sinus & inferiorly to occipital condyle. The rate of mortality & morbidity

| No. of canals-              | Right     |      |        | Left      |      |        | Total |
|-----------------------------|-----------|------|--------|-----------|------|--------|-------|
|                             | Frequency | Male | Female | Frequency | Male | Female |       |
| 1                           | 86        | 43   | 43     | 73        | 38   | 35     | 159   |
| 2 at extracranial end       | 1         | 1    | 0      | 1         | 0    | 1      | 2     |
| 2 complete throughout canal | 3         | 2    | 1      | 12        | 5    | 7      | 15    |
| 2 intra cranial end         | 9         | 4    | 5      | 14        | 7    | 7      | 23    |
| 3 intra cranial end         | 1         |      | 1      |           |      |        | 1     |
| Total                       | 100       | 50   | 50     | 100       | 50   | 50     | 200   |
| Chi square test             | p=0.402   |      |        | p=.541    |      |        |       |

**[Table/Fig-6]:** Shows number of hypoglossal canals, data was analysed using Mean±SD and chi-square test.

| Relation of HC to OC             | Right     |      |        | Left      |      |        | Total      |
|----------------------------------|-----------|------|--------|-----------|------|--------|------------|
|                                  | Frequency | Male | Female | Frequency | Male | Female |            |
| Anterior 1/3 <sup>rd</sup> of OC | 41        | 17   | 24     | 34        | 17   | 17     | 75 (37.5)  |
| Middle 1/3 <sup>rd</sup> of OC   | 59        | 33   | 26     | 66        | 33   | 33     | 125 (62.5) |
| Total                            | 100       | 50   | 50     | 100       | 50   | 50     | 200        |
| Chi-square test                  | p=0.155   |      |        | p=1.00    |      |        |            |

**[Table/Fig-7]:** Shows relation of HC to OC, Showing number of hypoglossal canals, data was analysed using Mean±SD and chi-square test.  
HC: Hypoglossal canal; OC: Occipital condyle as seen in [Table/Fig-4]

increases when surgical interventions are done without detailed knowledge of this region [6-9].

Embryologically the hypoglossal nerve originates from several segments and this may result in the canal being divided into two for part or all of its length [3]. Failure to make out a bipartite or rarely a tripartite HC during drilling of the OC can lead to avoidable damage to the hypoglossal nerve; therefore it becomes a necessity to identify a bipartite or rarely, a tripartite HC by preoperative imaging [10].

Double HC as shown in [Table/Fig-3] was found in 20% of cases in the present study as compared to other studies done by Muthukumar N et al., 30%, Nikumbh RD et al., 28%, Zaidi SHH et al., 12.5%, Wysocki J et al., 43%, Osunwoke EA et al., 25.4% [10,13-16].

In the present study septa was complete throughout HC in 15 cases (7.5%) as compared to Katsuta T et al., 1-3% of cases, bony septa or notch develops between bundles of hypoglossal nerve or along dural septum of venous plexus [8].

In the present study vertical diameter x Transverse diameter of extracranial end of HC was 4.9±1.1 mm X 4.1±0.8 mm on right

side, 4.9±1.1mm X3.9±0.8mm on left side in case of male skulls whereas in the study done by Nikumbh et al., it was 6.1 mm X 5.2 mm on right side, 6.4 mm X 5.2 mm on left side. In case of female skulls it was 4.4±1.4 mm X 3.8±1.8 mm on right side, 4.7±1.3 mm X 3.6±0.8mm on left side but in study done by Nikumbh et al., it was 5.7 mm X 5.2 mm on right side, 6.1 mm X 4.9 mm on left side. The present study values were little less compared to Nikumbh RD et al., [13].

The length of HC in the present study was 9.2±1.7 mm right side, 8.9±1.7mm left side, whereas in other studies Kizilkanat ED et al., [17] 9.8±1.8 mm right, 10.0±1.9 mm left, Vinay KV et al., [18] 12.5 ±0.55mm right, 12.6±0.45mm left, present study values are less compared to other studies [17,18].

The present study values of distances of HC to various landmarks considered in the present study are similar to the values of study done by Kizilkanat ED et al., and Vinay KV et al., as seen in [Table/Fig-8] [12,17-20]. The present study values differ from other studies because of racial and regional differences in measurements [3-5].

The relation between the HC and the OC is very important for the transcondylar approaches, as HC is surrounded inferiorly by the OC and runs its way posteromedially and anterolaterally in the OC. The cortical bone around the HC is drilled away to expose the hypoglossal nerve. Drilling of bone 14 mm from the posterior border of the OC (p-value=0.030) and 13 mm from lower border of OC (p-value =0.013) does not harm the HC during posterior and lateral approaches to the craniocervical junction, as p value is significant for these two parameters in the present study. Whereas Muthukumar N, Avci E, Ozer MA have suggested 12 mm resection of OC from its posterior border is safe [10,20,21]. This difference is because of racial changes in skull measurements. So our study values can help neurosurgeons of our region to plan for skull base surgeries.

HC is located in relation to middle 1/3<sup>rd</sup> of OC in 59% on right and 66% on left side, whereas study done by Kalthur SG et al., it is 1.8% on right side and 12.5% on left side [19].

## LIMITATION

We couldn't establish statistically significant sexual differences of HC which could be possible with larger sample size.

## CONCLUSION

Even though the sample size is less the present osteological study values may help neurosurgeons particularly of north Karnataka region to plan for various surgical interventions at cranial base as the measurements may vary in different populations and may guide the anthropologists to determine different cranial variants to different races and sexes.

| Parameters                                    | Present study | Parvindokht B et al., [12] | Kizilkanat ED et al., [17] | Vinay KV et al., [18] | Kalthur SG et al., [19] | Avci E et al., [20] |
|---|---------------|----------------------------|----------------------------|-----------------------|-------------------------|---------------------|
| Distance of Hc from basion-Right              | 16.2±2        | 12.21±2.08                 | 16.6±1.8                   |                       |                         |                     |
| Left  | 15.9±1.8      | 12.69±1.57                 | 16.4±1.6                   |                       |                         |                     |
| Distance of Hc from opisthion-Right           | 37.2±2.6      | 33.56±3.07                 | 29±2.6                     |                       |                         |                     |
| Left  | 36.7±2.5      | 34.21±2.57                 | 29.1±2.4                   |                       |                         |                     |
| Distance of HC from anterior end of OC-Right  | 11.2±2.2      | 6.91±2.52                  | 11.0±1.6                   | 12.68±0.56            | 12.2±1.6                |                     |
| Left  | 10.9±1.9      | 6.95±2.43                  | 11.3±1.5                   | 12.75±0.44            | 12.2±1.5                |                     |
| Distance of Hc from posterior end of OC-Right | 14.7±2.1      | 11.17±2.34                 | 12.2±2.2                   | 12.8±0.59             | 11.0±2.2                | 9.8±1.1             |
| Left  | 14.1±1.9      | 11.69±2.68                 | 12.4±2.3                   | 12.9±0.51             | 10.4±1.7                | 9.9±1.4             |
| Distance of Hc from lower border of OC-Right  | 13.3±1.5      | 8.95±4                     | 9.4±1.1                    | 11.98±0.51            | 9.3±1.8                 |                     |
| Left  | 13.2±1.6      | 8.95±3.9                   | 9.3±1.2                    | 12.32±0.36            | 8.8±1.7                 |                     |

**[Table/Fig-8]:** Shows comparison of distance between extracranial end of HC and various landmarks like-basion, opisthion, anterior end of OC, posterior end of OC and lower margin of OC (in mm) [12,17-20].



## REFERENCES

- [1] Standring S. In: Grays Anatomy: The anatomical basis of clinical practice. 40<sup>th</sup> ed. Edinberg: Churchill Livingstone. Elsevier pub; 2008:415-25.
- [2] Wardwell AG, Goree JA, Jimenez JP. The Hypoglossal artery and hypoglossal canal. [Cited on 21 September 2016] Available from www.ajronline.org. 1973;118(3):528-33.
- [3] Berry AC, Berry RJ. Epigenic variation in the human cranium. *J Anat.* 1967;101:361-80.
- [4] Berry AC. Factors affecting the incidence of non metrical skeletal variants. *J Anat.* 1975;120(3):519-35.
- [5] Kay RF, Cartmill M, Balow M. The hypoglossal canal and the origin of human vocal behavior. *Proc Natl Acad Sci.* 1998;95:5417-19.
- [6] DeGusta D, Gilbert WH, Turner SP. Hypoglossal canal size and hominid speech. *Proc Natl Acad Sci (USA).* 1999;96(4):1800-04.
- [7] Gillsbach JM, Sure U, Mann W. The supracondylar approach to the jugular tubercle and hypoglossal canal. *Surg Neurol.* 1998;50:563-70.
- [8] Katsuta T, Matsushima T, Wen HT, Rhoton AL. Trajectory of the hypoglossal nerve in the hypoglossal canal: Significance for the transcondylar approach. *Neurol Med Chir (Tokyo).* 2000;40:206-10.
- [9] Calzada G, Isaacson B, Yoshor D, Oghalai JS. Surgical approaches to the Hypoglossal canal. *Skull Base Surgery.* 2007;17(3):187-96.
- [10] Muthukumar N, Swaminathan R, Venkatesh G, Bhanumathy SP. A morphometric analysis of the foramen magnum region as it relates to the transcondylar approach. *Acta Neurochir (Wien).* 2005;147: 889-95.
- [11] Krogman WM, Iscan MY. The human skeleton in forensic medicine, 2<sup>nd</sup> edn. Springfield Illinois: Charles Thomas publishers, 1986;189-243.
- [12] Parvindokht B, Reza DM, Saeid B. Morphometric analysis of hypoglossal canal of the occipital bone in Iranian dry skulls. *J Craniovert Jun spine.* 2015;6(3):111-14.
- [13] Nikumbh RD, Nikumbh DB, Karambelkar RR, Shewale AD. Morphological study of hypoglossal canal and its anatomical variation. *International Journal of Health Sciences & Research.* 2013;3(6):54-58.
- [14] Zaidi SHH, Gupta R, Usman N. A study of hypoglossal canal in north Indian crania. *J Anat Soc India.* 2011;60(2):224-26.
- [15] Wysocki J, Kobryn H, Bubrowski M, Kwiatkowski J, Reymond J, Skarzyska B. The morphology of the hypoglossal canal and its size in relation to skull capacity in man and other species. other species. *Folia Morphol.* 2004;63:11-17.
- [16] Osunwoke EA, Okosemiema SC, Yorkhum KL, Uzomba GC. A study on the dimensions of hypoglossal canal in Southern Nigerian Crania. *Journal of Biology, Agriculture and Healthcare.* 2014;4(4):78-81.
- [17] Kizilkanat ED, Boyan N, Soames R, Oguz O. Morphometry of the hypoglossal canal, occipital condyle, and foramen magnum. *Neurosurg Q.* 2006;16(3):121-25.
- [18] Vinay KV, Swathi, Denia MY, Sachin KS. Morphometric study of hypoglossal canal of occipital bone in dry skulls of South India. *Int J Anat Res.* 2016;4(4):3016-19.
- [19] Kalthur SG, Padmashali S, Gupta C, Dsouza AS. Anatomic study of the occipital condyle and its surgical implications in transcondylar approach. *J Craniovert Jun spine.* 2014;5(2):71-77.
- [20] Avci E, Dagtekin A, Ozturk AH, Kara E, Ozturk NC, Uluc K, et al. Anatomical variations of the foramen magnum, occipital condyle and jugular tubercle. *Turk Neurosurg.* 2011;21:181-90.
- [21] Ozer MA, Celik S, Govsa F, Ulusoy MO. Anatomical determination of a safe entry point for occipital condyle screw using three-dimensional landmarks. *Eur Spine J.* 2011;20:1510-17.

### PARTICULARS OF CONTRIBUTORS:

1. Assistant Professor, Department of Anatomy, BLDE Deemed to be University Shri B M Patil Medical College and Research Centre, Vijayapur, Karnataka, India.
2. Associate Professor, Department of Anatomy, BLDE Deemed to be University Shri B M Patil Medical College and Research Centre, Vijayapur, Karnataka, India.
3. Senior Resident, Department of Anaesthesia, BLDE Deemed to be University Shri B M Patil Medical College and Research Centre, Vijayapur, Karnataka, India.
4. Lecturer (Statistics), Department of Community Medicine, BLDE Deemed to be University Shri B M Patil Medical College and Research Centre, Vijayapur, Karnataka, India.
5. Professor and Head, Department of Anatomy, BLDE Deemed to be University Shri B M Patil Medical College and Research Centre, Vijayapur, Karnataka, India.

### NAME, ADDRESS, E-MAIL ID OF THE CORRESPONDING AUTHOR:

Dr. Ashwini B Nuchhi,  
C/O Dr Santosh B, Karjagi Ashirwad Nilaya, Plot no-17, Malaprabha Nagar, Ashram Road,  
Vijayapur-586103, Karnataka, India.  
E-mail: ashnuchhi@gmail.com

Date of Submission: **May 12, 2019**

Date of Peer Review: **Jun 14, 2019**

Date of Acceptance: **Jul 02, 2019**

Date of Publishing: **Oct 01, 2019**

FINANCIAL OR OTHER COMPETING INTERESTS: None.