

Cadaveric Study on Variations in the Formation of Extrahepatic Portion of Portal Vein

NEELESH KANASKER¹, PREETI SONJE², JANHAVI BANKAR³, VATSALASWAMY⁴

ABSTRACT

Introduction: Knowing the variations in the course of the portal vein is significant for performing surgeries of pancreas and duodenum. It is also helpful in managing the cases of traumatic rupture of mesentery. Awareness about the variations of the portal vein is critically important in surgical resection and transplantation, specifically during pre-treatment planning in order to reduce the complication rates of the surgical and radiological procedures.

Also, the comprehensive knowledge of the portal vein variations is the key issue in determining the technical feasibility of surgical interventions like liver transplant, portal vein embolization before hepatectomy as well as the postoperative management.

Aim: To study the anatomical variations of portal vein, correlate the study with clinical conditions and to give valid ontological explanation for the same.

Materials and Methods: Twenty four cadavers embalmed in 10% formalin were procured from the department of anatomy and were dissected. Variations found were meticulously cleaned and photographed.

Results: Variations seen were: formation of portal vein by the confluence of superior mesenteric, inferior mesenteric and splenic vein (1 case) also Inferior mesenteric vein terminating into superior mesenteric vein (6 cases) and many more.

Conclusion: The present study was undertaken with the intention of determining the approximate percentage of incidence of major variations in the formation of portal vein. Awareness of such variations prior to major abdominal surgeries can thus prevent massive intraoperative haemorrhage.

Keywords: Embolization, Inferior mesenteric vein, Splenic vein, Superior mesenteric vein, Transplantation

INTRODUCTION

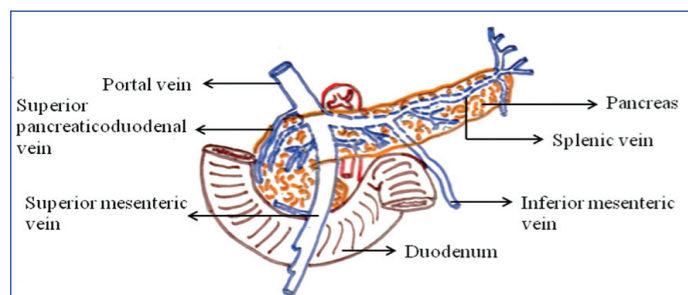
The term portal is derived from the latin word "portare" which means to carry. As the portal vein is the primitive veins recent adaptation in development of portal vein in relation with right vitelline vein appears to be modified [1].

The portal system includes almost all the veins draining the abdominal part of the digestive tube (except the lower anal canal), spleen, pancreas and gallbladder. It conveys the blood from abdominal viscera of gastrointestinal tract to the liver, where it ramifies like an artery, ending in sinusoids, from which vessels again converge to reach the inferior vena cava via hepatic veins. In adults, the portal vein and its tributaries have no valves, in foetal life and for a short postnatal period valves are demonstrable in its tributaries, usually they undergo atrophy [2].

Portal venous system of the body connects intestinal capillaries and hepatic sinusoids. The largest vessel of this system is the portal vein, which is formed by convergence of Superior Mesenteric Vein (SMV) and Splenic Vein (SV) behind the neck of pancreas at the level of L2 vertebra [3].

Portal vein measures about 8cm in length and 2cm in width. From its formation it ascends upwards and slightly to the right behind the neck of pancreas in front of inferior vena cava. It then enters the free margin of lesser omentum and reaches porta hepatis, where it divides into its right and left branches which accompany the corresponding branches of hepatic artery into the liver [4].

Between its formation and its disappearance into liver, the portal vein typically receives tributaries from stomach and upper part of pancreas and duodenum. The left gastric vein joins it in its lower part, while right gastric vein runs upwards to join it. Apart from these, portal vein also receives paraumbilical veins running along ligamentum teres in the falciform ligament [Table/Fig-1] [5]. (This figure is hand drawn, then scanned and uploaded)



[Table/Fig-1]: Figure showing normal formation of portal vein by union of splenic and superior mesenteric vein behind neck of pancreas and opening of inferior mesenteric vein into splenic vein [3].

Liver thus has dual blood supply; approximately 75% of hepatic blood flow is derived from the portal vein, while the remaining 25% is from hepatic arteries [6].

Variable patterns of formations of portal vein, its termination and tributaries of portal vein is of utmost importance in relation to surgeries of pancreas. Knowledge of such variations is helpful in radiological diagnostic procedures [7].

Aim of the present study was to study the anatomical variations in the extra hepatic portion of portal vein. As variations in the formation of portal vein are important for surgeries like liver transplant also for endovascular inter-ventionist and the diagnostic radiologist.

MATERIALS AND METHODS

After taking permission from the ethical committee this cadaveric study was carried out. Duration of this study was from April 2017 to September 2017. Twenty four cadavers (20 Males and 4 Females) embalmed in 10% formalin were procured from the Department of Anatomy of Dr DY Patil Medical College, Pune, Maharashtra, India. Inclusion criteria for study were intact and undamaged pancreas

and portal vein with its formative tributaries. Exclusion criteria were damaged portal vein without its tributaries. These cadavers were dissected to study the formation of extra hepatic portion of portal vein. As the abdomen was dissected by 1st MBBS students, anterior abdominal wall was dissected. Liver, stomach, intestines with mesentery were already removed. Further dissection was carried out as per steps given in Cunningham dissecting manual [8] Steps of the dissection were as follows: After lifting the tail of pancreas from the spleen, body of pancreas was separated from the posterior abdominal wall. Splenic vein was identified on the posterior surface of pancreas; it was followed to its junction with superior mesenteric vein to form the portal vein. Inferior mesenteric vein was also identified and traced which usually enters the splenic vein. Meticulous dissection of variations in the formation of portal vein was carried out. Different types of portal vein formations found were photographed (by using Samsung galaxy C9 pro camera) and noted down. Variable formations of portal vein were classified according to standard classification mentioned in literature [9].

STATISTICAL ANALYSIS

Chi-square test was applied for the statistical analysis and software used was Primer.

RESULTS

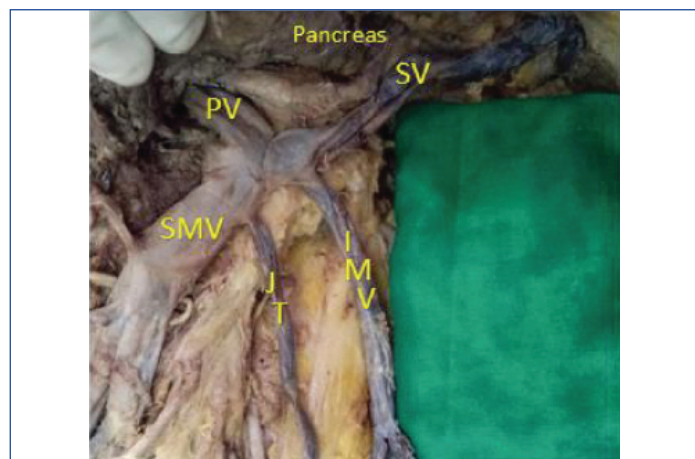
Variable formations of portal vein were studied in 24 cadavers and were classified according to standard classification mentioned in literature [9].

Different types of portal vein formations observed [Table/Fig-2]:

| Type of portal vein formation | Male | Female | Total cases | Percentage |
|-------------------------------|------|--------|-------------|------------|
| Type I | la | 2 | 14 | 58.3% |
| | lb | 1 | 6 | 25% |
| Type II | 2 | 1 | 3 | 12.5% |
| Type III | 1 | - | 1 | 4.2% |

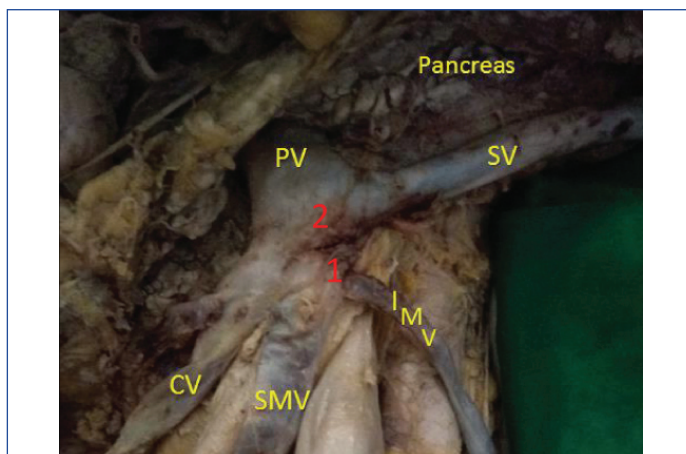
[Table/Fig-2]: Percentage of different types of portal vein formation. $\chi^2=0.627$; degrees of freedom =3; p =0.73 statistically not significant; Gender difference does not play a role in types of portal vein formation as is evident from the p-value

- Type I – Portal vein formed by confluence of superior mesenteric and splenic vein
- Subtype of Type I- according to termination of inferior mesenteric vein:
- Type Ia – Inferior mesenteric vein terminating into splenic vein (normal) [Table/Fig 3].



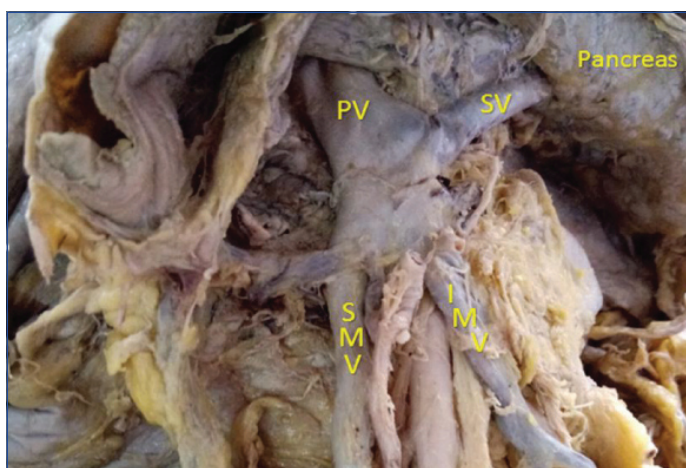
[Table/Fig-3]: Inferior mesenteric vein terminating into splenic vein (normal). PV: Portal Vein; SV: Splenic Vein; IMV: Inferior Mesenteric Vein; JT: Jejunal Tributary; SMV: Superior Mesenteric Vein

- Type Ib- Inferior mesenteric vein terminating into superior mesenteric vein [Table/Fig-4].



[Table/Fig-4]: 1) Inferior mesenteric vein terminating into superior mesenteric vein; 2) Portal vein formed by the confluence of superior mesenteric vein, splenic vein, and colic vein. PV: Portal Vein; SV: Splenic Vein; IMV: Inferior Mesenteric Vein; SMV: Superior Mesenteric Vein; CVT: Colic Vein Tributary

- Type II – Portal vein formed by the confluence of superior mesenteric, inferior mesenteric and splenic vein [Table/Fig-5].



[Table/Fig-5]: Portal vein formed by the confluence of superior mesenteric, inferior mesenteric and splenic vein. PV: Portal Vein; SV: Splenic Vein; IMV: Inferior Mesenteric Vein; SMV: Superior Mesenteric Vein

- Type III-Portal vein formed by the confluence of superior mesenteric vein, splenic vein, and colic vein [Table/Fig-4].

Out of 24 cadavers (20 males and 4 females), 20 cadavers (83.3%) showed type I formation while 3 cadavers (12.5%) showed type II formation and 1 (4.2%) showed type III formation. (Percentages were calculated according to statistical method by multiplying the decimal by the factor of 100).

Twenty cadavers which showed type I formation, type Ia formation was seen in 14 cases (12 males + 2 females) while 6 cases showed type Ib formation (5 males+1 female) [Table/Fig-2].

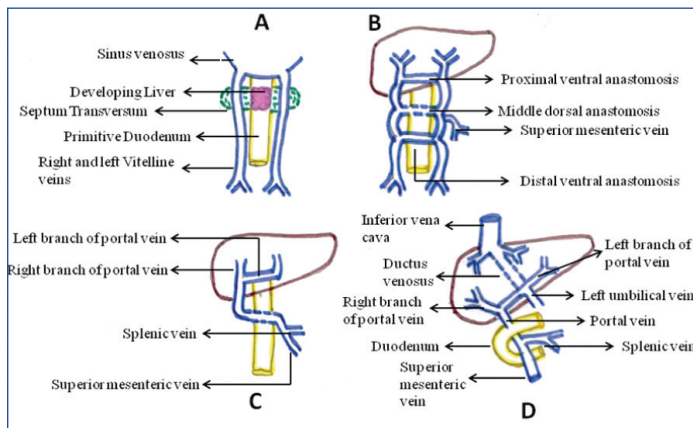
DISCUSSION

Embryological Explanation

Formation of portal vein during embryonic life is quite complicated process. In embryo, the paired primitive vitelline veins transport blood from yolk sac to the sinus venosus. During 2nd month of gestation three anastomoses are formed between the vitelline veins. Vitelline veins are having multiple bridging anastomoses on anterior and posterior aspect of developing duodenum which are cranial intrahepatically, middle behind duodenum and caudal in front of duodenum. Superior mesenteric vein joins right vitelline vein also splenic vein joins left vitelline vein near its anastomosis.

Out of these three anastomoses, the proximal ventral anastomosis become left branch of portal vein, the dorsal anastomosis forms the portal vein, while, the distal ventral anastomosis usually disappears

[Table/Fig-6] [10]. (This figure is hand drawn, then scanned and uploaded)



[Table/Fig-6]: Development of portal vein during 5th week of intrauterine life [2].

The portal vein is rarely variable. Identification of deviations from normal structure is important in hepatic surgeries as well as in diagnostic procedures. There are numerous clinical implications of portal vein variations like technically challenging operations with complex reconstruction, as well as rejection of potential donors [11], but studies on formation and anomalous course of portal vein are lacking. Considering the surgical importance of variations an attempt has been made in present study to observe and verify various formations of portal vein.

Now-a-days because of recent advances in bariatric, hepatobiliary and pancreatic surgeries, knowledge of variations in the anatomy of portal vein has become very important. This is because iatrogenic injury to portal vein post-pancreatico-duodenectomy may be life threatening as it cause massive postoperative haemorrhage. Also, the risk of injury to portal vein following blunt or penetrating abdominal trauma are real which needs its surgical repair [12]. In the treatment of pancreatic carcinoma where pancreatoduodenectomy is the treatment of choice, surgeon faces many technical challenges. The variations in the mesenteric veins pose a challenge for surgeons during pancreatoduodenectomy, mainly in cases with borderline resectable pancreatic carcinoma [13]. The complexity of these procedures further highlights the importance of extensive pre-operative knowledge of the mesenteric venous anatomy [14]. Benninger B described the new terminologies regarding normal formation of portal vein. He mentioned that inferior mesenteric vein joins splenic vein which should be atleast 3 cm before joining of superior mesenteric vein then it can be called as "splenomesentric vein". He suggested this name due to its high percentage of incidence. When inferior mesenteric vein directly joins superior mesenteric vein then this common vein is termed as "common mesenteric vein". The splenomesentric vein is informally termed as "Benninger vein". This 3 cm length of portal vein is in danger during pancreatitis, different surgeries of pancreas leading to vascular complications, surgeries for pancreatic cancer and also conditions like cholangiocarcinoma [15].

One of the rare congenital anomaly known as a preduodenal vein also has been reported few times. The important clinical significance of preduodenal vein is its association with intestinal obstruction. This can occur due to extrinsic compression of duodenum or due to intestinal malformation [16]. Preduodenal portal vein is present in first week of life in almost two-third of the children. Other associations include cardiovascular malformation, annular pancreas, and situs inversus [17]. Alternation in the pattern of obliteration of these anastomoses can result in several variants.

A prepancreatic portal vein is formed when caudal ventral anastomosis persist instead of the middle one [18]. Malunion in these anastomotic channels may result in complete or partial absence of portal system. As a result mesenteric and splenic venous flow cannot occur and may drain into renal veins, hepatic veins or directly into inferior vena cava

which may lead to poor perfusion of the liver [19]. Not only have the variations in the formation of portal vein and its tributaries, but also the angulations of portal vein with the vertical plane had clinical relevance. Three types have been mentioned in previous literature [20].

a) Oblique Tract- most common which is found in 60% cases where portal vein makes an angle of 45 degrees with vertical plane.

b) Vertical Tract – seen in 35% cases. In this case portal vein makes an angle of 10-30 degree with vertical plane.

c) Horizontal – 35% cases show this type where angle formed between portal vein to vertical plane is 75 to 80 degree [20].

The clinical significance of this formation of angle of portal vein on MR angiogram can be put as that, flow areas exist and may lead to signal loss while performing MRA on the portal system. Signal loss is a very common occurrence at the portal confluence; where mixing of blood takes place from splenic vein and superior mesenteric vein which commonly meet together at nearly right angles [21]. The oblique orientation of the portal vein often makes it difficult to be assessed in the transverse on MR angiogram [22,23].

Welch have taken into consideration the fact that the portal vein present in the anterior lip of epiploic foramen while inferior vena cava is present in the posterior lip of epiploic foramen, both run parallel to each other at the upper border of pancreas and lower border of liver where they can be used to perform side to side anastomosis between the two [22,24]. As the portal vein normally lies behind the hepatic artery and common bile duct the abdominal approach for this procedure is difficult. To carry out this delicate anastomosis behind hepatic artery and bile duct thoracoabdominal approach is easiest and safe for proper visualization and handling of these structures [24].

CONCLUSION

As there is limited literature on the portal vein formation, this study will contribute about extra knowledge regarding formation of portal vein. Three different types of formations of portal vein were observed in the present study. This will help the surgeons during hepatic and pancreatic surgeries. Thus literature about the variant portal vein anatomy is of deep importance taking into consideration its clinical point of view.

ACKNOWLEDGEMENTS

I would like to thank my Head of Department Professor (Dr. P.R. Manvikar) and laboratory attendants, Deepak and Amol for their help in this study.

REFERENCES

- Neal V, Rand WH. Comparative anatomy In: The Vascular System – The Evolution of Veins. 2nd ed. London: H.K. Lewis and Co. Ltd.; 1943.
- Singh V. Textbook of clinical embryology. 2nd ed. Elsevier publication; 2017; Pp-242.
- Gray H. The Anatomical Basis of Medicine and Surgery. 40th ed. Susan Standing, Elsevier Churchill Livingstone; 2008; Pp.1187.
- Datta AK. Essentials of Human Anatomy. Thorax and Abdomen. 7th ed. Current Books International Kolkata, 2006; Pp.244-247.
- Hollinsheads Textbook of Anatomy. 5th ed. Lippincott-Raven Publishers, Philadelphia, New York; 1997; Pp. 557.
- Pilino Rossi, L. Broglia Portal Hypertension: Diagnostic Imaging and Imaging Guided Therapy. Berlin: Springer. (2000) pg.51.
- Manjunatha YC, Beeregowda YC, Bhaskaran A. An unusual variant of the portal vein. Journal of Clinical Diagnostic Research. 2012;6(4):731-33.
- Romanes GJ. Cunningham's Manual of Practical Anatomy. 15th ed. Vol 2. New York: Oxford Medical Publications; 1986; p.149-153.
- Chaijaroonkhanarak W, Woraputtaporn W, Amartayakong P, Umka J, Brown K, Pannangrong, et al. Length, diameter and variations in types of portal vein formations in northeastern Thais. Srinagarind Medical Journal. 2010;25(4):323-27.
- Sadler TW. LANGMAN'S Medical Embryology. 11th ed. Philadelphia: Lippincott Williams and Wilkins; 2010; pp. 192-93.
- Guler N, Dayangae M, Yaprak O, Akyildiz M, Gunay Y, Taskesen F, et al. Anatomical variations of donor portal vein in right lobe living donor liver transplantation: The safe use of variant portal vein. Transpl Int. 2013;26:1191-97.
- Mantovani M, Leal RF, Fontelles MJ. Anatomic study of portal vein: Trans pancreatic vessels injuries approach. Acta Cir Bras. 2002;17(4):225-31.

- [13] Vauthey JN, Dixon E. AHPBA/SSO/SSAT consensus conference on resectable and borderline pancreatic cancer: Rational and overview of the conference. *Ann Surg*. 2009;16(7):1725-26.
- [14] Kim HJ, Ko YT, Lim JW, Lee DH. Radiological anatomy of the superior mesenteric vein and branching patterns of the first jejunal trunk: evaluation using multidetector row CT venography. *Surg Radiol Anat*. 2007;29(1):67-75.
- [15] Benninger B. Splenomesenteric vein: formally recognising a clinically relevant section of the portal venous drainage system. *Folia Morphologica*. 2013;72(1):63-66.
- [16] Stevens JC, Morton D, McElwee R, Hamit HF. Preduodenal portal vein: Two cases with differing presentation. *Arch Surg*. 1978;113:311-13.
- [17] Choi SO, Park WH. Preduodenal portal vein: A cause of prenatally diagnosed duodenal obstruction. *J Pediatr Surg*. 1995;30:1521-22.
- [18] Covey AM, Bordy LA, Getrajdman GI, Sofocleous CT, Brown KT. Incidence, pattern and clinical relevance of variant portal vein anatomy. *Am J Roentgenol*. 2004;183:1055-64.
- [19] Noe JA, Pittman HC, Burton EM. Congenital absence of the portal Vein in a child with Turner Syndrome. *Pediatr Radiol*. 2006;36:566-68.
- [20] Sztika D, Zahoi DE, Motoc A, Ureche MF, Daescu E. Anatomical variations of the hepatic portal vein associated with incomplete celiac trunk. *Rom J Morphol Embryol*. 2011;52(2):695-98.
- [21] Leyendecker JR, Rivera E Jr, Washburn WK, Johnson SP, Diffin DC, Eason JD. MR angiography of the portal venous system: Techniques, interpretation and clinical applications. *Radiographics*. 1997;17:1425-43.
- [22] Kaur H, Singh M, Bajaj AS. A cadaveric study of morphology of portal vein with its clinical importance. *Med J DY Patil Univ*. 2016;9:336-40.
- [23] Rodgers PM, Ward J, Baudouin CJ, Ridgway JP, Robinsons PJ. Dynamic contrast enhanced MR imaging of the portal venous system: Comparison with x-rays angiography. *Radiology*. 1994;191:741-45.
- [24] Welch CS. A technique for portacaval anastomosis. *Surg Gynecol Obstet*. 1947;85:492-94.

PARTICULARS OF CONTRIBUTORS:

1. Associate Professor, Department of Anatomy, Dr. D.Y.Patil Medical College, Pune, Maharashtra, India.
2. Associate Professor, Department of Anatomy, Dr. D.Y.Patil Medical College, Pune, Maharashtra, India.
3. MBBS Student, aDr. D.Y.Patil Medical College, Pune, Maharashtra, India.
4. Professor, Department of Anatomy, Dr. D.Y.Patil Medical College, Pune, Maharashtra, India.

NAME, ADDRESS, E-MAIL ID OF THE CORRESPONDING AUTHOR:

Dr. Preeti Sonje,
Dr D Y Patil Medical College, Sant Tukaram Nagar, Pimpri Colony, Pune-411018, Maharashtra, India.
E-mail: drpreetisalgar@gmail.com

Date of Submission: **Sep 14, 2018**Date of Peer Review: **Oct 06, 2018**Date of Acceptance: **Apr 20, 2019**Date of Publishing: **Jul 01, 2019****FINANCIAL OR OTHER COMPETING INTERESTS:** None.