

# Morphological and Morphometric Study of Foramen Magnum in Dry Human Skull and Its Clinical Significance

ARCHANA SINGH<sup>1</sup>, PREETI AGARWAL<sup>2</sup>, ARUN SINGH<sup>3</sup>

## ABSTRACT

**Introduction:** Foramen Magnum (FM) is present at the lower part of the occipital bone. It is a very important landmark for the anthropology, anatomy, forensic medicine, surgeons and other medical field for the skull base.

**Aim:** To observe the shape of foramen magnum and to measure the various morphometric parameters.

**Materials and Methods:** Morphological and morphometric study was done on 120 dry human skulls. Digital Vernier caliper was used for measurement. The shape of foramen magnum was noted and classified as oval, round, tetragonal, pentagonal, hexagonal and irregular in shape. Morphometric measurements like antero-posterior diameter, transverse diameter were measured and Foramen magnum index was calculated.

Statistical analysis was done and minimum, maximum mean and standard deviation was calculated.

**Results:** The most common shape of FM was oval in 40 (33.3%) skulls; followed by tetragonal in 20 (16.6%) skulls and hexagonal in 20 (16.6%) skulls. Round shaped FM was present in 16 (13.3%) skulls, pentagonal FM in 16 (13.3%) and pear shaped FM was present in 8 (6.6%) skulls. The mean of Anteroposterior (AP) diameter was  $33.79 \pm 2.60$  mm; transverse diameter was  $28.25 \pm 1.83$  mm and foramen magnum index was  $83.91 \pm 6.43$ .

**Conclusion:** The Knowledge of size and shape of foramen magnum is helpful to neurosurgeons in cranio-vertebral surgical approaches as well as in posterior cranial fossa surgeries. Data of present study may be helpful to neurosurgeons, anthropologist or forensic persons.

**Keywords:** Anthropology, Foramen magnum index, Occipital bone, Posterior cranial fossa

## INTRODUCTION

The posterior part of the inferior surface of the skull is formed by the occipital bone. Prominent features of posterior part of inferior surface are the foramen magnum and associated occipital condyles, jugular foramen, mastoid notch and the squamous part of the occipital bone up to the external occipital protuberance and the superior nuchal lines, hypoglossal canals (anterior condylar canals) and condylar canals (posterior condylar canals) [1]. The foramen magnum is situated in an antero-median position in the occipital bone and communicates into the posterior cranial fossa. It is oval in shape which is wider from behind. It is greatest in its dimensions anteroposteriorly. Posterior part of foramen magnum known as neurovascular compartment which contains the lower end of the medulla oblongata, meninges, cerebrospinal fluid, vertebral vessels and the accessory nerves; anterior part of it is known as osseo-ligamentous compartment through which the cruciate ligament, apical ligament of the dens and the tectorial membrane pass and attach to the internal aspect of basi-occiput [1]. Occipital condyles overhang the anterior margin of foramen magnum which articulates with the lateral masses of first cervical vertebrae and forms the Atlanto-occipital joint. Occipital condyles are oval shape and lie obliquely so, its anterior end lies nearer to the midline than its posterior end. Condyles are more convex antero-posteriorly than transversely. There is roughened impression on its medial aspect because of ligamentous attachments [1].

Basilar process of the occipital bone forms the anterior border, right and left ex-occipitalis form the lateral margin and supraoccipital part of occipital bone form the posterior border of foramen magnum [2]. Area around foramen magnum tends to withstand the physical insult because of thick cranial base and protected anatomical position [3].

Vital structures which pass through the foramen magnum, may suffer compression in cases of foramen magnum brain herniation and achondroplasia of foramen magnum [4-6]. Various neurosurgical approaches were described for skull base surgeries

like anterior, anterolateral, lateral, posterolateral and trans condylar approaches [7-9].

Variations in the shape of the foramen magnum have clinical as well as radiological significance.

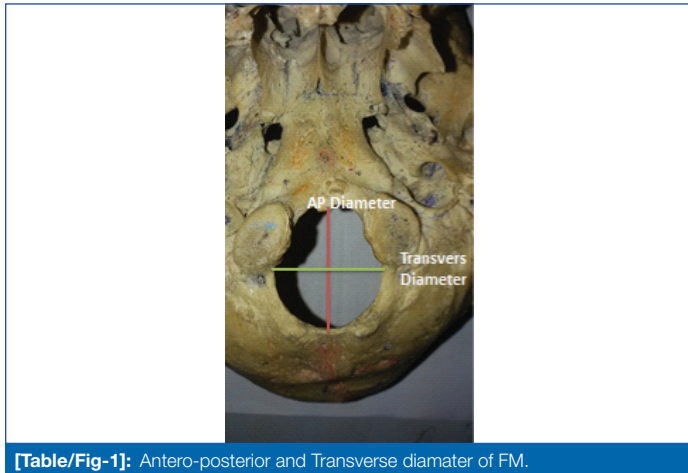
The knowledge of the dimensions and shape of the foramen Magnum has important clinical implications in the prognosis and treatment of various neurological pathologies like Arnold Chiari syndrome, and posterior cranial fossa lesions [10]. Similarly, dimensions of the foramen magnum are important in various surgical approaches to posterior cranial fossa through foramen magnum. Thus, understanding of the variations in its normal anatomy is essential for accurate diagnosis and treatment of same. Hence, the present study was done to determine and analyse the morphological types and diameters of the Foramen magnum in adult skull of Indian population so that the data can help in improving the efficacy and minimize the failure rates in surgical procedures in posterior cranial fossa particularly those involving the approaches through foramen magnum.

## MATERIALS AND METHODS

This observational study was carried out on 120 undamaged dry adult human skulls of unknown age and gender, in duration of three months. Specimens were collected from the Department of Anatomy and Department of Forensic Medicine and Toxicology. Only fully ossified, dried, macerated and thoroughly cleaned skull were included in the study while the skulls which were damaged and those having any deformity or pathology like healed fractures were excluded. The shape of foramen magnum was noted and classified as oval, round, tetragonal, pentagonal, hexagonal and irregular in shape. The number and incidence of each type in the studied skull was registered and tabulated. Various morphometric measurements like antero-posterior diameter and transverse diameter of foramen magnum were taken using the Digital Vernier sliding caliper which is accurate to 0.01 millimeter. The mean and standard deviation of the foramen magnum in various dimensions were calculated.

**Antero-posterior Diameter (APD):** measured from the end of anterior border (basion) to the end of posterior border (opisthion) of foramen magnum [Table/Fig-1].

**Transverse Diameter (TD):** measured from the point of maximum concavity on the right margin to the maximum concavity on left margin of foramen magnum [Table/Fig-1].



[Table/Fig-1]: Antero-posterior and Transverse diameter of FM.

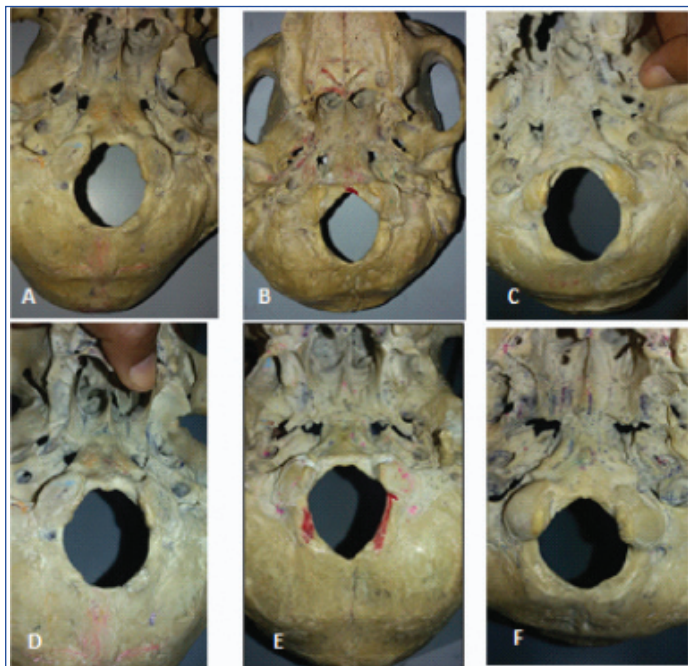
**Foramen Magnum Index (FMI):** was calculated by dividing the transverse diameter by AP diameter and multiplied by hundred.

## STATISTICAL ANALYSIS

The data was analysed using SPSS version 22.0. Mean, maximum and minimum values along with standard deviation were derived.

## RESULTS

In the present study various shapes of foramen magnum were observed. The most common shape was oval in 40 (33.3%) skulls; followed by tetragonal shape in 20 (16.6%) skulls and hexagonal in 20 (16.6%) skulls. Round shaped FM was present in 16 (13.3%) skulls, pentagonal FM in 16 (13.3%) and pear shaped FM was present in 8 (6.6%) skulls [Table/Fig-2,3].



[Table/Fig-2]: Different shapes of foramen Magnum observed in present study. A: OVAL; B: TETRAGONAL; C: HEXAGONAL; D: ROUND; E: PENTAGONAL; F: PEAR

The mean of anteroposterior (AP) diameter was  $33.79 \pm 2.60$  mm; transverse diameter  $28.25 \pm 1.83$  mm and foramen magnum index was  $83.91 \pm 6.43$  [Table/Fig-4]. The mean AP diameter, transverse diameter and FM index values for each shape of Foramen Magnum is depicted in [Table/Fig-5].

Shape	Number	Percentage
Oval	40	33.3
Tetragonal	20	16.6
Hexagonal	20	16.6
Round	16	13.3
Pentagonal	16	13.3
Pear	8	6.6
Irregular	-	-
Total	120	100

[Table/Fig-3]: Shapes of foramen magnum.

Total Number (N)-120	Antero-Posterior Diameter (mm)	Transverse Diameter (mm)	Foramen Index
Mean $\pm$ SD	$33.79 \pm 2.60$	$28.25 \pm 1.83$	$83.91 \pm 6.43$
Minimum	30.05	24.25	71.88
Maximum	40.07	32.32	97.94

[Table/Fig-4]: Dimensions of foramen magnum.

Shape	Number N (%)	Mean A-P Diameter (mm) $\pm$ SD	Mean Transverse Diameter (mm) $\pm$ SD	Mean Foramen Index $\pm$ SD
Oval	40 (33.3%)	$35.64 \pm 2.68$	$28.46 \pm 2.11$	$80 \pm 5.12$
Tetragonal	20 (16.6%)	$33.70 \pm 2.08$	$28.96 \pm 2.32$	$85.95 \pm 4.83$
Hexagonal	20 (16.6%)	$33.89 \pm 1.96$	$27.21 \pm 0.58$	$80.49 \pm 4.24$
Pentagonal	16 (13.3%)	$31.46 \pm 1.32$	$29.11 \pm 0.77$	$92.69 \pm 5.30$
Round	16 (13.3%)	$33.25 \pm 1.42$	$28.22 \pm 1.57$	$84.98 \pm 1.89$
Pear	8 (6.6%)	$30.26 \pm 0.09$	$26.40 \pm 0.99$	$87.24 \pm 3.53$

[Table/Fig-5]: Mean dimensions of foramen magnum according to shape.

## DISCUSSION

Evaluation of foramen magnum is important for neurosurgical approaches, forensic, radiological evaluations and for evolutionary studies. Regarding the shape of foramen magnum, oval shape was described as the most common in occurrence. In the present study also oval shape was most common shape of foramen magnum (33.3%). Many other studies also reported oval shaped foramen magnum [11,12]. However, Chethan P et al., found rounded FM, Aragão JA et al., reported pear shape and Sindel M et al., reported tetragonal shape as a common shape [Table/Fig-6] [13-15]. In the present study sagittal (A-P diameter) diameter of Foramen magnum was  $33.79 \pm 2.60$  mm which were consistent with the findings of Sampada PK et al., Jasuja VR et al., while Gruber P et al., and Osunwoke EA et al., reported higher values than the present study [12,16-18]. In the present study transverse diameter (width) of foramen magnum was  $28.25 \pm 1.83$  mm which were in accordance with the other studies by Sampada PK et al., Jasuja VR et al., Osunwoke EA et al., Tubbs RS et al., [12,16,18,19], while Gruber P et al., reported slightly higher values [Table/Fig-7] [17].

The average value of foramen magnum index obtained in present study was  $83.91 \pm 6.43$ . Chaturvedi RP et al., and Howale DS et al., studied Indian skulls and reported the average value of foramen magnum index as 83.81 and  $84.85 \pm 4.77$  respectively, which was congruent with this study [20,21]. Many radiological morphometrical studies of FM were done. Bello SS et al., evaluated FM by CT scan and reported mean A-P diameter as  $34.3 \pm 4.1$  mm and mean transverse diameter  $30.1 \pm 3.1$  mm [22]. Kanodia G et al., evaluated the dimensions of FM in dry skull as well as in living by CT scan, they reported AP diameter as  $34.1 \pm 2.9$  mm and transverse diameter as  $27.5 \pm 2.5$  mm in dry skull while there was no significant difference between the morphometric values of dry skull and CT scan group in transverse diameter and surface area but AP diameter of dry skull was larger than CT scan group [Table/Fig-8] [23].

## LIMITATION

The sample size of the present study was small, study was done on dry human skull and no sexual differentiation was done.

Shape	Radhakrishnan SK et al., [11]	Chethan P et al., [13]	Aragão JA [14]	Sampada PK et al., [12]	Present Study
Oval	39% (39)	15.1% (8)	5.5% (6)	58%	33.3% (40)
Round	28% (28)	22.6% (12)	15.5% (17)	9%	13.3% (16)
Tetragonal	19% (19)	18.9% (10)	15.5% (17)	8%	16.6% (20)
Pentagonal	14% (14)	3.8% (2)	2.7% (3)	1%	13.3% (16)
Hexagonal	-	5.61% (3)	9.1% (10)	1%	16.6% (20)
Pear	-	-	37.3% (41)	-	6.6% (8)
Irregular	-	15.1% (8)	6.4% (7)	10%	-
Egg	-	18.9% (10)	-	11%	-
Biconvex	-	-	10.9% (12)	-	-
Heptagonal	-	-	1.8% (2)	-	-
% (Total Number)	-	100% (53)	100%	-	100% (120)

**[Table/Fig-6]:** Comparison of shape of foramen magnum with different studies.

Authors	Numbers (n)	Mean A-P diameter (mm)±SD	Mean transverse diameter (mm)±SD
Gruber P et al., (Switzerland) [17]	110	36.6±2.8	31.1±2.7
Tubbs RS et al., [19]	72	31	27
Osunwoke EA et al., (Nigeria) [18]	120	36.11±2.60	29.56±2.60
Chethan P et al., (Turkey)[13]	53	31±2.4	25.2± 2.4
Jasuja VR et al., [16]	100	34.13±2.73	27.82±3.32
Sampada PK et al., [12]	100	34.84±2.32	29.39±1.73
Present study	120	33.79±2.60	28.25±1.83

**[Table/Fig-7]:** Comparison of A-P diameter and transverse diameter of foramen magnum.

	N (number)	Mean A-P diameter mm±SD	Mean transverse diameter mm±SD
Bello SS et al., (CT sacn) [22]	240	34.3±4.1	30.1±3.1
Kanodia G et al., (CT scan) [23]	100	33.1±3.5	27.6±3.1
Kanodia G et al., (dry skull) [23]	100	34.1±2.9	27.5±2.5
Present study (dry skull)	120	33.79±2.60	28.25±1.83

**[Table/Fig-8]:** Comparison of dimensions of foramen magnum by various methods.

## CONCLUSION

Although the sample size of present study is small but morphometric and morphological analysis and values of present study may help the anatomists, radiologist, and neurosurgeons for posterior cranial fossa surgical approaches. As the morphology and morphometry of foramen magnum varies in sexes and races, it has some evolutionary importance also.

## REFERENCES

- [1] Standarding S. Gray's anatomy. The anatomical basis of clinical practice. 41th ed. London: Elsevier Churchill Livingstone; 2016;422.
- [2] Scheuer L, Black S. The Juvenile Skeleton. Elsevier, London, 2004;1-19.

- [3] Ferreira FV, Rosenberg B, da Luz HP. The "Foramen Magnum" Index in Brazilians. Rev Fac Odontol Sao Paulo. 1967;5(4):297-302.
- [4] Hecht JT, Horton WA, Reid CS, Peyeritz RE, Chakraborty R. Growth of the foramen magnum in achondroplasia. Am J Med Genet. 1989;32(4):528-35.
- [5] Reich JB, Sierra J, Camp W, Zanzonico P, Deck MD, Plum F. Magnetic resonance imaging measurements and clinical changes accompanying transtentorial and foramen magnum brain herniation. Ann Neurol. 1993;33(2):159-70.
- [6] Ropper AH. MRI demonstration of the major features of herniation. J NeurolNeurosurg Psychiatry. 1993;56:932-35.
- [7] Cornu P, Hentati K, Chabolle F, Zouaoui A, Tamisier D, Hidden G, et al. Lateral approach to the foramen magnum. SurgRadiol Anat. 1990;12(1):77-78.
- [8] George B, Lot G. Anterolateral and posterolateral approaches to the foramen magnum: technical description and experience from 97 cases. Skull Base Surg. 1995;5(1):9-19.
- [9] Muthukumar N, Swaminathan R, Venkatesh G, Bhanumathy SP. A morphometric analysis of the foramen magnum region as it relates to the transcondylar approach. Acta Neurochir (Wien). 2005;147(8):889-95.
- [10] Murshed KA, Cicekcibasi AE, Tuncer I. Morphometric evaluation of the foramen magnum and variations in its shape: A study on computerized tomographic images of normal adults. Turk J Med Sci.2003;33:301-06.
- [11] Radhakrishna SK, Shivarama CH, Ramakrishna A, Bhagya. Morphometric Analysis of Foramen Magnum for Sex Determination in South Indian Population. NUJHS.2012;2(1):20-22.
- [12] Sampada PK, Poornima B, Mallikarjun M, SakriSB. Morphometric and morphological study of foramen magnum in dried human skull bones. Int J Anat Res. 2017;5(2.1):3682-86
- [13] Chethan P, Prakash KG, Murlimanju BV, Prashanth KU, Prabhu LV, Saralaya VV et al. Morphological analysis and morphometry of the foramen magnum: an anatomical investigation. Turk Neurosurg. 2012;22(4):416-19.
- [14] Aragão JA, de Oliveira PereiraR, da Cruz de MoraesRZ, ReisFP. Morphological types of foramen magnum. Annual Research & Review in Biology. 2014;4(9):1372-78.
- [15] SindelM, Özkan O, Uçar Y, Demir S. Foramen Magnum'unAnatomikVaryasyonları. AkdenizÜniversitesiTıpFakültesiDergisi. 1989;44(6):97-102.
- [16] Jasuja VR, Kulkarni PG, Borate SM, PurnaniSR. A morphometric study of occipital condyles and foramen magnum in adult skull base in western Maharashtra region of India. Int J Anat Res. 2016;4(1):1846-50.
- [17] Gruber P, Henneberg M, Boni T, Ruhli FJ. Variability of human foramenmagnum size. Anat Rec (Hoboken). 2009;292(11):1713-19.
- [18] Osunwoke EA, Oladipo GS, Gwunireama IU, Ngaokere JO. Morphometric analysis of the foramen magnum and jugular foramen in adult skulls in southern Nigerian population. Am J Sci Ind Res. 2012;3(6):446-48.
- [19] Tubbs RS, Griessenauer CJ, Loukas M, Shoja MM, Cohen-Gadol AA. Morphometric analysis of the foramen magnum: an anatomic study. Neurosurgery. 2010;66(2):385-88.
- [20] Chaturvedi RP, Harneja NK. A craniometric study of human skull. Journal of Anatomical Society of India.1963;12:93-96.
- [21] Howar DS, Bathija D, Pandit DP. Correlation between cranial index and foramen magnum index in human dried skulls. GJRA. 2014;3(1):3-6.
- [22] Bello SS, Zagga AD, Kalale SB, Usman JD, Bello A, Abdulhameed A, et al. Measurements of foramen magnum using computerised tomography in Sokoto State, Nigeria. International Journal of Health and Medical Information. 2013;2(2):29-35.
- [23] Kanodia G, Parihar V, Yadav YR, Bhatele PR, Sharma D. Morphometric analysis of posterior fossa and foramen magnum. J Neurosci Rural Pract. 2012;3(3):261-66.

### PARTICULARS OF CONTRIBUTORS:

1. Assistant Professor, Department of Anatomy, Rohilkhand Medical College and Hospital, Bareilly, Uttar Pradesh, India.
2. Assistant Professor, Department of Anatomy, Varun Arjun Medical College and Rohilkhand Hospital Banthra, Shahjahanpur, Uttar Pradesh, India.
3. Professor and Head, Department of Community Medicine, Rohilkhand Medical College and Hospital, Bareilly, Uttar Pradesh, India.

### NAME, ADDRESS, E-MAIL ID OF THE CORRESPONDING AUTHOR:

Dr. Preeti Agarwal,  
Department of Anatomy, Varun Arjun Medical College and Rohilkhand Hospital Banthra, Shahjahanpur, Uttar Pradesh, India.  
E-mail: Preetianat@gmail.com

Date of Submission: **Feb 20, 2019**

Date of Peer Review: **Mar 15, 2019**

Date of Acceptance: **Apr 20, 2019**

Date of Publishing: **Jul 01, 2019**

FINANCIAL OR OTHER COMPETING INTERESTS: None.