

A Study of Morphometric Analysis of Condyles of Adult Dry Femur of Humans in Gujarat Region

HIREN S. CHAVDA¹, NISHITA K JETHVA², SUDARSHAN GUPTA³

ABSTRACT

Introduction: The knee joint is one of the major joint of our body and lower end of femur forms important component of it. Knee joint is also commonly operated for replacement surgeries. In such cases, measurements of lower end of femur has great importance in designing of implants. Prosthesis based on accurate morphometric data of components of knee; femur and tibia, plays a crucial role, which will ensure early mobility as well as fewer complications after arthroplasty.

Aim: To obtain certain morphometric data of femoral condyles by direct method and to determine differences on right and left side.

Materials and Methods: Seventy four adult dry femur bones of unknown sex were studied. Bicondylar width, maximum anteroposterior distance of medial and lateral condyle, maximum transverse distance of medial and lateral condyle and intercondylar notch width were measured with the help of

vernier caliper and mean, standard deviation and p-value were calculated using unpaired t-test.

Results: Average bicondylar width was 69.70 ± 4.96 mm. Average anteroposterior distance of medial and lateral condyle was 53.17 ± 4.56 mm and 54.87 ± 4.13 mm respectively. Average transverse distance of medial and lateral condyle was 26.79 ± 2.16 mm and 29.93 ± 2.58 mm respectively. Average intercondylar notch width was found to be 19.57 ± 2.96 mm. In the present study; except for the intercondylar notch width ($p < 0.05$), other parameters did not show any significant differences between right and left side ($p > 0.05$).

Conclusion: Present study provides important morphometrical data of femoral condyles by direct method. This will help in adding the knowledge of morphometric data of various parameters in designing of implants and selection of suitable prosthesis for better outcome of knee replacement surgeries.

Keywords: Femoral condyle, Knee joint, Knee prosthesis, Morphometry

INTRODUCTION

The knee joint is a complex variety of synovial joint in which lower end of femur articulates with the upper end of tibia and patella forming femorotibial and femoropatellar articulations respectively. Anteriorly articular surfaces of both femoral condyles are continuous with each other but posteriorly they are separated by the intercondylar notch/fossa [1,2].

There is an increase in the incidence of osteoarthritis affecting knee joint with advancing age and also in obese persons. As osteoarthritis is a very painful condition it adversely affects the day to day activities of the patient. Total Knee Arthroplasty (TKA)/Total Knee Replacement (TKR) are beneficial in patients with severe osteoarthritis. Success of this operation largely depends on accurate size and proper selection of prosthesis as well as proper placing of components [3,4].

For designing of total joint replacement and internal fixation, anatomy of femoral condyles is very important [5]. Morphometric studies have been conducted by indirect methods of measurements like radiography, computerized tomography or magnetic resonance imaging [6-9]. However, even after correcting the magnification, technique and projection, it is found that these indirect methods are inaccurate [10-12]. Mismatch of selected prosthesis may lead to complications like loosening of implant or impingement of surrounding soft tissue [13].

To maintain normal functional range of knee joint, it is very essential to use the appropriate size of femoral component [13,14]. Selection of proper implant size is challenging, particularly for Asian population, as current implants are not designed according to the ethnic difference [15]. Differences between genders and among ethnic groups have also been emphasized. Among Asian and Caucasian population, it is suggested by several authors that, for Asian population, smaller size components will be more suitable [6,16,17]. Therefore, present study

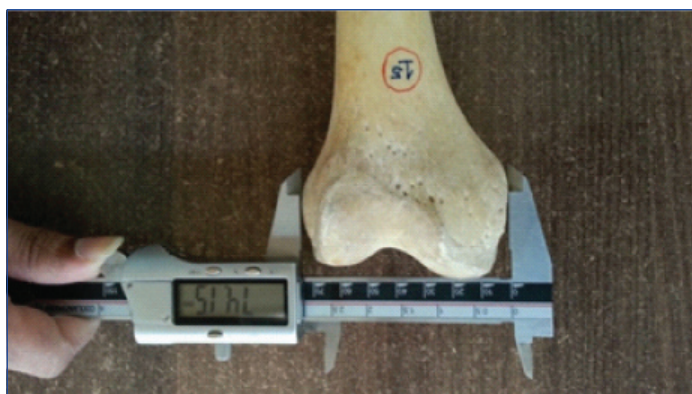was conducted to obtain morphometric data of femoral condyles which will help in selection of appropriate size of implant and will improve the prognosis after replacement surgeries involving knee joint.

MATERIALS AND METHODS

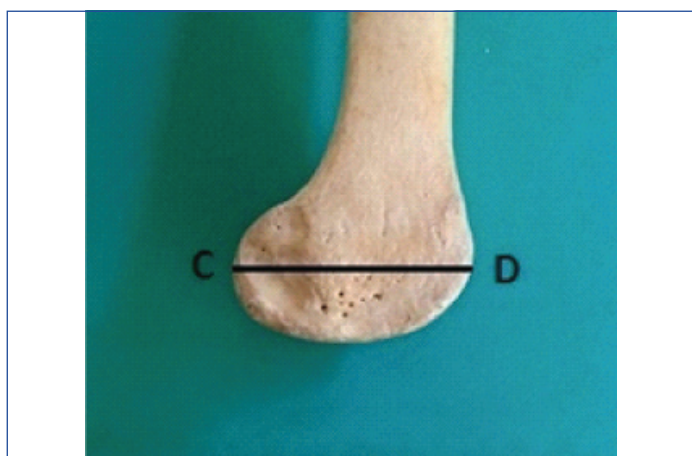
This was a prospective observational study conducted in the Department of Anatomy, GMERS Medical College, Gandhinagar, Gujarat, India, during April 2018 to July 2018. Prior approval from central research committee of our institute was taken (GMERS/MCG/CRC/14/2018). Seventy four dry adult femur of unknown age and sex; available in the department, were studied. Only complete and fully ossified bones were included and bones showing damage, deformity or arthritic changes were excluded from the study.

Following parameters were measured with the help of digital vernier caliper.

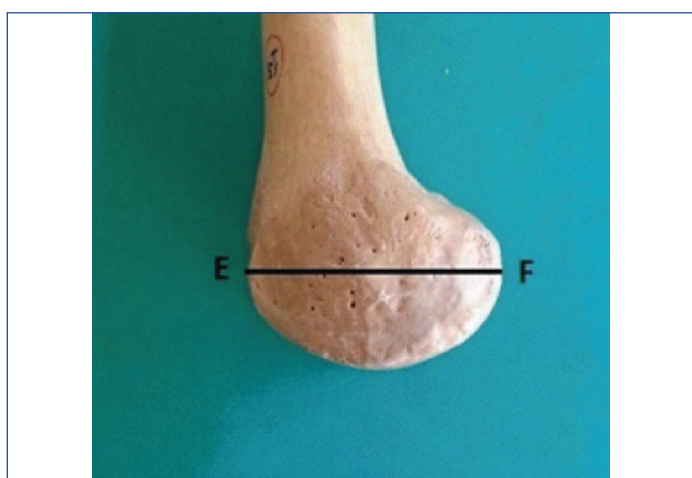
- (1) Bicondylar width-Maximum distance between both femoral epicondyles (BCW): Maximum distance between medial and lateral epicondyles in transverse plane [Table/Fig-1].
- (2) Maximum anteroposterior distance of lateral femoral condyle (LC AP): Maximum distance between anterior and posterior surface of lateral condyle [Table/Fig-2].
- (3) Maximum anteroposterior distance of medial femoral condyle (MC AP): Maximum distance between anterior and posterior surface of medial condyle [Table/Fig-3].
- (4) Maximum transverse distance of medial femoral condyle (MC T): Maximum distance between medial and lateral surface of medial condyle [Table/Fig-4].
- (5) Maximum transverse distance of lateral femoral condyle (LC T): Maximum distance between medial and lateral surface of lateral condyle [Table/Fig-4].



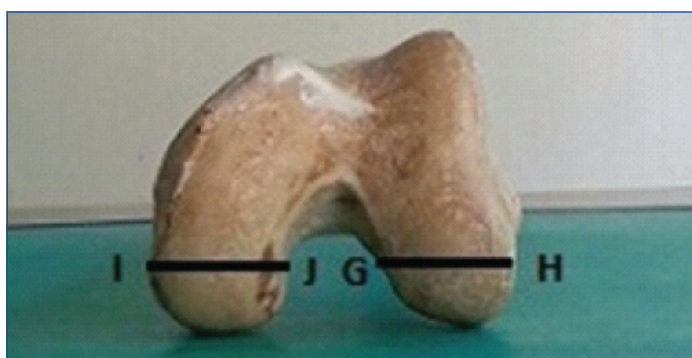
[Table/Fig-1]: AB= Bicondylar width (Maximum distance between both femoral epicondyles).



[Table/Fig-2]: CD = Maximum anteroposterior distance of lateral femoral condyle.

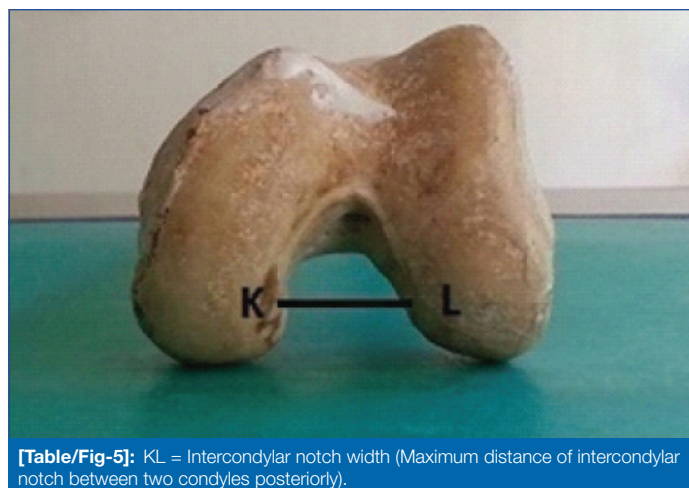


[Table/Fig-3]: EF= Maximum anteroposterior distance of medial femoral condyle.



[Table/Fig-4]: GH = Maximum transverse distance of lateral femoral condyle and IJ = Maximum transverse distance of medial femoral condyle.

(6) Intercondylar Notch Width (ICN W)-Maximum distance between medial and lateral surface of intercondylar notch posteriorly [Table/Fig-5].



[Table/Fig-5]: KL = Intercondylar notch width (Maximum distance of intercondylar notch between two condyles posteriorly).

STATISTICAL ANALYSIS

Qualitative data were expressed as percentage and proportions. Quantitative data were expressed as mean and standard deviation. The differences between two groups with respect to continuous variables were analysed using unpaired t-test. All the statistical tests were performed in Epi Info 3.5.1 software (CDC, USA 6). The p-value <0.05 was considered as statistically significant while p-value <0.01 was considered as highly statistically significant.

RESULTS

Out of 74 bones, 37 were of right side and 37 of left side. Mean bicondylar width was 69.6 ± 5.04 mm on right side and 69.8 ± 4.96 mm on left side ($p > 0.05$). Mean anteroposterior distance for medial condyle was 52.9 ± 4.99 mm on the right side and 53.5 ± 4.15 mm on the left side ($p > 0.05$). Mean anteroposterior distance for lateral condyle was 54.7 ± 4.01 mm on the right side and 55.0 ± 4.31 mm on the left side ($p > 0.05$). Mean transverse distance for medial condyle was 26.7 ± 2.03 mm on the right side and 26.9 ± 2.23 mm on the left side ($p > 0.05$). Mean transverse distance for lateral condyle was 30.3 ± 3.05 mm on the right side and 29.6 ± 2.03 mm on the left side ($p > 0.05$). Mean intercondylar notch width was 20.4 ± 3.17 mm on the right side and 18.7 ± 2.52 mm on the left side and the difference was statistically significant [Table/Fig-6,7].

The mean and SD values of all the bones included in the study are tabulated in [Table/Fig-8].

DISCUSSION

For the stability of the knee joint, morphology of femoral condyles and intercondylar notch play an important role. Replacement arthroplasty has become popular in treatment of permanent degenerative diseases of knee joint. To achieve long term success in knee arthroplasty, it is very important to use geometrically matched prosthesis [2]. Hence, for designing and selection of proper implant size, it is very important to have knowledge about accurate morphometric data. For this, direct methods of measurements are more beneficial than indirect methods [18]. In the present study, morphometric data were measured by direct observation using digital vernier caliper.

In [Table/Fig-9], we have compared our findings of the present study with other studies on dry femur published in literature [2,5,19-23].

In the present study, we found average bicondylar width to be 69.70 ± 4.96 mm. (69.6 ± 5.04 mm on right side and 69.8 ± 4.96 mm on left side). Similar results were obtained by Biswas A et al., in their study on Bengali population [23]. Slightly higher values than our study was found by Mistri S et al., [2], Ravichandran D et al., [20] Ameet KJ et al., [21], and Shweta J et al., [22] in their studies in different regions of India. Foreign authors like Terzidis I et al., and Taner Z et al., also found higher values than our study [5,19]. deoliveira Angelo RDC et al., in his radiographic study in Brazilians

Parameter (mm)	Right (37)				Left (37)			
	Minimum	Maximum	Mean	Std. deviation	Minimum	Maximum	Mean	Std. deviation
BCW	55.36	80.49	69.60	5.04	61.53	82.98	69.80	4.96
MC AP	44.59	63.29	52.90	4.99	47.68	65.19	53.50	4.15
LC AP	45.99	60.93	54.7	4.01	48.66	66.61	55.0	4.31
MC T	21.85	30.43	26.7	2.03	21.23	32.24	26.9	2.23
LC T	24.4	39.9	30.3	3.05	26.65	34.06	29.6	2.03
ICN W	14.88	27.69	20.4	3.17	15.17	27.36	18.7	2.52

[Table/Fig-6]: Showing minimum, maximum, mean and standard deviation for different parameters on right and left side (values are expressed in mm).

BCW: Bicondylar Width; MC AP: Maximum anteroposterior distance of medial femoral condyle; LC AP: Maximum anteroposterior distance of lateral femoral condyle; MC T: Maximum transverse distance of medial femoral condyle; LC T: Maximum transverse distance of lateral femoral condyle; ICN W: Intercondylar notch width: Maximum distance of intercondylar notch between two condyles posteriorly

Parameter	Side of femur bone (mean±SD) (mm)		p-value*
	Right (N=37)	Left (N=37)	
BCW	69.6±5.04	69.8±4.96	0.865
MC AP	52.9±4.99	53.5±4.15	0.596
LC AP	54.7±4.01	55.0±4.31	0.755
MC T	26.7±2.03	26.9±2.23	0.673
LC T	30.3±3.05	29.6±2.03	0.291
ICN W	20.4±3.17	18.7±2.52	0.013

[Table/Fig-7]: Showing mean, standard deviation (values are expressed in mm) and p-value of various parameters of right and left sides.

*-Unpaired t-test; BCW: Bicondylar width; MC AP: Maximum anteroposterior distance of medial femoral condyle; LC AP: Maximum anteroposterior distance of lateral femoral condyle; MC T: Maximum transverse distance of medial femoral condyle; LC T: Maximum transverse distance of lateral femoral condyle; ICN W: Intercondylar notch width: Maximum distance of intercondylar notch between two condyles posteriorly

Parameter (N=74)	Minimum	Maximum	Mean	Std. Deviation
BCW	55.36	82.98	69.70	4.96
MC AP	44.59	65.19	53.17	4.56
LC AP	45.99	66.61	54.87	4.13
MC T	21.23	32.24	26.79	2.16
LC T	24.40	39.90	29.93	2.58
ICN W	14.88	27.69	19.57	2.96

[Table/Fig-8]: Showing Minimum, Maximum, Mean and Standard deviation for different parameters of all bones (values are expressed in mm).

BCW: Bicondylar width; MC AP: Maximum anteroposterior distance of medial femoral condyle; LC AP: Maximum anteroposterior distance of lateral femoral condyle; MC T: Maximum transverse distance of medial femoral condyle; LC T: Maximum transverse distance of lateral femoral condyle; ICN W: Intercondylar notch width: Maximum distance of intercondylar notch between two condyles posteriorly

Year of study and population studied	BCW		MC AP		LC AP		MCT		LCT		ICW	
	R	L	R	L	R	L	R	L	R	L	R	L
Mistri S et al., [2], 2015, West Bengal 127 bones (65 R, 62 L)	74.43±6.10	73.98±5.99	-	-	-	-	-	-	-	-	19.12±2.5	18.65±2.8
Terzidis I et al., [5], 2012, Greek 360 bones (180R, 180L)	84.1±0.62	83.7±0.63	58.6±4.1	58.7±4.1	58.4±4.0	58.5±4.0	-	-	-	-	20.5±2.3	20.5±2.2
Taner Z et al., [19], 2002, Anatolian 72 bones (36 R, 36L)	76.8±5.9	77.3±5.2	-	-	-	-	-	-	-	-	-	-
Ravichandran D et al., [20] 2010, South India (200 bones, 106R, 94L)	74.58±0.57	73.97±0.61	-	-	-	-	-	-	-	-	18.89±0.29	18.65±0.27
Ameet KJ et al., [21], 2014, 97 bones (45R, 52 L)	72.5±5.3	73.3±5.3	-	-	-	-	-	-	-	-	18.0±3.0	17.9±2.5
Shweta J et al., [22], 2017, North India 100 bones (51R, 49 L)	73.1±6.14	72.16±6.58	-	-	-	-	-	-	-	-	20.82±2.57	21.03±3.13
Biswas A et al., [23], 2017, West Bengal 70 bones (35R, 35L)	71.71±4.50	70.71±5.25	52.97±3.77	54.74±3.85	56.20±3.36	56.05±4.29	25.48±2.05	27.28±2.29	27.80±2.91	28.03±2.56	20.86±2.52	19.45±2.57
Present study, Gujarat	69.6±5.04	69.8±4.96	52.9±4.99	53.5±4.15	54.7±4.01	55.0±4.31	26.7±2.03	26.9±2.23	30.3±3.05	29.6±2.03	20.4±3.17	18.7±2.52

[Table/Fig-9]: Showing comparison of various parameters of femoral condyles with other studies on dry femur (Values are expressed in mm) [2,5,19-23].

BCW: Bicondylar width; MC AP: Maximum anteroposterior distance of medial femoral condyle; LC AP: Maximum anteroposterior distance of lateral femoral condyle; MCT: Maximum transverse distance of medial femoral condyle; LCT: Maximum transverse distance of lateral femoral condyle; ICW: Intercondylar notch width

distance to be 63.35 ± 3.1 mm in Iranian males and 56.53 ± 2.98 mm in females [29].

No statistically significant difference was observed between two sides for anteroposterior distance of medial and lateral condyle ($p > 0.05$) in the present study. This finding was in accordance with Terzidis I et al., and Biswas A et al., in their studies on dried femora [5,23]. Average maximum transverse distance of medial condyle and lateral condyle in the present study was similar to the study done by Biswas A et al., [23]. Neelima P et al., observed slightly lower values for both condyles (total: 21.33 ± 0.43 mm on right side and 21.08 ± 0.44 mm on left side) than the present study [27]. In a study conducted by Moghtadaei M et al., on Iranian males and females by CT scan, results were found to be 24.6 ± 1.9 mm and 21.33 ± 0.2 mm respectively for maximum transverse distance of medial condyle while that of lateral condyle was found to be 24.42 ± 2.0 mm and 21.37 ± 1.6 mm in males and females respectively [29]. No statistically significant difference was observed on right and left side for maximum transverse distance of medial and lateral condyle ($p > 0.05$) in the present study. Biswas A et al., observed statistically significant difference for transverse distance of medial condyle ($p < 0.05$) but not for lateral condyle ($p > 0.05$) of both sides [23].

In the present study, average intercondylar notch width was found to be 20.4 ± 3.17 mm on the right side and 18.7 ± 2.52 mm on the left side (Total: 19.57 ± 2.96 mm). Our finding was in accordance with most of the other authors [2,5,20-23,27]. In a radiographic study conducted by de Oliveira Angelo RDC et al., in Brazilian males and females, values were 22.67 ± 4.45 mm and 21.56 ± 3.21 mm respectively [30]. In contrast to other studies conducted by direct method [2,5,20,21,23] and by indirect methods [7,26]; statistically significant difference ($p < 0.05$) was observed between right and left sides for intercondylar notch width in our study as well as that of Biswas A et al., [23]. Herzog RJ et al., in their study, compared intercondylar width measurements obtained with imaging techniques and direct method [31]. They reported that there was no statistical significant difference between vernier caliper and MRI but there was a significant difference between vernier caliper and X-ray. Measurements of intercondylar notch are clinically important because it is reported by several authors that smaller intercondylar notches are associated with smaller anterior cruciate ligament and more frequent rupture of anterior cruciate ligament [7,26,32].

Differences in the measurements among different populations may be attributed to genetic factors, environmental factors, mode of work, lifestyle, and effects of civilization etc., which may affect the built, stature and composition of human body. In the present study, except for the intercondylar notch width ($p < 0.05$), we did not find any side to side differences for other parameters ($p > 0.05$). Our findings were very much similar to that of Biswas A et al., in their study on Bengali population [23]. It is suggested by Terzidis I et al., that for total knee reconstruction, if there is no statistically significant difference, contralateral healthy side can be used safely for preoperative templating [5].

LIMITATION

The present study was conducted on only 74 bones which is small sample for the study to represent the entire Gujarati population. Because of the resource limitations in the department, we could not incorporate more bones in the study. Also, in the present study, we could not conduct evaluation on the basis of gender because the bones available in the department were of unknown sex. Further larger studies involving more bones of known sex from different geographical regions are advised to increase the knowledge on the subject. Gender based evaluation might add to the design of prosthesis.

CONCLUSION

Present study provides morphometric data for femoral condyles by direct method of measurement. As the measurements may vary

between populations; our study will help in adding the information by providing morphometric data of femoral condyles for manufacturing implants suitable for Indian population, particularly for Gujarat region. Selection of appropriate implant according to different ethnic specifications will minimize mismatch and will improve clinical outcome.

REFERENCES

- [1] Standring S. Gray's Anatomy. The Anatomical basis of clinical practice. 40th edition. Elsevier Churchill Livingstone. 2008: 1362,1397.
- [2] Mistri S. A study of femoral condylar morphometry. Indian Journal of Basic and Applied Medical Research. 2015;4(4):500-10.
- [3] Goldberg VM, Figgie HE III, Figgie MP. Technical consideration in total knee surgery: Management of patellar problems. Orthop Clin North Am. 1989;20(2):189-99.
- [4] Ranawat CS. The patellofemoral joint in total condylar knee arthroplasty. Pros and cons based on five-to-ten-year follow-up observations. Clin Orthop Relat Res. 1986;(205):93-99.
- [5] Terzidis I, Totlis T, Papathanasiou E, Sideridis A, Vlasik K, Natsis K. Gender and side-to-side differences of femoral condyles morphology: osteometric data from 360 caucasian dried femora. Anatomy Research International. 2012;2012:679658.
- [6] Cheng FB, Ji XF, Lai Y, Feng JC, Zheng WX, Sun YF, et al. Three dimensional morphometry of the knee to design the total knee arthroplasty for Chinese population. Knee. 2009;16(5):341-47.
- [7] Shelbourne KD, Facibene WA, Hunt JJ. Radiographic and intraoperative intercondylar notch width measurements in men and women with unilateral and bilateral anterior cruciate ligament tears. Knee Surg Sports Traumatol Arthrosc. 1997;5(4):229-33.
- [8] Lombardo S, Sethi PM, Starkey C. Intercondylar notch stenosis is not a risk factor for anterior cruciate ligament tears in professional male basketball players: an 11-year prospective study. American Journal of Sports Medicine. 2005;33(1):29-34.
- [9] Murshed KA, Çiçekcibasi AE, Karabacakoglu A, Seker M, Ziyilan T. Distal femur morphometry: A gender and bilateral comparative study using magnetic resonance imaging. Surg Radiol Anat. 2005;27(2):108-12.
- [10] White TD and Folkens PA. Human Osteology, Academic Press, San Diego, Calif, USA, 2nd edition. 2000.
- [11] Anderson AF, Anderson CN, Gorman TM, Cross MB, Spindler KP. Radiographic measurements of the intercondylar notch: are they accurate? Arthroscopy. 2007;23(3):261-68.
- [12] Horsman A, Leung WK, Bentley HB, McLachlan MSF. Effect of rotation on radiographic dimensions of the humerus and femur. BJR. 1977;50(589):23-28.
- [13] Mistri S, Majumdar S, Biswas S. Morphometric study of some lower femoral anatomy in Eastern Indian population. Indian Journal of Basic and Applied Medical Research. 2014;3(4):182-90.
- [14] Hussain F, Abdul Kadir MR, Zulkifly AH, Sa'at A, Aziz AA, Hossain G, et al. Anthropometric measurements of the human distal femur: A study of the adult Malay population. Biomed Res Int. 2013;2013:175056.
- [15] Jain JP. Knee prosthesis sizes in Indian patients undergoing total knee replacement. Int Surg J. 2015;2(3):348-51.
- [16] Cheng CK, Lung CY, Lee YM, Huang CH. A new approach of designing the tibial baseplate of total knee prostheses. Clin Biomech. 1999;14(2):112-17.
- [17] Shah DS, Ghayur R, Ravi B, Hegde C, Shetty V. Morphological measurement of knee joints in Indian population: Comparison to current knee prostheses. OJRA. 2014;4(2):75-85.
- [18] Zalawadia AZ, Parekh DH, Patel SM. Morphometric study of lower end of dry femur in Gujarat region and its clinical implication. Int J Anat Res. 2017;5(4.2):4595-99.
- [19] Taner Z and Murshid KA. An analysis of Anatolian human femur anthropometry. Turk J Med Sci. 2002;32:231-35.
- [20] Ravichandran D, Melanie R. Morphology of the intercondylar notch and its clinical significance. IJAS. 2010;1:26-30.
- [21] Ameet KJ, Murlimanju BV. A Morphometric analysis of Intercondylar notch of femur with emphasis on its clinical implications. Med and Health. 2014;9(2):103-18.
- [22] Shweta J, Renu C. Morphometric analysis of condyles and intercondylar notch of femur in north indian population and its clinical significance. J Evolution Med Dent Sci. 2017;6(32):2605-08.
- [23] Biswas A, Bhattacharya S. A morphometric and radiological study of the distal end of femur in West Bengal population. IJAE. 2017;122(1):39-48.
- [24] de oliveira Angelo RDC, de Moraes SRA, Suruagy LC, Tetsuo T, Costa HM. Morphometric study of the femoral intercondylar notch of knees with and without injuries of Anterior Cruciate Ligament (ACL), by the use of software in digitalized radiographic images. Acta Ortop Bras. 2004;12(3):220-37.
- [25] Suryanarayan P, Jain N, Ashok P. CT evaluation and study: Anthropometric measurement of knee joint in Asian population. Int J Sci Res Publ. 2014;4(12):1-12.
- [26] Charlton WP, St John TA, Ciccotti MG, Harrison N, Schweitzer M. Differences in femoral notch anatomy between men and women. A magnetic resonance imaging study. Am J Sports Med. 2002;30(3):329-33.
- [27] Neelima P, Ravisunder R, Himabindu A. A study on morphometric measurements of adult dried Femora in Visakhapatnam. Int J Adv Res. 2016;4(8):564-67.
- [28] Magetsari R, Suyitno, Dharmastiti R, Salim UA, Hidayat L, Yudiman T, et al. Three dimensional morphometry of distal femur to design knee prosthesis for Indonesian population. Int J Morphol. 2015;33(4):1255-60.

- [29] Moghtadaei M, Moghimi J, Shahhoseini G. Distal femur morphology of Iranian population and correlation with current prostheses. *Iran Red Crescent Med J.* 2016;18(2):e21818.
- [30] de Oliveira Angelo RDC, Costa HM, Galindo LCM, Tashiro T. An anthropometric radiographic study of the intercondylar notch in Brazilian males and females. *J Morphol Sci.* 2007;21(1):47-52.
- [31] Herzog RJ, Silliman JF, Hutton K, Rodkey WG, Steadman JR. Measurements of the intercondylar notch by Plain film radiography and magnetic resonance imaging. *Am J Sports Med.* 1994;22(2):204-10.
- [32] Wada M, Tatsuo H, Baba H, Asamoto K, Nojyo Y. Femoral intercondylar notch measurements in Osteoarthritic knees. *Rheumatology.* 1999;38(6):554-58.

PARTICULARS OF CONTRIBUTORS:

1. Assistant Professor, Department of Anatomy, GMERS Medical College, Civil Hospital Campus, Gandhinagar, Gujarat, India.
2. Tutor, Department of Anatomy, GMERS Medical College, Civil Hospital Campus, Gandhinagar, Gujarat, India.
3. Associate Professor, Department of Anatomy, GMERS Medical College, Civil Hospital Campus, Gandhinagar, Gujarat, India.

NAME, ADDRESS, E-MAIL ID OF THE CORRESPONDING AUTHOR:

Dr. Nishita K Jethva,
GMERS Medical College, Civil Hospital Campus, Sector-12, Gandhinagar-382012, Gujarat, India.
E-mail: nishi.jethva@gmail.com

Date of Submission: **Dec 23, 2018**Date of Peer Review: **Jan 01, 2019**Date of Acceptance: **Jan 29, 2019**Date of Publishing: **July 01, 2019****FINANCIAL OR OTHER COMPETING INTERESTS:** None.