

Sex Determination using Anthropometric Dimensions of Clavicle-An Observational Study

NIVEDITHA SAMALA¹, BETHI MANASA²

ABSTRACT

Introduction: Determination of sex constitutes the most important element during the identification process of human skeletal remains. Several sex-specific features of human skeleton have been tried for sex determination with varying reliability. It becomes even more challenging when only a single bone like the clavicle is available.

Aim: To study the parameters of the clavicle for bilateral asymmetry, to study the sexual dimorphism in human adult clavicles and to compare this data with the data from previous studies.

Materials and Methods: The materials for the present observational study consisted of 60 adult clavicles of known sex (34 male and 26 female) which were collected from the dissected cadavers from Department of Anatomy during the period August 2010-December 2012 in Telangana. The length & mid shaft circumference of each clavicle was studied. The data collected were analysed and subjected to statistical analysis using SPSS software version 20.0. The descriptive statistics were calculated to define the sample.

Results: The mean of the maximum length of clavicle were more in males compared to the females. In the present study for right clavicles, if length is more than 152.69 mm it should be male clavicle and if length is less than 105.68 mm it should be female clavicle. Similarly for left clavicles if length is more than 156.49 mm it should be male clavicle and if length is less than 117.21 mm it should be female clavicle. Mid-shaft circumference of male clavicles were more compared to females. Mean mid-shaft circumference of male right clavicles were at least 4.94 mm more than mean mid-shaft circumference of female right clavicles and mean mid-shaft circumference of male left clavicles were at least 5.63 mm more than mean mid-shaft circumference of female left clavicles.

Conclusion: By this present study the author highlighted the importance of clavicle from skeletal remains of the deceased whose identification is not known thus it helps the forensic experts in medico-legal issues and also anthropologists in their study of evolution of mankind and migration of races and also helps the orthopaedicians in intra-medullary nailing techniques in case of fracture of clavicle.

Keywords: Collar bone, Length, Mid shaft circumference, Variations

INTRODUCTION

Gender identification of an individual is one of the primary factors in medico-legal examination [1]. For this different parts of the body are utilised such as the pelvis, long bones with an epiphysis and a metaphysis in skeletons, skull, pubis, paranasal sinuses, foramen magnum, maxillary sinuses and teeth [1-5]. The clavicle is the first bone in the body to ossify and is the last bone to complete ossification and is the only long bone that lies horizontally in the body [6]. It is a long bone that is relatively resistant to environmental degradation and have been proposed as a reliable bone to determine sex [7]. The male and female clavicles exhibit a few variations [6]. The female clavicle was found to be shorter, less curved, thinner and smoother than the male. Male bones are heavier and the muscular markings are more prominent than in females.

The morphological variations of clavicle like size and dimensions are very important for both clinical in case of fracture-fixation of internal or external medullary devices as well as forensic anthropological perspectives [8].

Clavicle is most frequently fractured bone of human skeleton, possessing high degree of variability in its anatomical, bio mechanical and morphological features. Extended period of skeletal growth up to 3rd decade in clavicle imparts additional advantage for forensic identification purpose [8].

Taylor in his book "Medical Jurisprudence" has quoted the accuracy of sexing various bones using the statistical analysis as follows [9]:

Skull + Femur - 97.35%

Sacrum + Coccyx - 97.18%

Coccyx - 97.25%

Mandible - 86.29%

Sternum - 80%

Atlas + Axis - 31.18%

Clavicle - 28.08%


This study was carried out to assess the accuracy of this bone for sex determination.

MATERIALS AND METHODS

An observational study was carried out in Department of Anatomy of a tertiary care hospital during the period August 2010 to December 2012. The study consisted of 60 adult clavicles of known sex (34 male and 26 female) which were collected from the dissected cadavers. The clavicles were cleaned and dried and the study was approved by the Institutional Ethical Board. The length and mid shaft circumference of each clavicle was studied.

For measuring the length, the clavicle was kept on a table, in such a position that anterior and posterior borders were in the same horizontal plane, the midpoints of sternal and acromial ends were marked and the maximum distance between the two ends of the clavicle was measured with the help of a digital Vernier Caliper (in mm) as shown in [Table/Fig-1]. Measurement of the Mid-shaft circumference of clavicle is shown in [Table/Fig-2,3]. While taking the length, a mark was done with a pencil at the middle of the

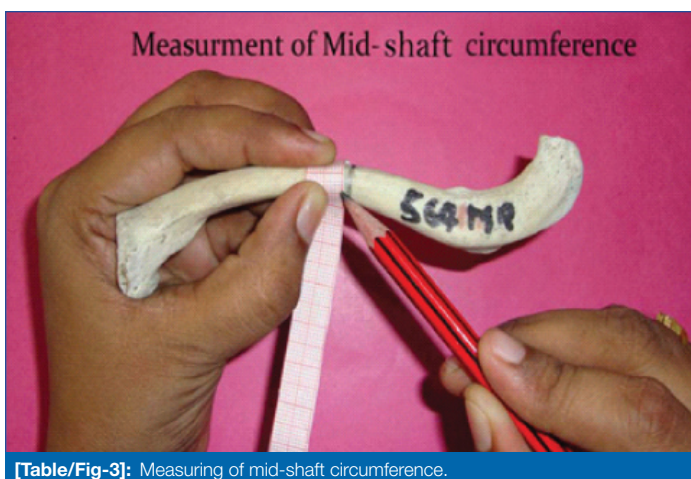clavicle. At the midpoint, a circumference was measured with the help of a graph paper.



[Table/Fig-1]: Photograph showing measurement of length by Vernier Caliper (in mm).



[Table/Fig-2]: Marking of mid-shaft circumference.



[Table/Fig-3]: Measuring of mid-shaft circumference.

In the normal distribution, the maximum and the minimum limits can be safely calculated by the formula $\text{mean} \pm 3 \text{ Standard Deviation}$ whereas the $\text{mean} + 3\text{SD}$ gives the maximum value and $\text{mean} - 3\text{SD}$ gives the minimum value. In this way, we can statistically fix a measurement below which only female clavicle can be found and similarly another measurement above which only male clavicle can be seen in a particular zone. These limiting measurements were known as the Demarcating points. The data collected were analysed and subjected to statistical analysis using SPSS software version 20.0.

RESULTS

In the present research study a total of 60 adult clavicles of both sex were studied. The length of clavicles were measured and statistically analysed and represented in [Table/Fig-4]. The mid-shaft circumference of clavicles were measured and statistically analysed and represented in [Table/Fig-5].

S. No.	Details of Measurements	Right		Left	
		M	F	M	F
1.	No. of bones	17	13	17	13
2.	Range in mm	121-170	119-142	124-160	120.5-150.5
3.	Mean	142.76	128.69	145.17	131.56
4.	Standard Deviation	12.36	8.00	9.32	8.31
5.	Mean \pm 3SD	105.68-179.84	104.69-152.69	117.21-173.13	106.63-156.49
6.	Demarcating Point	>152.69	<105.68	>156.49	<117.21
7.	p-value	0.0001	0.0001	0.001	0.001

[Table/Fig-4]: Statistical Analysis of the length of the clavicle in mm (millimeters).

S. No.	Details of Measurements	Right		Left	
		M	F	M	F
1.	No. of bones	17	13	17	13
2.	Range in mm	22.0-55.0	27.0-35.0	14.8-26.4	6.6-17.3
3.	Mean	35.29	30.34	35.94	30.30
4.	Standard Deviation	7.27	2.42	2.88	3.25
5.	Mean \pm 3SD	28.02-57.10	23.08-37.60	27.30-44.58	20.55-40.05
6.	Demarcating Point	>37.60	<28.02	>40.05	<27.30
7.	p-value	0.01	0.01	0.01	0.01

[Table/Fig-5]: Statistical Analysis of the mid circumference of the clavicle in mm (millimeters).

DISCUSSION

In the present study an effort has been made to determine the sex of an adult clavicle by its length and midshaft circumference. Many authors worked on the sex determination of clavicles based on their length and their results were tabulated in [Table/Fig-6] [10-15].

Author	Number of Clavicles	Male		Female	
		Right	Left	Right	Left
Terry RJ et al., [10]	100 (50 M, 50 F)	153.30 \pm 0.83	155.85 \pm 0.92	140.98 \pm 0.76	141.78 \pm 0.03
Oliver [11]	180 (110 M, 70 F)	154.20	155.00	137.90	138.70
Jit I et al., [12]	348 (236 M, 112 F)	145.58 \pm 8.60	147.5 \pm 9.25	130.36 \pm 9.11	129.80 \pm 1.77
Singh S et al., [13]	200 (162 M, 38 F)	141.49 \pm 8.22	144.18 \pm 8.01	125.78 \pm 7.50	125.77 \pm 8.09
Mohammad SA et al., [14]	100 (63 M, 37 F)	155.20	156.67	137.42	139.21
Present study (2012)	60 (34 M, 26 F)	142.76 \pm 12.36	145.18 \pm 9.32	128.69 \pm 8.00	131.56 \pm 8.32
Ishwarkumar S et al., [15]	100 (66 M, 34 F)	153.52 \pm 8.79	151.82 \pm 10.96	138.02 \pm 7.36	141.04 \pm 5.72

[Table/Fig-6]: Comparison of mean values of the length of clavicles in different studies in mm (millimeters).

The present study (2012) is correlating with the Singh S et al., and Jit I et al., authors and present study (2012) is not correlating with other authors. The difference in measurements can be due to racial, genetic and environmental factors in this study for right clavicles, if length is more than 152.69 mm it should be male clavicle and if length is less than 105.68 mm it should be female clavicle. Similarly for left

clavicles if length is more than 156.49 mm it should be male clavicle and if length is less than 117.21 mm it should be female clavicle. The p-value also suggests the study is statistically significant. Many authors worked on the sex determination of clavicles based on their midshaft circumference and their results were tabulated in [Table/ Fig-7] [12,16,17].

Author	Number of Clavicles	Male		Female	
		Right	Left	Right	Left
Jit I et al., [12]	348 (236 M, 112 F)	37.10±2.99	36.44±3.46	30.15±2.46	30.16±2.72
Jit I et al., [16]	340 (280 M, 60 F)	36.20±3.50	35.90±2.70	30.40±2.70	30.00±2.80
Kaur K et al., [17]	200 (100 M, 100 F)	36.97±3.62	36.91±3.57	30.83±2.89	30.69±2.98
Present study (2012)	60 (34 M, 26 F)	35.29±7.28	35.94±2.88	30.35±2.43	30.31±3.25

[Table/Fig-7]: Comparison of mean values of the midshaft circumference of clavicles in different studies in mm (millimeters).

REFERENCES

- [1] Khangura RK, Sircar K, Singh S, Rastogi V. Sex determination using mesiodistal dimension of permanent maxillary incisors and canines. *J Forensic Dent Sci.* 2011;3:81-85.
- [2] Uthman AT, Al-Rawi NH, Al-Timimi JF. Evaluation of foramen magnum in gender determination using helical CT scanning. *Dentomaxillofac Radiol.* 2012;41:197-202.
- [3] Teke HY, Duran S, Canturk N, Canturk G. Determination of gender by measuring the size of the maxillary sinuses in computerized tomography scans. *Surg Radiol Anat.* 2007;29:09-13.
- [4] Leopold D, Novotny V. Sex determination from the skull and parts of the hip bone. *Gegenbaurs Morphol Jahrb.* 1985;131:277-85.
- [5] Luo YC. Sex determination from the pubis by discriminant function analysis. *Forensic Sci Int.* 1995;74:89-98.
- [6] Standring, S. *Gray's Anatomy: The Anatomical Basis of Clinical Practice.* 40th edition. Edinburgh, Churchill Livingstone/Elsevier; 2008:817-19.
- [7] Akhlaghi M, Moradi B, Hajibeygi M. Sex determination using anthropometric dimensions of the clavicle in Iranian population. *J Forensic Leg Med.* 2012;19(7):381-85.
- [8] Sehrawat JS, Pathak RK. Variability in anatomical features of human clavicle: Its forensic anthropological and clinical significance. *Translational Research in Anatomy.* 2016;3-4:05-14.
- [9] Taylor AS. *The principles and practice of medical jurisprudence.* 1866; 8th edition, vol 1.
- [10] Terry RJ. The Clavicle of the American Negro. *Amer Jour Phys Anthropol.* 1932;16:351-80.
- [11] Oliver. *Anthropologie de la clavicle III, La Clavicle du Francis.* *Bullins at Memories de la Societe D' Anthropology, Paris 2.* 1951; 10 Edition Serie: 121-157.
- [12] Jit I, Singh S. The sexing of the adult Clavicles *Ind Jour Med Res.* 1966;54:551-71.
- [13] Singh S, Gangrade KC. The Sexing of adult clavicles demarking points for Varanasi Zone. *J Ana Soc India.* 1968;17:89-100.
- [14] Mohammad SA. Length of the collar bone in Iraqi people. *Tikrit Medical Journal.* 2006;12(1):11-14.
- [15] Ishwarkumar S, Pillay P, Haffajee MR, Rennie C. Sex determination using morphometric and morphological dimensions of the clavicle within the KwaZulu-Natal population. *Int J Morphol.* 2016;34(1):244-51.
- [16] Jit I, Sahni D. Sexing the North Indian Clavicles. *J Ana Soc India.* 1983;32:61-72.
- [17] Kaur K, Sidhu SS, Kaushal S, Kaur B. Sexing Northwest Indian Adult Clavicles of Patiala zone. *J Anat Society of India.* 1997;46(2):121-30.

PARTICULARS OF CONTRIBUTORS:

1. Assistant Professor, Department of Anatomy, Shadan Institute of Medical Sciences, Hyderabad, Telangana, India.
2. Assistant Professor, Department of Anatomy, Malla Reddy Medical College for Women, Hyderabad, Telangana, India.

NAME, ADDRESS, E-MAIL ID OF THE CORRESPONDING AUTHOR:

Dr. Bethi Manasa,
11-10-156, Sri Kalkinagar Colony, Kothapet, Hyderabad-500035, Telangana, India.
E-mail: bethimanasa@yahoo.co.in

Date of Submission: **July 21, 2018**

Date of Peer Review: **Aug 09, 2018**

Date of Acceptance: **Dec 21, 2018**

Date of Publishing: **Jan 01, 2019**

FINANCIAL OR OTHER COMPETING INTERESTS: None.