

# Laparoscopic Management of Post Traumatic Diaphragmatic Hernia: Report of Two Cases and Review of Literature

MAHENDRA PRATAP SINGH, YOGESH NIWARIYA, ROMAN DUTTA, ROHIT SALUJA

## ABSTRACT

Traumatic diaphragmatic rupture is a serious complication following abdominal-thoracic trauma and is often missed in acute phase due to the presence of concurrent injuries. It can present later as diaphragmatic hernia which carries high morbidity and mortality. Traditionally, laparotomy or thoracotomy is performed to manage diaphragmatic hernias. However, laparoscopic approach is being increasingly used recently for both diagnosis and treatment

of traumatic diaphragmatic hernia. Here we describes laparoscopic management in two cases of post traumatic left sided diaphragmatic hernia.

We found laparoscopic approach safe, feasible and effective alternative for management of post-traumatic diaphragmatic hernia with short and uneventful post operative period in both of our cases. The patients were remaining asymptomatic during postoperative follow-up at two years.

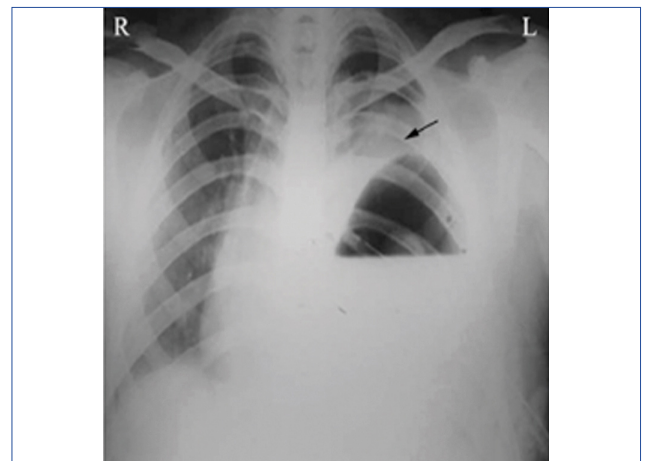
**Keywords:** Blunt trauma, Diaphragmatic tear, Internal hernia, Thoraco-abdominal injury

## CASE REPORT 1

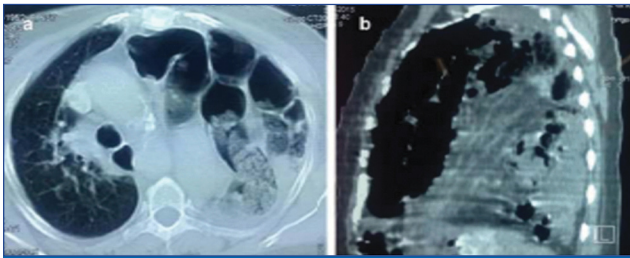
A 63-year-old otherwise healthy female was admitted with history of pain in the left side of the chest and one episode of haematemesis. Two and a half years ago the patient had met with a road traffic accident with seat-belt injury sustained in the left abdominal and thoracic region, which was managed conservatively at another hospital. She remained asymptomatic for six months but developed haematemesis which was treated conservatively in the same hospital without establishing the cause of the problem. On physical examination, her vitals were normal and stable. The left hemithorax revealed decreased air entry in the lower and middle lung zones. Bowel sounds were heard in the same hemithorax. Abdominal examination showed fullness in left upper quadrant. Plain chest radiograph revealed raised left dome of the diaphragm and a mediastinal shift towards the right side with radio-opacity involving lower and mid zone field consistent with bowel [Table/Fig-1]. A Contrast Enhanced Computed Tomography (CECT) scan of chest and abdomen demonstrated elevated left hemidiaphragm with high placed stomach and colon and herniated small bowel loops with its mesentery associated with mass effect with mediastinal shift towards the right side confirming diaphragmatic hernia [Table/Fig-2a,b].

Diagnostic laparoscopy revealed a 6 cm x 5 cm rent in the posterior aspect of left dome of diaphragm through which

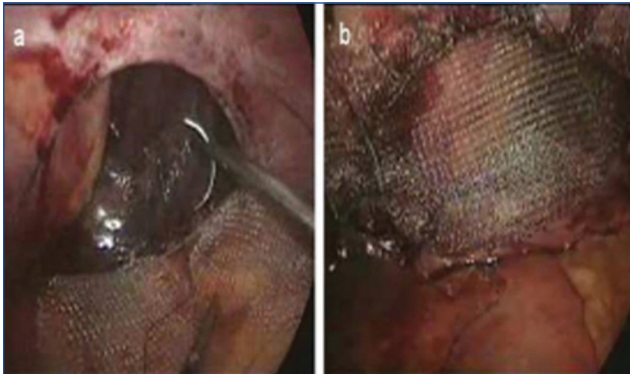
stomach, transverse colon and loops of small intestine were seen herniating into the thoracic cavity. There were dense adhesions between the contents and margins of the defect. The herniated contents were reduced back into the abdomen cavity after adhesiolysis. The diaphragmatic defect was repaired using composite mesh fixed with non absorbable 2-0 prolene interrupted stitches. The entire procedure was accomplished laparoscopically through two 5 mm and two 10 mm ports, keeping the internal pressure around 7-8 mm Hg after placing the patient in steep reverse



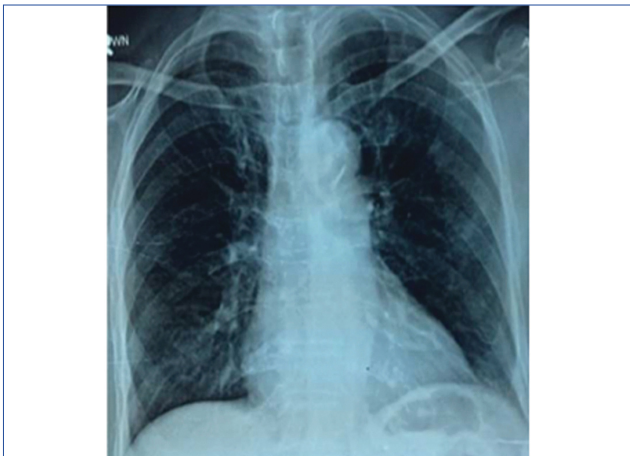**[Table/Fig-1]:** Preoperative chest X-ray of a patient showing raised left dome of diaphragm with mediastinal shift towards right side.



**[Table/Fig-2a,b]:** CECT-scan of chest showing herniation of abdominal contents consistent with bowel loops into left hemithorax associated with mass effect.



**[Table/Fig-3]:** a) Operative photograph showing left side large diaphragmatic tear. b) laparoscopic mesh repair of diaphragm tear.



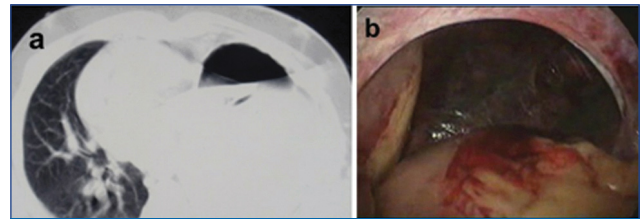
**[Table/Fig-4]:** Postoperative chest X-ray showing clear and normal lung fields.

Trendelenburg's position with surgeon standing between the split legs [Table/Fig-3a,b]. The patient made an uneventful recovery. Her postoperative chest X-ray showed clear and normal lung fields [Table/Fig-4]. The patient was discharged on 3<sup>rd</sup> postoperative day. She remains asymptomatic at two years of follow-up.

## CASE REPORT 2

A 19-year-old male was admitted with history of pain left upper abdomen and post prandial respiratory discomfort for one month and non-bilious vomiting for 2 days. There was no history of chest pain, dyspnoea, haematemesis or

fever. He gave history of fall from height sustaining injury to the left lower anterior chest 6 months ago, which was managed with intercostal drainage and blood transfusion at another hospital. He remained asymptomatic for the next 5 months. On physical examination, vitals were stable. Chest examination revealed decreased air entry over the left lower lung zone with presence of bowel sounds. Per abdomen palpation revealed deep tenderness in the left hypochondrium. Chest X-ray showed raised left dome of the diaphragm. CECT-scan of chest and abdomen confirmed left side diaphragmatic hernia [Table/Fig-5a].



**[Table/Fig-5]:** a) Axial section of CT scan of chest showing presence of abdominal contents consistent with stomach. b) Peri-operative picture showing the diaphragmatic defect with omentum and stomach in left pleural cavity.

At diagnostic laparoscopy, 3 x 4 cm rent was visualised in the posterior left hemi diaphragm through which stomach and omentum were seen herniating into the thoracic cavity [Table/Fig-5b]. The herniated contents were reduced back into the abdomen after dividing all the adhesions in the chest cavity and at the diaphragmatic rent. The diaphragmatic rent was repaired with interrupted, mattress non absorbable 2-0 prolene sutures. The entire procedure was accomplished laparoscopically through two 5 mm and two 10 mm ports. The patient developed loculated left pleural effusion on the 3<sup>rd</sup> post operative day which was managed with USG guided pigtail drainage. There was complete resolution of pleural space collection by post operative day 7. The patient was symptom free at two year of follow-up.

## Consent

Written and informed consent to photograph radiological images, operative procedures, including appropriate portions of the body for medical, scientific or educational purposes without revealing the identity was obtained from the two patients.

## DISCUSSION

Traumatic diaphragmatic rupture is an under-reported but not uncommon injury that occurs secondary to both blunt and penetrating trauma to abdomen and thorax. Ambroise Pare described the first case of traumatic rupture of diaphragm diagnosed at autopsy in 1579 [1]. Bowditch reported antemortem diagnosis of traumatic diaphragmatic rupture in 1853 [2].

A high index of suspicion is required to diagnose this injury at an early stage. Unlike other acute traumatic problems, it may lead to serious late sequelae. Missed diaphragmatic tear can lead to development of diaphragmatic hernia, which carries high morbidity and mortality due to complications. The largest experience of traumatic diaphragmatic injury in the form of a collective review of 980 patients was reported by Shah R et al., in 1995 [3]. They reported a mortality of 19% in traumatic diaphragmatic injury. The pronounced prevalence of diaphragmatic rupture is among 0.8% and 1.6% of sufferers admitted to the health facility following blunt trauma [3,4].

Traumatic diaphragmatic rupture may result from both blunt and penetrating thoraco-abdominal injuries. The diagnosis of diaphragmatic rupture is often not obvious at the time of the admission due to the presence of concurrent injuries and is missed in 7% to 66% of patients with multiple injuries [4-7]. The actual incidence may be even higher. Out of all patients undergoing laparotomy or thoracotomy for trauma, 4% to 6% have associated diaphragmatic injuries [8,9].

Blunt trauma is usually caused by motor vehicle accidents, fall from heights or crush injury to lower chest or upper abdomen. Penetrating injuries result from stab or gunshot wounds of the lower chest and upper abdomen. Left sided injuries are more common in case of blunt trauma. Shah R et al., pronounced left sided injury in 68.5%, right sided injury in 24.2% and bilateral injury in 1.5% of sufferers of blunt trauma [3]. Monsour KA, reported only 20% of patients to have right sided rupture [10]. The reasons proposed for increased occurrence of left sided damage are: quality strength of right hemidiaphragm, protection by liver on right side, underdiagnoses of right side damage, and shortcoming of left hemidiaphragm at points of embryonic fusion [11,12]. During blunt abdominal trauma, a tenfold increase in pressure can occur in the abdomen transmitting a sudden blow of kinetic energy through the domes of diaphragm which may result in diaphragmatic rupture and herniation of the abdominal contents into thoracic cavity [13]. In case of penetrating injuries, the mechanism is self explanatory. Both of our cases had isolated left sided diaphragmatic hernia caused by blunt trauma which was missed at initial admission.

The presentation of patients with traumatic diaphragmatic rupture is non specific. Symptoms are often variable and usually overshadowed by concurrent injuries. Injuries missed in the acute phase usually lead to development of diaphragmatic hernia later. Left untreated, the hernia continues to grow because of upward migration of the abdominal contents due to positive intra-abdominal and negative intra thoracic pressure. It may become symptomatic at any stage due to respiratory symptoms or the contents may undergo torsion with disastrous consequences. Based on the time of presentation, traumatic diaphragmatic hernia has been classified by Cartar B et al., (acute versus chronic) and the same was later modified by

Adamthwaite [14,15].

The investigation tools used to diagnose diaphragmatic rupture include chest X-ray, barium study, CT-scan, laparoscopy and thoracoscopy. Chest X-ray is a cost effective and easily available investigation. A barium study may reveal herniating bowel loops in the thoracic cavity. The CT-scan is useful in further delineating the herniated contents. However, the best diagnostic test is either a laparoscopy or thoracoscopy depending on the presence of concurrent injuries and time of presentation. These not only identify the site and size of the tear, the nature of the herniating contents but also allow repair to be performed at the same time [15-17]. In our two cases, the diagnosis of traumatic diaphragmatic hernia was made because of history of trauma, clinical examination, chest X-ray and CT-scan findings. The exact location and size of the defect and the nature of herniated contents were however identified at laparoscopy.

Most surgeons agree that in the acute phase laparotomy should be performed because injury to other intra-abdominal organs can readily be addressed. In the latent phase, thoracotomy or laparotomy have been used to manage diaphragmatic injury [18-21]. Recently, Video-Assisted-Thoracoscopic-Surgery (VATS) and laparoscopy have been successfully used in the management of these patients [15-17,22-24]. VATS provide direct inspection of entire hemidiaphragm including recesses. Repair of the diaphragm can be done at the same time if abdominal injury has been ruled out or has already been managed. Laparoscopy has limitations in right side injury evaluation, especially when located posteriorly.

The possibility of spatial occupation existed in our cases, due to many viscera displaced from the abdomen over such a long period. We performed laparoscopic repair in both the cases successfully. The laparoscopic approach allows for proper assessment of such injuries in the both half of diaphragm simultaneously and whole abdomen is evaluated. Their successful correction is also possible at the same time with all the well known benefits of minimal access surgery. Although, experience with this approach is small and the reported follow-up is short at present, it appears to be a safe, feasible and effective alternative approach to laparotomy or thoracotomy both for diagnosing and repairing post traumatic chronic diaphragmatic hernias.

## CONCLUSION

Diaphragmatic injury can be missed if not specifically looked for at the time of initial trauma assessment. Non specific symptoms are responsible for delayed presentation with herniation of abdominal viscera and its attendant complications. By keeping possibility of diaphragmatic tear while managing blunt trauma patients along with close collaboration of emergency physician, radiologists and surgeon would cut occurrence

of missing diaphragmatic injury. We recommend use of laparoscopic approach for the management of post-traumatic diaphragmatic hernia in carefully selected patient by surgeon experienced enough in performing advance laparoscopic procedures.

## REFERENCES

- [1] Hanby WB. The case reports and autopsy records of Ambrose Pare. Springfield, IL: Thomas.1968. Pp. 50-51.
- [2] Bowditch HI. Diaphragmatic hernia. Buffalo Med J. 1853;9:65-94.
- [3] Shah R, Sabanathan S, Mearns AJ, Choudhury AK. Traumatic rupture of diaphragm. Ann Thorac Surg. 1995;60(5):1444-49.
- [4] Leaman PL. Rupture of right hemidiaphragm due to blunt trauma. Ann Emerg Med. 1983;12(6):351-57.
- [5] Lucido JL, Wall A. Rupture of diaphragm due to blunt trauma. Arch Surg. 1963;86:989-99.
- [6] Niville EC, Himpens JM, Bruos PL, Gruwez JA. The use of laparotomy in the treatment of recent diaphragmatic rupture due to blunt trauma. Injury. 1983;15(3):153-55.
- [7] Adamthwaite DN. Traumatic diaphragmatic hernia. Ann Surg. 1983;15:73-97.
- [8] Drews JA, Mercer EC, Benfield JR. Acute diaphragmatic injuries. Ann Thorac Surg. 1973;16: 67-88.
- [9] Freeman T, Fischer RP. The inadequacy of peritoneal lavage in diagnosis of acute diaphragmatic rupture. J Trauma. 1976;16:538-41.
- [10] Mansour KA. Trauma to the diaphragm. Chest Surg Clin N Am.1997;7:373-83.
- [11] Jarret F, Bernhardt LC. Right sided diaphragmatic injury. Arch Surg. 1978;113:737-39.
- [12] Lu J, Wang B, Che X, Li X, Qiu G, He S, Fan L. Delayed traumatic diaphragmatic hernia: A case-series report and literature review. Medicine (Baltimore). 2016 ;95(32):e4362.
- [13] de la Rocha AG, Creel RJ, Mulligan GW, Burns CM. Diaphragmatic rupture due to blunt abdominal trauma. Surg Gynecol Obstet. 1982 ;154(2):175-80.
- [14] Carter B, Giuseffi J, Felson B. Traumatic diaphragmatic hernia. Am J Roentgenol Rad Ther. 1951;65:56.
- [15] Adamthwaite DN. Traumatic diaphragmatic hernia: A new indication for laparoscopy. Br J Surg. 1984;71:315.
- [16] Domene CE, Volpe P, Santo MA, Onari P, Szachnowicz S, Pinotti HW. Laparoscopic treatment of traumatic diaphragmatic hernia. J Laparoendosc Adv Surg Tech A. 1998;8(4):225-29.
- [17] Frantzides CT, Carlson MA. Laparoscopic repair of a penetrating injury to the diaphragm: a case report. J Laparoendosc Surg. 1994;4(2):153-56.
- [18] Simpson J, Lobo DN, Shah AB, Rowlands BJ. Traumatic diaphragmatic rupture: associated injuries and outcome. Ann R Coll Surg Engl. 2000 ;82(2):97-100.
- [19] Schumpelick V, Steinau G, Schüper I, Prescher A. Surgical embryology and anatomy of the diaphragm with surgical applications. Surg Clin North Am. 2000;80(1):213-39, xi.
- [20] de Nadai TR, Lopes JC, Inaco Cirino CC, Godinho M, Rodrigues AJ, Scarpellini S. Diaphragmatic hernia repair more than four years after severe trauma: Four case reports. Int J Surg Case Rep. 2015;14:72-76.
- [21] Rosati C. Acute traumatic injury of the diaphragm. Chest Surg Clin N Am. 1998;8(2):371-79.
- [22] Kamelgard JI, Harris L, Reardon MJ, Reardon PR. Thoracoscopic repair of a recurrent diaphragmatic hernia four years after initial trauma, laparotomy and repair. J Laparoendosc Adv Surg Tech A. 1999;9(2):171-75.
- [23] Slim K, Bousquet J, Chipponi J. Laparoscopic repair of missed blunt diaphragmatic rupture using a prosthesis. Surg Endosc. 1998;12(11):1358-60.
- [24] Kurata K, Kubota K, Oosawa H, Eda N, Ishihara T. Thoracoscopic repair of traumatic diaphragmatic rupture: A case report. Surg Endosc. 1996;10(8):850-51.

### AUTHOR(S):

1. Dr. Mahendra Pratap Singh
2. Dr. Yogesh Niwariya
3. Dr. Roman Dutta
4. Dr. Rohit Saluja

### PARTICULARS OF CONTRIBUTORS:

1. Assistant Professor, Department of General Surgery, All India Institute of Medical Sciences, Bhopal, Madhya Pradesh, India.
2. Assistant Professor, Department of Cardiothoracic Surgery, All India Institute of Medical Sciences, Bhopal, Madhya Pradesh, India.
3. Consultant Thoracic Surgeon, Department of Thoracic Surgery, Max Super speciality Hospital Vaishali, Ghaziabad, Uttar Pradesh, India.

4. Ramalinga Swami Fellow (Scientist D, DBT) Department of Biochemistry, All India Institute of Medical Sciences, Bhopal, Madhya Pradesh, India.

### NAME, ADDRESS, E-MAIL ID OF THE CORRESPONDING AUTHOR:

Dr. Mahendra Pratap Singh  
Assistant Professor, Department of General Surgery,  
All India Institute of Medical Sciences, Saket Nagar,  
Bhopal-462024, Madhya Pradesh, India.  
E-mail: drmpsingh2012@gmail.com

### FINANCIAL OR OTHER COMPETING INTERESTS:

None.

Date of Publishing: **Apr 15, 2018**