

# An Anatomical Study of Internal Anal Sphincter with Clinical Correlation

MURALI KRISHNA, MANOJ KUMAR

## ABSTRACT

**Introduction:** The anatomy of Anal Sphincter Complex (ASC) still is a mystery even in this modern time. Knowledge of the exact anatomy is helpful in diagnosis and management of anorectal diseases. With the high prevalence of anorectal diseases it is imperative that there is a clear understanding of the underlying anatomy.

**Aim:** To characterize the constitution of Internal Anal Sphincter (IAS) and understand its clinical impact and to investigate the presence of any midline fixity of fibers of IAS and understand its clinical impact.

**Materials and Methods:** This is an observational study based on cadaveric dissection. Fifteen cadavers were used for the study. The ASC was dissected out from the cadavers and was bivalved to visualize the IAS. Further, dissection was done to delineate the anatomy of IAS. The average length and breadth of IAS was studied. The

number of fibers in IAS was studied. Distance of IAS from anal verge and dentate line was studied. Midline fixity of IAS was studied.

**Results:** The mean length of IAS was 33 mm (0.67), width was 3.6 mm (0.83). The number of fibers was 22.94 (3.55). The average distance from anal verge was 8.0 mm (1.4) and from the dentate line was 10.86 mm (1.95). Midline fixity was appreciated at 12 O' clock and 6 O' clock. The mean width of anterior fixation was 12.15 mm (2.11) and posterior fixation was 4.61 mm (1.02).

**Conclusion:** The detailed anatomy of IAS with number of fibers and their arrangement was described. The anatomy of midline fixity described in this study as per our knowledge has never been reported before in the literature. To know the exact physiological purpose of this structure further study would be required.

**Keywords:** Anal canal, Carcinoma, Cadaveric study, Fissure, Surgery

## INTRODUCTION

To completely understand the complex defecatory disorders an accurate knowledge of the ASC is required. The anal canal is site for several diseases like fistula, malignancy and other physiological diseases like anal incontinence. Understanding the exact anatomy is important in treatment and diagnosis of the above mentioned diseases and also in comparing post operative results [1]. The complex anatomy of ASC makes assessment of functional diseases problematic. Knowledge of accurate anatomy is essential in surgeries like sphincter repair for functional diseases [2].

## MATERIALS AND METHODS

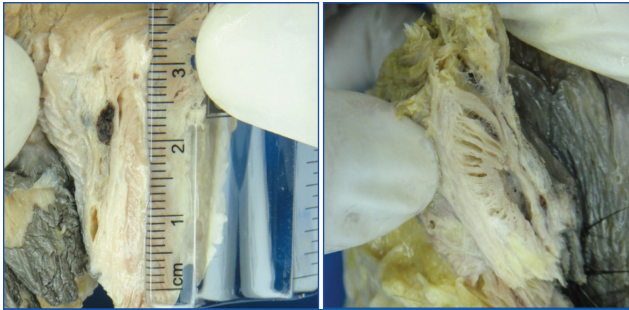
This observational study was based on cadaveric dissection carried out at Armed Forces medical College, Pune, India. Ethical clearance was taken from Institutional Ethical Committee prior to the study. The study period was from October 2013 to October 2015. The cadavers were provided by Department of Anatomy and Department of Forensic

Medicine. All well preserved cadavers were included in the study and in all 15 cadavers were studied.

**Collection of specimens:** The cadavers were positioned so as to expose the perineal area. Using a 10 number scalpel blade an elliptical incision was given around the anal sphincter area to include the sphincter itself and roughly 2 cm adjoining area. The incision was deepened through the ischioanal fossa and through the levator ani muscle. Roughly, 10 cm of the specimen including anal canal and the rectum was mobilized. After reaching the satisfactory depth the rectum was transected at the level to deliver the specimen out. In case of cadavers undergoing postmortem the defect was closed with interrupted sutures over the gluteal region. The defect was left open in embalmed cadavers. All the resected specimen was stored in 10% formalin.

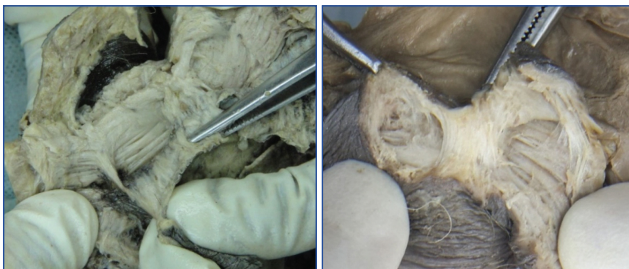**Examination of specimens:** A full thickness incision was given at 3 O'clock position of the specimen to open out the anal canal. The layers of the ASC, namely the external

anal sphincter, conjoint longitudinal muscle and internal anal sphincter were examined under magnification using a standard examination lens. The length and breadth of the IAS in cross-section was measured with a standard ruler. The internal sphincter was then dissected out from the overlying mucosa starting from the 3 O'clock position. The dissection was carried out till 12 O'clock and 6 O'clock positions. The findings were noted. Part of the sphincter at 12 O'clock and 6 O'clock was excised for subjecting to microscopic studies [Table/Fig-1-5].



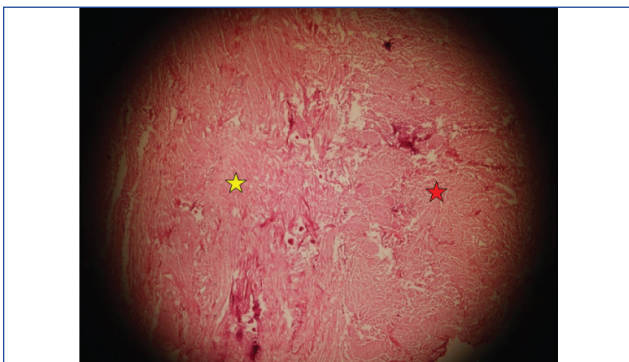
[Table/Fig-1]: Measuring length of internal anal sphincter.

[Table/Fig-2]: Slanting fibres of internal anal sphincter.



[Table/Fig-3]: Narrow posterior fixation of fibres.

[Table/Fig-4]: Broad anterior fixation of fibres.



[Table/Fig-5]: Microscopic view of midline fixation and IAS fibres.

\*Red star- Denotes the midline fixation,

\*\*Yellow star- denotes the IAS fibres. The muscle fibers in the midline fixation denote that it has an active physiological role.

## RESULTS

In this study it was found that IAS was formed out of individual fibers which ranged from minimum of 16 to maximum of 28. These fibers were arranged at an angle to the midline resembling a venetian blind. The average distance of the

sphincter from dentate line was 10.86 mm and the average distance from anal verge was 8.0 mm. Two broad strands were seen fixing the individual fibers of IAS at 6 O'clock and 12 O'clock. The posterior fixation was comparatively broader as compared to anterior fixation [Table/Fig-5,6].

Specimens	Length (mm)	Width (mm)	Number of fibres	Distance from dentate line (mm)	Distance from anal verge (mm)	Anterior fixation (mm)	Posterior fixation (mm)
1	25	3	24	8	9	6	15
2	26	4	16	9	5	-	-
3	21	4	23	15	10	3.5	13
4	26	3	19	12	8	4	14
5	32	2	19	10	7	3	8
6	25	4	19	9	7	5	12
7	33	5	24	12	8	6	14
8	39	3	21	10	9	5	9
9	40	4	26	11	10	-	-
10	40	3	22	9	7	6	13
11	38	5	26	13	8	4	10
12	40	4	28	12	8	5	13
13	39	3	25	9	9	4	14
14	36	4	24	13	6	3.5	12
15	35	3	28	11	9	5	11

[Table/Fig-6]: Outcome of the study.

## DISCUSSION

The ASC is an integral part of the human body which helps in the normal social functioning of an individual. The anal sphincter has also been dubbed as 'intelligent sphincter' as it has the ability to distinguish between gaseous, liquid or solid substances [3]. Even after being such an important part of human body, the exact anatomy of the IAS is yet not described. Descriptive studies of IAS are very few. Study of ASC and IAS have been usually done using radiographic techniques like ultrasound [4,5] and MRI particularly with endoanal probes [6,7].

The first study on the cadaveric dissection was done by Uz A et al., provided new insight into the anatomy of IAS. They have described the structure of set of ribbons of smooth muscle. We confirm similar arrangement [8]. But the exact types of arrangement of these ribbons was lacking in their study. The positioning of the ribbons at 45 degree slanting toward the anal lumen, which is demonstrated here is likely to have functional advantage possibly by cranial lift of the anus for better sphincter control [Table/Fig-2].

**Number and nature of specimen:** The study by Uz A et al., was conducted, they examined total of 24 cadavers. In this study the pelvises were removed at the level of L5 and cut sagittally [8]. In the present study we have examined 15 cadavers and only the anal canal and rectum part of the specimen was dissected out.

**Length of IAS:** The average length of IAS in our study was 33 mm with SD of 0.67 [Table/Fig-1]. This is more than what

is quoted in literature. The study done by Tsunoda A et al., measured the length and width of IAS from 62 resected specimen of abdomino perineal resection of the rectum for malignancy. The mean length of the IAS in their study was  $25.8 \pm 4.1$  mm [9]. The higher mean value of the length of IAS may be due to some racial differences and low sample size of our study.

The differences can also be explained by the character of specimen, which were fresh after surgery and ours formalin fixed specimen might have contracted leading to smaller length.

In literature it has been mentioned that the muscle fibers and fascia joined at three points around the anal canal to form columns which extended distally into the lumen [8]. We could not find such coalescing at three points. But we found the smooth muscle ribbons were bound together at 6 and 12 O' clock as mid line fixity. The same is described in detailed below.

**Width of IAS:** The mean width of IAS in our study was  $3.6 \pm 0.83$  mm. This value appears to be concurrent with previous studies. Tsunoda et al., in their study described the mean width of IAS to be  $4.0 \pm 1.1$  mm [9].

**Number of fibers:** In our study the individual rings constituting the IAS was counted in all the specimens. The mean value for the number of fibers was  $22.93 \pm 3.55$  with a range of 16-28. This value is comparable to mean value found in the study by Uz A et al., [8]. The average number of fibers in that study was  $26.33 \pm 2.93$  with a range of 20-30.

**Midline fixity:** The finding of midline fixity is the new finding of the present study as it has never been described before in literature. There are some elastic like fibers binding these ribbons all around the sphincter in 360 degree. But in the mid line they are well defined.

At 12 O' clock it is broad at the lower end and tapering cranially [Table/Fig-4]. These fibers comes out from the inter ribbon space and join together to form an effective binder of all the ribbons so that it acts as a single force for effective sphincter function. At 6 O' clock i.e., the posterior mid line, it is narrower [Table/Fig-3]. The overall anatomy of IAS as found in our study confirms to that described by Uz A et al., [8].

The individual fibers of IAS are covered by a fascia thus allowing for easy separation of these fibers from the surrounding structures. Uz A et al., describes that the fascia covering the fibers coalesce at three equidistant points to form columns [8]. From anterior view these points were located anteriorly at the right (5 O' clock position), posteriorly at the right (1 O' clock position) and laterally at the left (9 O' clock position). Further details as to the width of the column were not described.

In comparison to their study we could see that the fascia covering the fibers coalesced in the midline at 6 O' clock and 12 O' clock. The width of the columns was also different with the posterior column being broader than the anterior column. The mean width of posterior column was  $12.15 \pm 2.11$  mm and that of anterior column was  $4.61 \pm 1.02$  mm.

This hereto undescribed anatomy of IAS may play an important role to ensure safe surgical intervention in the anorectal region. This might also be related to embryological development from cloaca to bladder and anorectum. It can also be explained by the bilateral nerve supply to this mid line structure, which is evident in the external sphincter. This knowledge can be applied in the treatment of chronic fissure in ano in the form of bilateral partial internal sphincterotomy for better result.

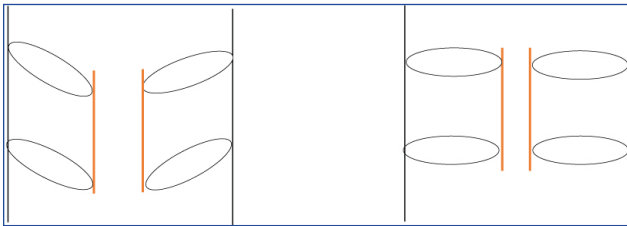
**Distance from the anal verge:** In our study the mean distance from anal verge was calculated to be  $8.0 \pm 1.4$  mm. This distance has not been quoted in the literature.

**Distance from the dentate line:** The mean distance in our study was  $10.86 \pm 1.95$  mm. The figures quoted in the literature by Tsunoda et al., is  $11.3 \pm 1.3$  mm. Both the values are in rough approximation.

**Cross-sectional analysis:** To know the further anatomy a cross-section of midline column was obtained and studied under low power microscope. This sort of cross-sectional anatomy has also not been described in the literature. The microscopic study showed the fibers in the column running perpendicular to the IAS fibers [Table/Fig-5]. The exact anatomy of anal canal still remains debated. The present study just adds a new point to this debate. The anal sphincter remains one of the most important parts of human body both anatomically and physiologically and moreover psychologically. The poor quality of life of patient suffering from anal incontinence bears witness to this fact. A study conducted by Khan RM et al., found the prevalence of fissure in ano in patients visiting the hospital with anorectal complaints to be 15.6%. [10] Also the anal sphincter involvement occurs in rectal cancer and carcinoma of anal canal. The knowledge of exact anatomy of anal sphincter will help in improving the surgical outcome of patients undergoing anorectal surgery.

## Clinical Correlation

**Function of midline fixity:** The anal continence is maintained by several factors. These include the angulation caused by puborectalis sling, a functional ASC and the presence of mucosal cushions [11]. It has been demonstrated that, the anal sphincter even after maximum contraction is not able to close the anal canal by itself. For this purpose, the mucosal and vascular cushions act as a washer thus obliterating the anal canal and thus maintaining continence.



**[Table/Fig-7]:** Proposed physiological function of midline fixation. As demonstrated in the histology slide the midline fixation is composed of muscle fibres. These fibres on contracting will cause a closer approximation of individual IAS fibres.

The midline fixity mechanism described in our study may also contribute some part in maintenance of continence. Using the venetian blinds analogy as described by Uz A et al., [8] we tried to explain the function of midline fixity.

As demonstrated in the histological cross-section, the midline fixity is composed of muscle fibres. Contraction of this midline fixity will bring the circumferential fibers from an angle of 45 degrees to 90 degrees, thus further closing the anal canal. [Table/Fig-7]. Though, there is no objective evidence for this mechanism, this is just a hypothesis.

**Fissure in ano:** It is one of the most common pathological conditions encountered by surgical specialist. Though, conservative management has been tried in form of calcium channel blockers and topical nitrate ointments, surgical management still remains the gold standard. The indications for surgery are persistent pain and bleeding and lack of response to medical management.

As demonstrated in our study, the posterior midline fixity is situated at 6 O' clock position. Doing a posterior midline sphincterotomy, as described by Eisenhammer, will disrupt this band of posterior fixity and due to the hypothesized role in maintaining continence, it may lead to development of incontinence. Since, other mechanisms are intact the end result would be a minor incontinence to flatus and not complete incontinence.

Another controversy surrounding the surgery for sphincterotomy has been the extent of division of the IAS. Though the earlier surgeries advocated complete division the latest Cochrane review for surgeries for anal fissure [12] has concluded that the IAS should be divided upto the dentate line. Keeping our study in mind, the total length of IAS was 33 mm. also the length of IAS below the dentate line was 10.86 mm. Thus, almost one third of the sphincter is present below the dentate line. Another study done by Murad-Regadas et al., [13] concluded that the safe extent of division is less than 25 % of the total sphincter length. Thus, division of IAS fibers above the dentate line is not warranted and may lead to increased morbidity of the surgery.

**Sphincter preservation in malignancy:** Preservation of

ASC while adhering to the oncological principles of surgery has been the target of surgical resection of lower one third rectal cancers. The distal margin for excision of low rectal growth was initially advocated to be 5 cm [14] and has now been reduced to 1 cm [15], provided a proper total mesorectal excision is done. Ultra low anterior resection following neoadjuvant chemoradiation with 1 cm distal margin has shown no statistical difference in oncologic outcome when compared in terms of local recurrence and overall survival.

With the mean length of IAS being 33 mm and giving an additional 1 cm distal resection margin, it can be inferred that rectal growth with lower level at 44 mm and above from the anal verge will be amenable for sphincter sparing surgery. Such low lying growths can be easily palpated while doing a digital rectal examination. This once more emphasizes the importance of doing a proper digital rectal examination in any patient presenting with anorectal complaints. [16]

## LIMITATION

Comparatively small sample size is one of the limitation of our study and further studies would be required to understand the complete physiological importance.

## CONCLUSION

The anal sphincter is an integral part of human body and this study has proven that the exact anatomy of ASC is still unclear. Since, there has been no Indian study regarding the anatomy of anal canal the measurements mentioned in this study can help in treatment of benign and malignant diseases of anal canal. Also, the midline fixity as demonstrated in this study could be another factor involved in maintenance of continence of anal canal.

## REFERENCES

- [1] Al Ali S, Blyth P, Beatty S, Duang A, Parry B and Bissett IP. Correlation between gross anatomical topography, sectional sheet plastination, microscopic anatomy and endoanal sonography of the anal sphincter complex in human males. *J. Anat.* 2009;215(2):212-20.
- [2] Macchi V, Porzionato A, Stecco C, Vigato E, Parenti A, Caro RD. Histo-topographic study of the longitudinal anal muscle. *Clin Anat.* 2008;21(5):447-52.
- [3] Agarwal S. Anatomy of the pelvic floor and anal sphincters. *Journal of International Medical Sciences Academy.* 2012;25(1):19-21.
- [4] Poen AC, Felt-Bersma RJ. Endosonography in benign anorectal disease: an overview. *Scand J Gastroenterol Suppl.* 1999;230:40-48.
- [5] Wong WD. Endosonography of the anal canal. *Perspectives in Colon and Rectal Surgery.* 1998;10:01-21.
- [6] Stoker J, Rociu E, Zwamborn AW, Schouten WR, Laméris JS. Endoluminal MR imaging of the rectum and anus: Technique, applications, and pitfalls. *RadioGraphics.* 1999;19(2): 383-98.
- [7] Endocavitary MRI of the Pelvis. Ed. by N M deSouza. Harwood Academic Publishers, Amsterdam, The Netherlands. 2001. pp. 114.

- [8] Uz A, Elhan A, Ersoy M, Tekdemir I. Internal anal sphincter: an anatomic study. *Clinical Anatomy*. 2004;12(1):17-20.
- [9] Tsunoda A, Shibusawa M, Kawamura M. Anatomical measurement of the internal anal sphincter-the relative site of the dentate line in the internal anal sphincter. *Nihon Geka Gakkai Zasshi*. 1993;94(7):686-89.
- [10] Khan RM, Itrat M, Ansari AH, Ahmer SM, Zulkifle. Prevalence of fissure-in-ano among the patients of anorectal complaints visiting nium hospital. *J Community Med Health Educ*. 2015;5:344.
- [11] Rao SS. Pathophysiology of adult fecal incontinence. *Gastroenterology*. 2004;126(Suppl 1):S14-22.
- [12] Nelson R. Operative procedures for fissure in ano. *Cochrane Database Syst Rev*. 2002;(1):CD002199.
- [13] Murad-Regadas SM, Fernandes GO, Regadas FS, Rodrigues LV, Pereira Jde J, Regadas Filho FS, et al. How much of the internal sphincter may be divided during lateral sphincterotomy for chronic anal fissure in women? Morphologic and functional evaluation after sphincterotomy. *Diseases of the Colon and Rectum*. 2013;56(5):645-51.
- [14] Lichliter W, Fleshman J. Rectal cancer. *Clinics in Colon and Rectal Surgery*. 2015;28(01):003-04.
- [15] Andreola S, Leo E, Belli F, Bonfanti G, Sirizzotti G, Greco P, et al. Adenocarcinoma of the lower third of the rectum surgically treated with a <10-mm distal clearance: preliminary results in 35 no patients. *Ann Surg Oncol*. 2001;8(7):611-15.
- [16] Joguet E, Robert R, Labat JJ, Riant T, Guérineau M, Hamel O, et al. Anatomical basis of digital rectal examination. *Surgical and Radiologic Anatomy*. 2012;34(1):73-79.

**AUTHOR(S):**

1. Dr. Murali Krishna
2. Dr. Manoj Kumar

**PARTICULARS OF CONTRIBUTORS:**

1. Senior Resident, Department of Surgery, Armed Forces Medical College, Pune, Maharashtra, India.
2. Professor, Department of Surgery, Armed Forces Medical College, Pune, Maharashtra, India.

**NAME, ADDRESS, E-MAIL ID OF THE CORRESPONDING AUTHOR:**

Dr. Manoj Kumar,  
Professor, Department of Surgery, Armed Forces Medical College, Pune-411040, Maharashtra, India.  
E-mail: drmanojkumar@yahoo.co.in

**FINANCIAL OR OTHER COMPETING INTERESTS:**

None.

Date of Publishing: Oct 01, 2017