

# A Morphometric Analysis of Fibularis Tertius Muscle in Eastern Indian Population

GYANARANJAN NAYAK

## ABSTRACT

**Introduction:** Fibularis tertius is a unipennate muscle of extensor compartment of leg exclusively found in humans. Fibularis tertius muscle flap is used for transposition and correcting any laxity in the ankle joint by foot surgeons. Variable insertion of the muscle may play a role in causation of torsional stress as observed in certain fractures of foot.

**Aim:** To study the incidence of fibularis tertius muscle with its dimensions and note the variations in origin and insertion of the muscle in cadaveric limbs.

**Materials and Methods:** Hundred cadaveric lower

limbs (50 right and 50 left) were dissected and analysed macroscopically to find out the incidence, dimensions and variations in origin and insertion of the fibularis tertius muscle.

**Results:** Fibularis tertius was present in all the limbs. It was inserted to fourth or fifth metatarsals. The length and width of the muscle and its tendon were also noted.

**Conclusion:** Distal attachment of fibularis tertius is variable making a precise knowledge of the muscle necessary for foot surgeons in performing tendoplasty or tendon transfer surgeries.

**Keywords:** Lower limb, Myocutaneous flap, Tendoplasty, Variations

## INTRODUCTION

Fibularis tertius is a muscle of the anterior compartment of leg. It's absent in hominid apes and found exclusively in humans [1]. The fibularis tertius is considered as the fifth tendon of extensor digitorum longus. It arises from the medial surface of fibula, interosseous membrane of leg and anterior crural intermuscular septum. The insertion of the muscle is usually onto the base of the fifth metatarsal [2,3]. The muscle acts as a dorsiflexor and evertor of the foot. The everting action of the muscle along with fibularis longus and brevis elevates the foot and helps the toes to clear the ground thus improving the economy of bipedal mode of locomotion [2,4,5].

The muscle can sense sudden inversion and contracts reflexly to prevent damage to the anterior tibio-fibular ligament which usually gets sprained in ankle injuries [6].

Appearance of fibularis tertius is related to the development of extensor digitorum longus. The fibularis tertius gets progressively separated from extensor digitorum longus until it is inserted laterally onto the fifth metatarsal [7]. Alternatively, it is described as the migrated part of extensor digitorum brevis of little toe [8,9]. Some researchers also opine that the muscle represents extensor digiti minimi with displaced insertion to the base of the fifth metatarsal [1].

Presence of fibularis tertius in human beings and its absence in non human primates hints towards the evolution of the muscle and establishes its role in terrestrial bipedalism. Thus, the muscle is very important from an evolutionary point of view.

Literature describes various variations of fibularis tertius muscle. These are as follows-the muscle may be absent (in about 18% cases), duplicated or it may give additional slip to the fascia of fourth interosseous muscle of foot or extensor aponeurosis of little toe [3,4,9]. Variable insertion of fibularis tertius muscle may be responsible for causation of fractures such as Jone's fracture [10].

Fibularis tertius is useful in plastic and orthopaedic surgeries. It's used for performing tendoplasty, tendon transfer and resection surgeries of the foot. Flap from the muscle and its tendon are used for transposition, correcting any laxity in the ankle joint and transplantation surgeries on foot [11].

As the fibularis tertius muscle is highly significant from evolutionary and surgical points of view, the present study was conducted to find the measurements and variations of the muscle.

## MATERIALS AND METHODS

This cross-sectional study was conducted in the Department

of Anatomy at Medical College in Bhubaneswar, Odisha, India between the period of January 2017 to March 2017. The study included 100 (50 right and 50 left) formalin preserved cadaveric lower limbs. The dissection was carried out on the formalin preserved limbs extracted from routine cadaveric dissection classes for undergraduate students in the past ten years. The limbs were dissected cleanly and macroscopically studied for the frequency, origin and insertion of the fibularis tertius muscle. The length and width of the muscle belly and tendon of fibularis tertius muscle were measured with the help of a measuring scale, thread and marker pens.

## STATISTICAL ANALYSIS

The data obtained from the measurements of the muscle belly and tendon of fibularis tertius was tabulated and analysed using Microsoft Excel software. Arithmetic mean was calculated for each parameter of the muscle.

## RESULTS

The fibularis tertius was found in all the lower limbs. The incidence was 100%.

The muscle took its origin from the usual anatomical site (lower one fourth of medial surface of shaft of fibula) in all the limbs. However, the insertion showed variations. In 94 lower limbs (94% of cases) the muscle was inserted onto the base of the fifth metatarsal [Table/Fig-1].

However, in four lower limbs (three right and one left) the insertion was on dorsum of the fifth metatarsal upto the metatarsophalangeal joint [Table/Fig-2]. In the remaining two lower limbs (one right and one left) the tendon of fibularis tertius was inserted near the base of fourth metatarsal [Table/Fig-3].

Morphology of the muscle revealed the mean length of the muscle belly as 23 cm (range being 14.3-28.6 cm). The mean width of the muscle belly was found to be 2 cm (range being 1.4-2.3 cm). The mean length of the tendon of fibularis tertius was found to be 5 cm (range being 4.1-9.8 cm) whereas, its mean width was derived to be 0.4 cm (range being 0.2-0.8 cm).

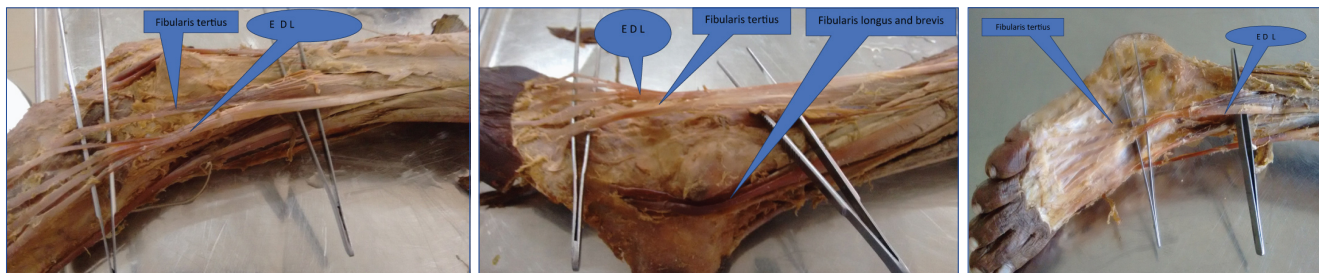
## DISCUSSION

Fibularis tertius muscle is inherent to humans and man is the only primate to have this muscle. The muscle is variable in its attachment. It's postulated that the muscle has evolved due to functional demands of bipedal gait and plantigrade foot [9]. Fibularis tertius can be found early in the developing human embryo. So, fibularis tertius muscle may be a specific character developed early in the growth of the human race as this muscle is found only in humans in contrast to other hominid apes [12]. Fibularis tertius with its not so significant function and negligible aesthetic aspect serves as a good source of myocutaneous flap in reconstruction surgeries of distal segments of lower limb.

We have found fibularis tertius muscle in all the lower limbs studied by us. Krammer E et al., have reported an incidence of 92.2% [13]. Incidence was reported as 95.5% and 93.3% by Kunnika C et al., [14] and Rourke K et al., [15] respectively. Joshi SD et al., have reported the incidence of fibularis tertius as 89.55% in Indian population [9].

The current study has revealed the usual insertion of fibularis tertius onto the base of fifth metatarsal in majority of cases. However, the fibularis tertius was also found to get inserted on the dorsal surface of fifth metatarsal as well as the fourth metatarsal. Various authors have found variations in the insertion of fibularis tertius. Bhadkamkar and Mysorekar have reported in their study that the fibularis tertius tendon may get inserted onto the extensor tendon of fifth toe or onto the fourth or even third metatarsal [16]. Joshi SD et al., have reported the insertion of fibularis tertius tendon up to the metatarsophalangeal joint of the fifth toe in 4% cases and onto the proximal phalanx of little toe in 1.5% cases [9]. Rourke K et al., have reported that fibularis tertius was found to get inserted on the dorsal surface of both fourth and fifth metatarsals [15]. Figen T et al., found that the tendon of fibularis tertius got inserted on the entire dorsolateral surface of the fifth metatarsal [17].

The current study has found out the mean length and width of both muscle belly and tendon of fibularis tertius. These



**[Table/Fig-1]:** Photograph showing the insertion of Fibularis tertius onto base of fifth metatarsal.

**[Table/Fig-2]:** Photograph showing the insertion of Fibularis tertius onto dorsum of fifth metatarsal.

**[Table/Fig-3]:** Photograph showing the insertion of Fibularis tertius onto dorsum of fourth metatarsal.

\* (EDL - Extensor Digitorum Longus)

findings are comparable to those of Verma and Seema [12]. They have reported the mean length of muscle belly as 21 cm and mean width as 1.9 cm. In their study the mean length and width of the tendon of fibularis tertius were 6 cm and 0.5 cm respectively. Gusmao LCB et al., have reported a mean length of 17.89 cm and mean width of 1.95 cm for the muscle belly. They have reported a mean length of 1.2 cm and mean width of 0.55 cm for the tendon [18].

Our study observed fibularis tertius in all the cadaveric lower limbs. The eversion function of fibularis tertius is a characteristic feature of human locomotion [19]. In non human primates lacking fibularis tertius, the fibularis longus and brevis play a more active role in the swing phase of bipedal locomotion.

## CONCLUSION

Frequent variation in the insertion of a lateral muscle of leg such as fibularis tertius indicates that it is still in the process of evolution. Some muscles are degenerating (like plantaris) and some are appearing (like fibularis tertius).

Soft tissue reconstruction of the lower limbs is particularly cumbersome due to paucity of subcutaneous tissue and absence of muscle protection for the osteotendinous and neurovascular structure. So myocutaneous flaps are raised in concerned surgeries. This need can be fulfilled with a muscle like fibularis tertius due to its insignificant action. The current study has highlighted the incidence, variations in the insertion and dimensions of fibularis tertius muscle which can be useful for surgeons while raising myocutaneous flaps in the lower limb.

## REFERENCES

- [1] Bergman RA, Thompson SA, Afifi AK, Saadeh FA. Compendium of Human Anatomic Variations, Text, Atlas and World Literature. Baltimore and Munich, Urban and Schwarzenburg: 1988. Page 141.
- [2] Standring S, Gray's Anatomy: the anatomical basis of clinical practice. 4<sup>th</sup> Edition. London: Churchill Livingstone, Elsevier: 2008. Page 1419.
- [3] Romanes JG. Cunningham's text book of Anatomy. 11<sup>th</sup> Edition. London. Oxford University Press: 1978. p 377-78.
- [4] Witvrouw E, Vanden Borre K, Willems TM. the significance of peroneus tertius muscle in ankle injuries. A prospective study. Am J Sports Med. 2006;34:1159-63.
- [5] Das S, Haji Suhaimi F, Abd Latiff A, Pa Pa Hlaing K, Abd Ghafar N, Othman F. Absence of the peroneus tertius muscle: Cadaveric study with clinical considerations. Rom J Morphol Embryol. 2009;50:509-11.
- [6] Moore KL, Dalley AF, Agur AM. Clinical Oriented Anatomy, 6<sup>th</sup> Edition. India, Wolters Kluwer Pvt Ltd. 2009. p 589.
- [7] Jungers WL, Meldrum DJ, Stern JT. The functional and evolutionary significance of the human peroneus tertius muscle. J Hum Evol. 1993;25:377-86.
- [8] Word Jones F. Structure and function as seen in the foot. 2<sup>nd</sup> Edition. London: Baillire, Tindall and Co: 1949. p 158-59.
- [9] Joshi SD, Joshi SS and Athavale SA. Morphology of peroneus tertius muscle. Clin Anat. 2006;19:611-14.
- [10] Vertullo CJ, Glisson RR, Nunley JA. Torsional strains in the proximal fifth metatarsal: implications for Jones and stress fracture management. Foot Ankle Int. 2004;25:650-56.
- [11] Ozkan T, Tuncer S, Ozturk K, Aydin A, Ozkan S. Tibialis posterior tendon transfer for persistent foot drop after peroneal nerve repair. J Reconstr Micro Surg. 2009;25:157-64.
- [12] Verma P, Seema. Analysis of Fibularis tertius in terms of frequency, morphology, morphometry and clinical significance in North Indian Cadavers. Int J Anat Res. 2015;3(4):1646-50.
- [13] Krammer E, Lischka M, Gruber H. Gross anatomy and evolutionary significance of the human Peroneus III. Anat Embryol. 1979;155:291-302.
- [14] Kunnika C, Jantima R, Wimon R. The presence of the peroneus tertius muscle in Thai people. Siraj Hosp Gaz. 2004;56:216-21.
- [15] Rourke K, Dafyd H, Parkin IG. Fibularis Tertius: Revisiting the Anatomy. Clin Anat. 2007;20:946-49.
- [16] Bhadkamkar AR and Mysorekar VR. Anomalous peroneus tertius and extensor digitorum longus muscles. J Anat Soc Ind. 1962;10(11):37-38.
- [17] Taser F, Shafiq Q, Toker S. Coexistence of anomalous m. peroneus tertius and longitudinal tear in the m. peroneus brevis tendon. Eklem Hastalik Cerrahisi. 2009;20(3):165-68.
- [18] Gusmao LCB, Brito lima JS, Durate FHG, Farias Souto AG, Melo Voloso Couto B. Anatomical basis for the use of the fibularis tertius muscle in myocutaneous flaps. Revista Brasileira de Cirurgia Plastica. 2013;28(2):191-95.
- [19] Yammine K, Eric M. The fibularis (peroneus) tertius muscle in humans: a meta-analysis of anatomical studies with clinical and evolutionary implications. Bio-Med Research International, vol 2017, Article ID 6021707, 12 pages, 2017. doi:1155/2017/6021707.

### AUTHOR(S):

1. Dr. Gyanaranjan Nayak

### PARTICULARS OF CONTRIBUTORS:

1. Assistant Professor, Department of Anatomy, I M S and SUM Hospital, SOA University, Bhubaneswar, Odisha, India.

### NAME, ADDRESS, E-MAIL ID OF THE CORRESPONDING AUTHOR:

Dr. Gyanaranjan Nayak,  
Flat No-111, Manorama Metro Complex, Malasahi,  
Mangalabag, Cuttack-753001, Odisha, India.  
E-mail: drgrn82@gmail.com

### FINANCIAL OR OTHER COMPETING INTERESTS:

None.

Date of Publishing: Oct 01, 2017