

Magnetic Resonance Spectroscopy in Temporal Lobe Epilepsy

SIDDHARTH PRAKASH, VIKRAM NARANG, RANJAN KUKRETI, DEEPAK GOEL

ABSTRACT

Introduction: Epilepsy affects 2% to 5% of the population at some time in their lives and hippocampal sclerosis accounts for 50% to 70% of cases. The role of proton magnetic resonance spectroscopy (1H-MRS) has been shown to be a useful tool in investigating in vivo and non-invasively key molecules of brain metabolism but the data from Indian subcontinent is scarce.

Aim: To evaluate and compare the visual and volumetric findings on Magnetic Resonance Imaging (MRI) and to study the metabolite concentration variation in patients with Temporal Lobe Epilepsy (TLE) through MR Spectroscopy.

Materials and Methods: The present case control study was done over a period of 18 months in Department of Radiodiagnosis, Himalayan Institute of Medical Sciences, Dehradun. The patients with temporal lobe epilepsy were studied with selection criteria defined under International League against Epilepsy 1989 convention. The matched

non-epileptic controls of similar age and sex were taken up for the study. MR examination was performed on a 1.5 –T MR System with a circular polarizing head coil. Statistical analysis was done using Chi square test and p-value was calculated accordingly.

Results: In patients by including both the normally lateralized and bilaterally lateralized groups, NAA was able to lateralize in 14 of 15 cases. NAA/Cr and NAA/Cho both performed less well than NAA and NAA/Cr+Cho with only 11 and 10 patients, respectively being lateralized correctly. NAA concentration and NAA/Cr+Cho ratio were reduced in hippocampi with HS (Hippocampal sclerosis) when compared with control and contralateral sides (at $\alpha = 0.01$).

Conclusion: MR imaging is the neuroimaging variety of choice for such patients. But even MR imagine cannot lateralize all cases. Better sensitivity has been reported with magnetic resonance spectroscopic but the findings have been found to vary widely.

Keywords: Brain, Hippocampal sclerosis, Seizures

INTRODUCTION

Epilepsy affects 2% to 5% of the population at some time in their lives, intractable seizures occurring in 0.2% to 0.5%. The partial epilepsies are known to be the most intractable with TLE being the most common partial epilepsy. Hippocampal sclerosis accounts for 50% to 70% of cases. It can be diagnosed using MRI. Quantitative MRI has increased the sensitivity towards the diagnosis. However, recently 1H-MRS has been shown to be a useful tool in investigating in vivo and non-invasively key molecules of brain metabolism relevant to the pathophysiology and neuropathology of mesial temporal structures involved in TLE [1-3].

Various metabolites such as N-acetyl aspartate (NAA), creatine + phosphocreatine (Cr), and compounds containing choline (Cho) can be studied in proton spectra from regions located in temporal lobes. Neuronal loss results in reduction

in NAA found in neurons and increases in Cho and Cr may be a reflection of astrocytosis. Proton MR spectroscopy is able to detect abnormalities in medial temporal lobes of medically intractable patients with TLE (reduced NAA/Cr ipsilateral to the ictal EEG focus) with a normal MRI volumetric study of the hippocampus [3-5].

MATERIALS AND METHODS

This prospective case-control study was carried out, after ethical clearance from the institution board, in the Department of Radio-diagnosis, in Himalayan Institute of Medical Sciences, Swami Rama Nagar, Dehradun, India, between the period of June 2003–December 2004.

Study Subject: The patients (n=19) with temporal lobe epilepsy were studied with selection criteria defined under International League Against Epilepsy 1989 [6] convention i.e., a) Patient suffering from complex partial seizure; b) Patient

suffering from generalized tonic clonic seizure who had history of febrile convulsion; c) Patient suffering from refractory seizure (i.e., seizure not controlled on more than two anti-epileptic drugs with adequate dosage). The 19 patients underwent MRI for evaluation for TLE. Out of which, 11 male were male and 8 were females. The median age of onset of habitual epilepsy was 10 years (6 months - 43 years) 4 patients had history of febrile seizures. All the patients were diagnosed clinically as TLE.

Control: The matched non-epileptic controls (n=15) of similar age and sex were taken up for the study. MR examination was performed on a 1.5-T MR System (Siemens Magnetom Vision) with a circular polarizing head coil (Siemens Medizintechnik, Erlangen, Germany). The following sequences were obtained:

1. Sagittal and oblique coronal and axial T2-weighted turbo spin echo sequences were obtained (repetition time [TR]=5400 millisecond; echo time [TE]=99 millisecond; flip angle=90 degree; section thickness=3 mm/2 mm; intersection gap=0.0 mm; field of view=23 cm with a matrix of 256x512). The oblique coronal plane was obtained perpendicular and the axial plane to be parallel to the longitudinal axis of the hippocampal body.

2. T1 weighted spin echo sequences in the axial and coronal planes (500/12/90/5/0.0/250) and a 3D magnetization-prepared rapid gradient echo (MPRAGE) sequence in the sagittal plane, 10/4/200/1(TR/TE/TI/NEX), flip angle of 12^o, 128 partitions. In both the sequences matrix size was 256x256.

The images obtained were assessed under the following headings:

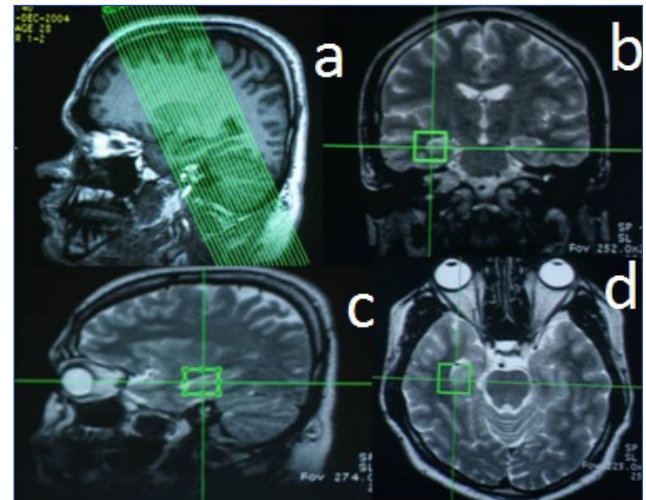
Visual Morphological assessment: This was done for evaluation of presence of atrophy on the T2 weighted images-

- Changes in the signal intensity.
- Shape and orientation of the hippocampal formation.
- The presence of a mass lesion.
- Presence of abnormalities of the temporal lobe cortical ribbon, including its morphology, location, extent.
- Presence of heterotopia was considered a sign of disease.

On the T1-weighted images, on the other hand a loss of gray matter volume and/or a decreased signal in the hippocampus and /or the temporal lobe white matter and/or loss of internal structure of the hippocampus were considered a proof of disease.

Volumetric measurements: This was obtained by manual tracing using a mouse driven cursor in the region of interest in

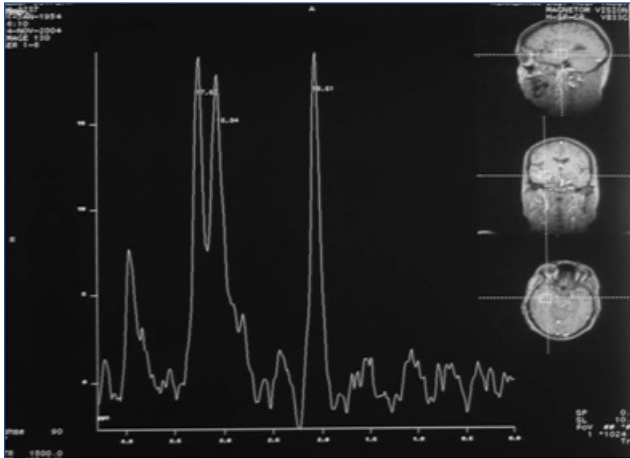
each section of the T1 weighted MPRAGE sagittal sequence and obtaining the surface area. The volume was then calculated by multiplying the area with the inter-slice distance/partition thickness. Subsequently, hippocampal volume ratio was acquired with the smallest volume forming the numerator [Table/Fig-1 a-d].



[Table/Fig-1]: (a) Sagittal localizer showing planning of oblique coronal images perpendicular to the long axis of hippocampus; (b-d) Voxel localization over the right hippocampal head on the coronal image, sag and axial images.

Magnetic Resonance Spectroscopic Imaging: All the above patients including controls were subjected to a spectroscopic evaluation on the same equipment. Two dimensional fast low angle shot (FLASH) images (200/6) were acquired in coronal, sagittal and oblique transverse planes for localisations of epileptic focus. Single voxel Proton MR Spectra were obtained with an 8 ml voxel (20x20x20 mm³) in each of the medial temporal lobes including a part of the hippocampus. Attention was kept on the reproducibility of the voxel position with respect to the brain stem and hippocampus. Water suppression was effected by a 90-degree Gaussian pulse. An interactive shimming was subsequently performed to obtain a least FWHM (6-8) and the highest possible integral value. Spectra were acquired using a spin echo sequence with an echo time (TE) of 135 msec and a Repetition Time (TR) of 1365 ms and number of excitation as 256. To compensate for eddy current artefacts, we obtained a reference scan with the same scan parameters but with 8 acquisitions and with no water suppression. Automatic phase correction was done. Three resonances of importance could be identified, viz NAA at 2 ppm, Cr at 3 ppm and Cho at 3.2 ppm. These peaks were quantified by simple triangulation as well as automatic calculation using the proprietary software. Metabolite signal intensities and metabolite ratios like NAA/ (Cho+Cr), NAA/Cr, NAA/Cho were calculated and analyzed in reference to the data from the control group [Table/Fig-2].

These were subsequently categorized as under and analyzed [Table/Fig-3].



[Table/Fig-2]: Single voxel proton MR Spectra from right hippocampal head.

Category	Label	Explanation
Normal	N	Both values are in the normal range; there is no abnormal asymmetry.
Correctly lateralized; clear lateralization	Lat	The ipsilateral value is abnormal; there is a clear abnormal asymmetry.
Bilateral	Bil	Both values are abnormal; there is no asymmetry.
Bilateral but lateralized correctly	B/L Lat	Both values are abnormal; there is a clear abnormal asymmetry.
Normal but lateralized correctly	N Lat	Both values are in the normal range; but there is a clear abnormal asymmetry.
Incorrectly lateralized	Wrong(W)	The value is worse on the contralateral side; with abnormal asymmetry.

[Table/Fig-3]: Correlation of MRV and MRS data for lateralization of TLE patients.

RESULTS

MR scan of 15 healthy individuals was performed and reference values for all the parameters were calculated from the pooled values. On 15 patients (control) hippocampal volumetry was performed and hippocampal volume ratio calculated [Table/Fig-4].

The absolute value of NAA on MRS in control varied from 15.39 to 22.0 and those of NAA/Cho+ Cr ratio varied from 0.65 to 0.96. The mean value of NAA, NAA/Cho+Cr, NAA/Cr, and NAA/Cho corresponded to 17.87, 0.79, 1.67 and 1.52 respectively [Table/Fig-5].

The side of lateralization determined by clinical and morphological examination was termed ipsilateral, and

the other side contralateral. Total 14 (R-9, L-5) cases were lateralized on the basis of morphological data. Signal changes in hippocampus with loss of internal architecture were seen in 63.2% and 36.8% cases respectively. Temporal horns were prominent in 12 of 19 cases. Involvement of fornix and mammillary body was in 11 (57.9%) and 6 (11.9%) of cases. Absolute values of hippocampus volume were calculated by a mouse driven cursor on T1 weighted sagittal images [Table/Fig-6].

	T1 Volumetry		Ratio (HCVR)
	Right	Left	
Mean	33.28	32.03	0.94
SD	2.91	3.14	0.04

[Table/Fig-4]: Mean, SD of hippocampus volume and ratio of control subjects.

Parameters	NAA	NAA/Cho+Cr	NAA/Cr	NAA/Cho
Mean Value	17.87	0.79	1.67	1.52
Standard Deviation	1.84	0.10	0.26	0.20
Minimum	15.39	0.65	1.37	1.21
Maximum	22.00	0.96	2.11	1.82
Abnormal if:	< 14.19	< 0.59	<1.16	<1.12

[Table/Fig-5]: Reference values for parameters obtained with SVS MR Spectroscopy.

Lateralization on the basis of comparison with mean value of hippocampal volumes and mean HCVR (Hippocampal Volume Ratios) were calculated and we were able to lateralize in 17 of 19 cases by using volumetric data. HCVR was able to lateralize in 14 of 19 cases [Table/Fig-7].

The concentration of NAA is substantially reduced on the ipsilateral side as well as on the contralateral side. However, the concentration of Cr and Cho appeared to be quite within normal range. The concentration of NAA was able to lateralize in 9 of 15 patients. By including both the normally lateralized and bilaterally lateralized groups, NAA was able to lateralize in

Morphology	Number of Patients	Percentage
Total number of patients lateralized	14	73.7%
Hyperintense signal in hippocampus	12	63.2%
Loss of hippocampal architecture	7	36.8%
Involvement of mammillary body	11	57.9%
Involvement of fornix	6	31.6%
Prominence of temporal horn	12	63.2%
Loss of collateral white matter	5	26.3%
Others (Cortical dysplasia etc.,)	1	5.3%

[Table/Fig-6]: Morphology on MR Imaging.

14 of 15 cases. Compared to this NAA/Cr+Cho ratio was able to lateralize in only 13 of the cases with 2 wrong lateralizations [Table/Fig-8].

NAA concentration and NAA/Cr+Cho ratio were reduced in hippocampi with hippocampal sclerosis when compared with control and contralateral sides (at $\alpha = 0.01$). The value of NAA reduction on the contralateral side as compared to normal is also significant (at $\alpha = 0.01$). The value of NAA/Cho and NAA/Cr ratio when compared in Ipsilateral to control subjects was significant, with NAA/Cho performing better. However the p-value of the contralateral to the normal was insignificant [Table/Fig-9].

Bivariate analysis of NAA and Peak ratios by Sigma plot showed that taking any two variables we were able to lateralize

Case No.	MR lateralization	Volumetry		Volumetry lateralization	Ratio	HCVR
		IPS	CL			
1	Left	11.7	21.9	Lat	0.53	Lat
2	R	15.4	28.8	Lat	0.53	Lat
3	N	32.1	35.4	N	0.91	w
4	N	21.7	30.7	Lat	0.71	Lat
5	R	18.6	38.4	Lat	0.48	Lat
6	R	18.4	22.8	Billat	0.81	Lat
7	N	26.2	30.6	Nlat	0.86	Lat
8	L	23.8	24.6	Billat	0.97	w
9	L	27.2	35.6	Nlat	0.76	Lat
10	L	12.4	27.8	Lat	0.45	Lat
11	R	19.4	29	Lat	0.67	Lat
12	N	23	32.2	Nlat	0.71	Lat
13	R	27.6	34	Lat	0.81	Lat
14	R	22.2	35.1	Lat	0.63	Lat
15	L	13.2	34.7	Billat	0.38	Lat
16	R	30	31.7	Lat	0.95	w
17	L	24.2	24.5	Lat	0.99	w
18	N	26.4	27.8	N	0.97	w
19	R	11.6	25.1	Billat	0.46	Lat

[Table/Fig-7]: Volumetry with HCVR and their lateralization in patients.

Category	Volumetry	NAA	NAA/Cho+Cr	NAA/Cr	NAA/Cho
N	2	1	0	1	2
Nlat	3	1	3	4	4
Lat	9	9	8	5	4
Billat	4	4	2	2	2
W	1	0	2	3	3

[Table/Fig-8]: Categorization of TLE patients with different MR spectroscopic parameters.

all patients except one. This was in contrast to the standard deviations method of lateralizing which was sensitive only for NAA.

Variables	NAA	CR	Cho	NAA/CR+Cho	NAA/CR	NAA/Cho
Mean	17.87	10.79	11.86	0.79	1.67	1.52
SD of Normal	1.84	1.09	1	0.1	0.26	0.2
p-value I/C	0.00015	0.3049	0.3311	0.0068	0.0654	0.0106
p-value I/N	3.318-10E8	0.3663	0.0231	0.0001	0.0016	0.0009
p-value C/N	0.0065	0.377	0.11	0.069	0.198	0.482

[Table/Fig-9]: Significance of NAA/CR/Cho with NAA/CR+Cho and NAA/Cho.

DISCUSSION

During this present multi-variate study involving evaluation of morphological, volumetric and spectroscopic data showed 4 of 19 (21%) patients had history of febrile seizures. Similar findings were reported by Lehericy et al., who reported an overall prevalence of 23.4% i.e., 52 of 222 patients to have history of febrile seizures [7]. Ng YT et al., reported 1 of 12 children studied having history of febrile seizures [8]. Janszky et al., reported an overall prevalence of febrile seizures in 59% of cases [9].

Morphology: In our imaging series of TLE patients, hippocampus was hyperintense to gray matter in 63.2% of cases. Prominence of temporal horn was also noted in 63.2% cases. Loss of hippocampal architecture was seen in 36% and involvement of mammillary body in 57.9% of cases. Loss of collateral white matter was seen in 26.3% of cases. A similar frequency of loss of internal architecture of hippocampus was noted by Achten et al., however, they also reported another 16% cases with minimal damage to hippocampal architecture [10]. A higher percentage of changes were described by Ng YT et al., who showed a loss of internal architecture in 75% of cases [8]. Morphologically, hippocampus is isointense to gray matter on all pulse sequences. It may however be hyperintense to gray matter on FLAIR sequences due to incomplete suppression of CSF. There has been a wide variation in the frequency of hippocampal abnormality in literature in the form of signal changes and loss of hippocampal architecture. Lehericy et al., reported T2 hyperintense changes in 53.3%; Achten et al., were able to lateralize in 77% of cases; and Ng YT et al., who found hyperintense signal changes on T2 weighted images in 83.3% of cases, Ercan et al., found hyperintense signal in 85% patients [7,8,10,11].

Other associated lesions in our study like cortical dysplasia and cavum septum Pelucidum accounted for only 10.5% (2) of cases. Others have reported a higher incidence. Ng Y-t et

al., reported such findings in 5 of 12 patients [8].

A total of 14 patients (74%) could be lateralized with morphological analysis alone. This conforms to the fact that visual morphological data is not consistently useful in lateralizing the epileptic focus.

Hippocampal volumetry: Quantitative evaluation of hippocampus was successful in lateralizing 17 of our 19 cases (90%) by keeping the volume two standard deviation below the mean control value viz., 27.48 mm³ on the right and 25.78 mm³ on the left. This is at variance to the 86% found by Cendes et al., and Achten et al., [10,12]. In a study by Lehericy et al., unilateral hippocampal atrophy was present in 63 of 84 patients (75%) of cases. In comparison, 14 of 19 (73.6%) patients could be properly lateralized by HCVR [7]. This lesser sensitivity suggests that it is useful in cases in which asymmetry existed but not useful in cases where a bilateral decreased or normal hippocampal volumes were present.

Spectroscopy: Of the spectroscopic metabolite concentrations, NAA was found to be most useful. By keeping the minimum concentration two standard deviation below the mean control value viz., 14 of 19, we were able to lateralize 9 of 15 patients. However, by including both the normally lateralized and bilaterally lateralized group to the above, NAA was able to lateralize in 14 of 15 cases i.e., in 93.3% of cases. Four of the 15 cases had bilaterally reduced NAA concentration. Compared to this NAA/Cr+Cho ratio is able to lateralize in 13 of our 15 cases i.e., in 86.6% that included 2 cases with bilateral lateralization. There were 2 wrong lateralizations. A similar lateralization was reported by Cendes et al., who were able to lateralize in 83% of cases (25 of 30) with two bitemporal abnormalities [12]. Our findings are discordant with findings by Achten et al., who found NAA/Cho+Cr ratio to lateralize in 13 of 21 cases (62%) and NAA to lateralize in 11 of 21 cases (52.38%). Simister et al., found NAA to be useful but NAA/Cr and NAA/Cho+CR ratios to be unhelpful in localizing abnormality in the TLE group. In our study NAA/Cho and NAA/Cr ratios were discordant in 3 patients each [13]. Both Naa/Cr and Naa/Cho ratios performed less well than NAA and NAA/Cr+Cho with only 11 (73.33%) and 10 (66.66%) patients, respectively being lateralized. Among the two however, NAA/Cr performed better than NAA/Cho in lateralizing the seizure focus. These findings are supported by Ende et al., who also reported a similar number of cases to have discordant lateralization i.e., 3 of 13 cases. Contrary to our study Avecado et al., were able to localize well by using these ratios [13-15].

We found no trend towards an increase or decrease in Cr or Choline concentration. Similar findings have been reported by Ende et al., who did not find any changes in Cr or Cho concentration on both sides [15]. This is at variance with

findings by Achten et al., who reported a trend towards a decrease in Cr concentration in both lobes and an increase in Cho on the ipsilateral side. Simister et al., reported a reduction of Cr and Cho on both sides [13].

Statistical analysis by one tailed 't'-test showed that NAA concentration and NAA/Cr+Cho ratio are reduced in hippocampi with HS when compared with control and contra lateral sides (at $\alpha = 0.01$). The value of NAA reduction on the contra lateral side as compared to normal is also significant (at $\alpha = 0.01$). The value of NAA/Cho and NAA/Cr ratio when compared in Ipsilateral to control subjects is significant, with NAA/Cho performing better. However, the p-value of the contra lateral to the normal is insignificant. The non significance of Cho and Cr (at $\alpha = 0.01$) is also demonstrated. Analyzing further the usefulness of spectroscopy over the morphology, we found 5 patients who were imaging negative to be lateralizing by using the metabolite concentration/ratio. Three of these patients had unilateral lateralization, 1 had bilateral reduction in absolute NAA concentration, and one was normally lateralized. These are similar to what was observed by Connelly et al., [16].

LIMITATION

The major limitations of the study were that histopathological examination of the affected areas of brain was not done to confirm the diagnosis and the sample size of the study was small. Further studies are required to ascertain exact pathogenetic mechanisms of epilepsy.

CONCLUSION

Epilepsy is a wide spread neurological disorder with prevalence of 1.5-5% in any population at some time. Of this, the complex partial seizures account for 40% of cases. The temporal lobe seizures account for a majority of CPS. The loss of CA1 neurons in the hippocampus with hyper synchronization and hyper excitability of surviving neurons result in temporal lobe seizures. MR imaging is the neuroimaging variety of choice for such patients. But even MR imaging cannot lateralize all cases. Better sensitivity has been reported with magnetic resonance spectroscopic but the findings have been found to vary widely. The present study is a step in the direction to lateralize the seizure focus by MR morphology, volumetric and spectroscopy and to determine the sensitivity of each method over the other.

REFERENCES

- [1] Engel J, Williamson PD, Wieser HG. Mesial Temporal Lobe Epilepsy. In: Engel J, Pedley TA, editors. Epilepsy; A comprehensive Textbook. Philadelphia: Lippincot- Raven; 1997: p. 2417-23.
- [2] Definition and Classification of epilepsy. In: Shorvon SD, editor. Handbook of epilepsy Treatment. Oxford: Blackwell Science; 2000.

- [3] Trescher WH, and Lesser RP. The Epilepsies in: Bradely WG, Dradoff RB, Fenichel GM, Marsden CD, editors. *Neurology in Clinical Practice, Principles of Diagnosis and Management*, 3rd edition. Boston : Butterworth Heinmann ;2000: p.1745-80.
- [4] Commission on Classification and Terminology of the International League Against Epilepsy. Proposal for revised clinical and Electroencephalographic classification of epileptic seizure. *Epilepsia*. 1981;22:489-501.
- [5] Commission on Classification and Terminology of the International League Against Epilepsy Proposal for revised classification of epilepsies and epileptic syndrome. *Epilepsia*. 1985;26(3):268-78.
- [6] Commission on Classification and Terminology of the International League Against Epilepsy Proposal for revised classification of epilepsies and epileptic syndrome. *Epilepsia*. 1989;30(4):389-99.
- [7] Lehericy S, Semah F, Hasboun D, Dormont D, Clémenceau S, Granat O, et al. Temporal lobe epilepsy with varying severity: MRI study of 222 patients. *Neuroradiology*. 1997;39(11):788-96.
- [8] Ng YT, McGregor AL, Wheless JW. Magnetic resonance imaging detection of mesial temporal sclerosis in children. *Pediatr Neurol*. 2004;30(2):81-85.
- [9] Janszky J, Schulz R, Janszky I, Ebner A. Medial temporal lobe epilepsy: gender differences. *Journal of Neurol Neurosurg Psychiatry*. 2004;75:773-75.
- [10] Achten E, Boon P, De Poorter J, Calliauw L, Van de Kerckhove T, De Reuck J, et al. An MR protocol for presurgical evaluation of patients with complex partial seizures of temporal lobe origin. *AJNR Am J Neuroradiol*. 1995;16(6):1201-13.
- [11] Ercan K, Gunbey HP, Bilir E, Zan E, Arslan H. Comparative lateralizing ability of multimodality MRI in temporal lobe epilepsy. *Dis Markers*. 2016;2016:5923243. Epub 2016 Nov 15.
- [12] Cendes F, Andermann F, Dubeau F, Arnold DL. Proton magnetic resonance spectroscopic images and MRI volumetric studies for lateralization of Temporal Lobe Epilepsy. *Magn Reson Imaging*. 1995;13(8):1187-91.
- [13] Simister RJ, Woermann FG, McLean MA, Bartlett PA, Barker GJ, Duncan JS. A short echo time proton magnetic resonance spectroscopic imaging study of temporal lobe epilepsy. *Epilepsia*. 2002;43(9):1021-31.
- [14] Lopez-Acevedo ML, Martinez-Lopez M, Favila R, Roldan-Valadez E. Secondary MRI-findings, volumetric and spectroscopic measurements in mesial temporal sclerosis. *Swiss Med Wkly*. 2012;142:w13549.
- [15] Ende GR, Laxer KD, Knowlton RC, Matson GB, Schuff N, Fein G, et al. Temporal lobe epilepsy: bilateral hippocampal metabolite changes revealed at proton MR spectroscopic imaging. *Radiology*. 1997;202(3):809-17.
- [16] Connelly A, Paesschen WV, Porter DA. Proton magnetic resonance spectroscopy in MRI-negative temporal lobe epilepsy. *Neurology*. 1998;51:61-66.

AUTHOR(S):

1. Dr. Siddharth Prakash
2. Dr. Vikram Narang
3. Dr. Ranjan Kukreti
4. Dr. Deepak Goel

PARTICULARS OF CONTRIBUTORS:

1. Assistant Professor, Department of Radiology, DMCH, Ludhiana, Punjab, India.
2. Assistant Professor, Department of Pathology, DMCH, Ludhiana, Punjab, India.
3. Professor, Department of Radiology, HIMS Dehradun, Uttranchal, India.

4. Professor, Department of Medicine, HIMS, Dehradun, Uttranchal, India.

NAME, ADDRESS, E-MAIL ID OF THE CORRESPONDING AUTHOR:

Dr. Vikram Narang,
Assistant Professor, Department of Pathology,
Dyanand Medical College and Hospital,
Ludhiana-141001, Punjab, India.
E-mail: drvikramnarang@yahoo.com

FINANCIAL OR OTHER COMPETING INTERESTS:

None.

Date of Publishing: Oct 01, 2017