

# Pancreatic Divisum – A Silent Anomaly with Clinical Essence

SIVAKAMI R PRADHEEP KUMAR, D. KARTHIKEYAN

**Keywords:** Accessory duct of Santorini, Recurrent pancreatitis, Ventral duct of Wirsung

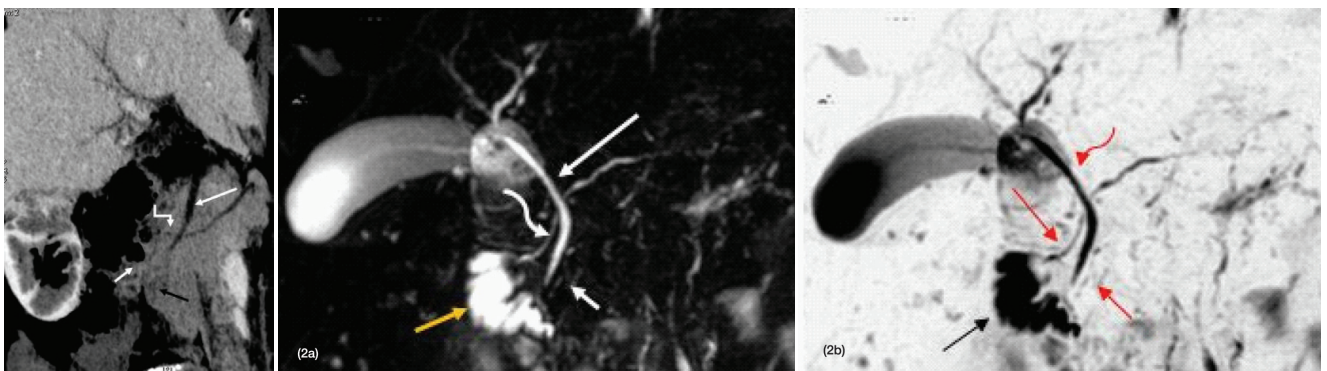
A 33-year-old male patient presented with complaints of recurrent and chronic abdominal pain for past two years. On examination mild epigastric tenderness was present. Lab test showed mildly raised serum amylase and lipase levels. Patient was referred for abdominal sonography to rule out pancreatic pathology. However, sonography turned out to be normal study. Then patient was referred for CECT abdomen.

CECT abdomen study was done using 128 slice GE machine and the study revealed prominent dorsal pancreatic duct emptying separately via the minor papilla and small ventral pancreatic duct emptying via major papilla into duodenum after joining the CBD [Table/Fig-1]. MRCP image of patient confirmed the findings on CECT Abdomen [Table/Fig-2a,b]. The diagnosis made was a variant of pancreatic duct anatomy, pancreatic divisum type I. No differential diagnosis was considered as the abnormality was obviously demonstrable with no confusing or overlapping findings. Patient's informed consent was acquired for publication purposes in future.

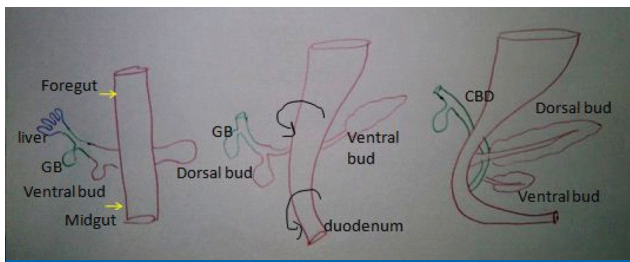
Pancreas development starts at five weeks of gestation when two endodermal outpouchings, namely ventral and dorsal form from the duodenum. Dorsal bud grows faster than

the ventral bud. Ventral bud moves dorsally as duodenum rotates to right side. Ventral bud forms the uncinete process and inferior part of the pancreatic head. Superior part of the head, body and tail of pancreas form from dorsal bud [Table/Fig-3]. Ventral part of the pancreas drained by the small ventral duct of Wirsung which joins the main pancreatic duct, the segment of the dorsal pancreatic duct proximal to the fusion of dorsal-ventral duct at the level of pancreatic neck. The main pancreatic duct is the main drainage pathway of pancreas and drains in to the major papilla at the ampulla of Vater after joining common bile duct. In few individuals the accessory pancreatic duct of Santorini is present, which is the segment of the dorsal pancreatic duct distal to the fusion of dorsal and ventral pancreatic ducts. Antero-superior part of the pancreatic head is drained by this duct. Commonly (70%) the minor papilla drains this duct and less commonly (30%) it remains as the main pancreatic duct branch [Table/Fig-4a,b].

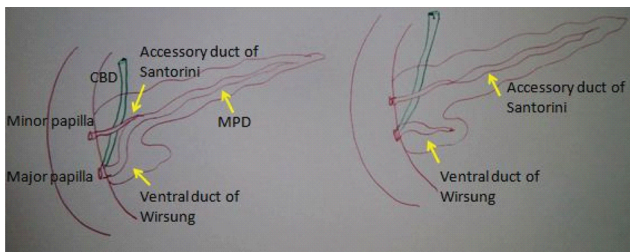
Most common congenital anomaly of the pancreatic ductal system with incidence of 4%–10% is pancreas divisum which results due to failure of fusion of dorsal and ventral pancreatic ducts. In this anomaly the ventral duct (duct of Wirsung)



**[Table/Fig-1]:** Curved reformatted image of Multislice contrast CT abdomen of the patient showing prominent dorsal duct (bent arrow) emptying via minor papilla and small ventral duct (black arrow) emptying in to major papilla in second part of the duodenum (short white arrow) after joining the CBD (long white arrow). **[Table/Fig-2a-b]:** (a) MRCP image of the patient showing prominent dorsal duct (curved arrow) emptying via minor papilla and small ventral duct (short white arrow) in to major papilla in second part of the duodenum (yellow arrow) after joining the CBD (long white arrow); (b) Inverted MRCP image of the patient showing prominent dorsal duct (long arrow) emptying via minor papilla and small ventral duct (short arrow) in to major papilla in second part of the duodenum (black arrow) joining the CBD (curved arrow).



**[Table/Fig-3]:** Schematic diagram showing embryology of pancreas.



**[Table/Fig-4a-b]:** (a) Schematic diagram showing normal ductal anatomy of pancreas, (b) Schematic diagram of pancreatic divisum showing prominent dorsal duct (yellow arrow) emptying via minor papilla and small ventral duct (yellow arrow) emptying into major papilla joining the CBD.

drains only the ventral pancreatic anlage via major papilla and the majority of the gland is drained by the dorsal duct (duct of Santorini) [1] emptying into the minor papilla. This entity is usually asymptomatic but it is commonly found in patients with recurrent and chronic abdominal pain and pancreatitis of unknown etiology than the normal population. Associated stenosis of the minor papilla is proposed to be the etiology in these patients [2]. There are three subtypes in pancreatic divisum. Type 1 is the classic and commonest (70%) one in which there is no connection between the ventral and the dorsal pancreatic duct. Type 2 (20- 25%) is less common one, where the ventral duct is absent with the minor papilla draining all of pancreas through dorsal duct while major papilla drains bile duct. Type 3 (5-6%) is functional and the least common type in which an incomplete communication is present between the dorsal and ventral pancreatic duct.

The gold standard investigation for diagnosing pancreatic divisum is Endoscopic Retrograde Pancreatography (ERCP) [3]. When pancreatic duct is dilated multislice CT will also easily demonstrate the anomaly [4]. In recent times MR Cholangiopancreatography (MRCP) is found to be an alternative to the invasive ERCP in diagnosing pancreatic divisum. Secretin, the drug which stimulates pancreatic secretions can be used to accentuate the visualisation of pancreatic ducts. The ventral duct is smaller and dorsal duct is larger in these patients. Few of the patients also show

santorinicele i.e., focal cystic dilatation of the dorsal duct near minor ampulla. The advantage of MRCP over ERCP is that the MRCP is non invasive procedure. In ERCP if only the major papilla is cannulated, only the dorsal duct could be seen unless there is common drainage of the ventral and dorsal ducts, however in MRCP both ventral and dorsal ducts can be visualised regardless of the common or separate drainage of those ducts. Extra ductal pathologies i.e., pancreatic, biliary and ampullary pathologies can also be evaluated with MRCP.

As this congenital anomaly is commonly silent, only for patients who are symptomatic are treated, after ruling out other causes for chronic abdominal pain and recurrent pancreatic inflammation. Medical management is given for patients with mild and early symptoms. Endoscopic or surgical intervention is suggested for patients who present with recurrent pancreatitis and chronic abdominal pain to relieve the associated papillary stenosis. Minor papillotomy, stenting, and dilatation of minor papilla with balloon are the endoscopic interventions. Verification of the pancreatic divisum diagnosis with ERCP is required in all the patients taken for surgical intervention. Sphincterotomy and sphincteroplasty of the minor papilla are available surgical procedures [5].

Our patient presented with chronic upper abdominal pain. Other causes for the symptom like cholelithiasis, gastritis and renal causes were ruled out. Patient was started with symptomatic medical treatment, however patient was not responding. Hence, patient was suggested endoscopic minor papillotomy. Congenital anomalies of pancreas are commonly encountered on day to day imaging work, commonest of them being the pancreatic divisum. This anomaly contributes to the pathogenesis of few common pancreatic and biliary diseases. It is necessary for both the clinicians and radiologist to be familiar with this anomaly to suspect, diagnose and treat the clinical problems of the patient and to avoid diagnostic errors.

## REFERENCES

- [1] Taylor AJ, Morteale K. Congenital disorders of the bile and pancreatic ducts [abstr]. In: Abdominal Radiology Course annual meeting program. San Antonio, Tex. 2005:224-26.
- [2] Mortelé K, Wiesner W, Zou K, Ros P, Silverman S. Asymptomatic nonspecific serum hyperamylasemia and hyperlipasemia: spectrum of MRCP findings and clinical implications. *Abdominal Imaging*. 2003;29:109.
- [3] Morgan D, Logan K, Baron T, Koehler R, Smith J. Pancreas divisum: implications for diagnostic and therapeutic pancreatography. *AJR Am J Roentgenol*. 1999;173(1):193-98.
- [4] Soto JA, Lucey BC, Stuhlfaut JW. Pancreas divisum: depiction with multi-detector row CT. *Radiology*. 2005;235(2):503-08. Epub 2005 Mar 15.
- [5] Schneider L, Müller E, Hinz U, Grenacher L, Büchler MW, Werner J. Pancreas divisum: a differentiated surgical approach in symptomatic patients. *World J Surg*. 2011;35(6):1360-66.

**AUTHOR(S):**

1. Dr. Sivakami R Pradheep Kumar
2. Dr. D. Karthikeyan

**PARTICULARS OF CONTRIBUTORS:**

1. Assistant Professor, Department of Radio Diagnosis, Sri Manakulavinayagar Medical College and Hospital, Kalitheerthal Kuppam, Madagadipet, Pondicherry, India.
2. Senior Consultant and HOD, Department of Radio Diagnosis, SRM Institute for Medical Science and Imaging, Jawaharlal Nehru Salai, Vadapalani, Tamil Nadu, India.

**NAME, ADDRESS, E-MAIL ID OF THE CORRESPONDING AUTHOR:**

Dr. Sivakami R Pradheep Kumar,  
Door no – 80, Boopalam Street, Vallalar Nagar, Villupuram,  
Villupuram District, Tamil Nadu, Pin Code-605602, India.  
E-mail: sivakamijj@yahoo.co.in

**FINANCIAL OR OTHER COMPETING INTERESTS:**

None.

Date of Publishing: Jan 01, 2017