

Surgical Management of Choledochal Cysts in Children- Our Experience in a District Level Teaching Hospital

ANIL BALRAJ THATIPAMULA, JAGANMOHAN MOKA

ABSTRACT

Introduction: Choledochal cyst is a rare congenital dilatation of the bile ducts. It occurs frequently in females. Its incidence is more in Asian population particularly in Japan.

Aim: To study the clinical presentation, diagnosis, management and results of 10 patients of choledochal cyst treated in a district level teaching hospital.

Materials and Methods: It is a retrospective study about the clinical presentation, management and results of treatment of 10 cases of choledochal cysts managed over 7 years during April 2009 to March 2016. Medical records of the children admitted with choledochal cysts during the study period in MGM Hospital Warangal, India were studied.

Results: The age of the patients ranged from 25 days-12 years. Two patients were 1 year or less in age (infantile group) and 8 patients were more than 1 year old (classical pediatric group). Children less than 1 year presented with

jaundice (n=2), hepatomegaly (n=2) and clay colored stools (n=2) whereas, those above 1 year presented with pain (n=8) jaundice (n=2) and palpable mass in right hypochondrium (n=2). Ultrasonography diagnosed/suggested choledochal cyst in all cases, however, CT-scan (n=5) and MRCP (n=5) also contributed to the diagnosis. Nine patients had type I choledochal cyst and 1 patient had type IV variety having intrahepatic and extrahepatic dilatation. Operative management included primary total excision of cyst and Roux-en-Y hepaticojejunostomy (n=7), Lilly's modification of submucosal resection with hepaticojejunostomy (n=2) and total cyst excision with hepaticoduodenostomy (n=1). Two patients had wound infection which needed secondary suturing. There was one post operative death due to burst abdomen and sepsis.

Conclusion: Choledochal cyst should be ruled out while evaluating neonates and infants with obstructive jaundice and older children with recurrent abdominal pain. Primary excision of the cyst with hepaticojejunostomy provides satisfactory results in infants and children.

Keywords: Hepaticoduodenostomy, Hepaticojejunostomy, Jaundice

INTRODUCTION

Choledochal cyst is cystic dilatation of extrahepatic and/or intrahepatic biliary tree, which may be a cause of obstructive jaundice and diagnosed mainly in the pediatric age group [1]. Alonso-Lej et al., in 1959 classified choledochal cysts into 3 types i.e., from type I-III initially [2], later in 1977 Todani et al., modified it by adding type IV and V. He classified choledochal cysts into Type-I make upto 50%-80%, Type-II is 2%, Type-III is 1.4%-4.5%, Type-IV is 15%-35% and Type-V 20% [3]. Choledochal cyst was first described by Vater in 1723, but, the first clinical description was given by Douglas in 1852 which was due to dilatation of the common bile duct and congenital in origin [4]. Its incidence is one in 100-150,000 live births in Western population, high in Asia particularly in Japan [5]. Infants with choledochal cyst can present with jaundice,

acholic stools and palpable mass in right upper quadrant of the abdomen with hepatomegaly where as older children present with jaundice, palpable right upper quadrant mass, associated pancreatitis with elevated amylase and lipase levels and cholangitis [6]. The pathological features include intra hepatic duct dilatation, distal common bile duct stenosis, an anomalous junction of the pancreatic and common bile duct and abnormal hepatic histology [7]. They can cause recurrent cholangitis, pancreatitis, sepsis, liver abscesses and cholangiocarcinoma if not treated when diagnosed. This study focused on clinical presentation, diagnosis, management and outcome in 10 cases of choledochal cyst managed at our institution over a period of 7 years. During last decade, with the advent of much improved laparoscopic techniques with minimal dissection and short stay in hospital lead many surgeons to apply them in children. Many groups

have successfully performed laparoscopy and laparoscopic assisted total excision of the cyst and hepaticojejunostomy with equally good results compared to open surgery.

MATERIALS AND METHODS

This retrospective study was conducted in the Department of Pediatric Surgery, MGM Hospital, Kakatiya Medical College, Warangal, India. The medical records of patients admitted for the treatment of choledochal cyst between April 2009 and March 2016 were reviewed. Ten patients diagnosed as choledochal cyst were included in our study. Patients with associated biliary atresia, pancreatitis were excluded.

All the patients were subjected to radiological investigations like Ultrasonography (USG), CT- scan in 5 patients and MRCP in 5 patients. Liver function tests were done to confirm jaundice in all the cases. MRCP is the best non invasive radiological investigation of choice in better delineation of pancreatobiliary system and pathology.

All 10 patients underwent surgery. Preoperative preparation/stabilization of all patients was undertaken in relation to correction of anemia, electrolyte imbalance and correction for dehydration. Coagulation profile was done in all patients before surgery which was important to secure the hemostasis during surgery. Surgical exploration was done by right sub costal incision in all patients. Intra op was uneventful.

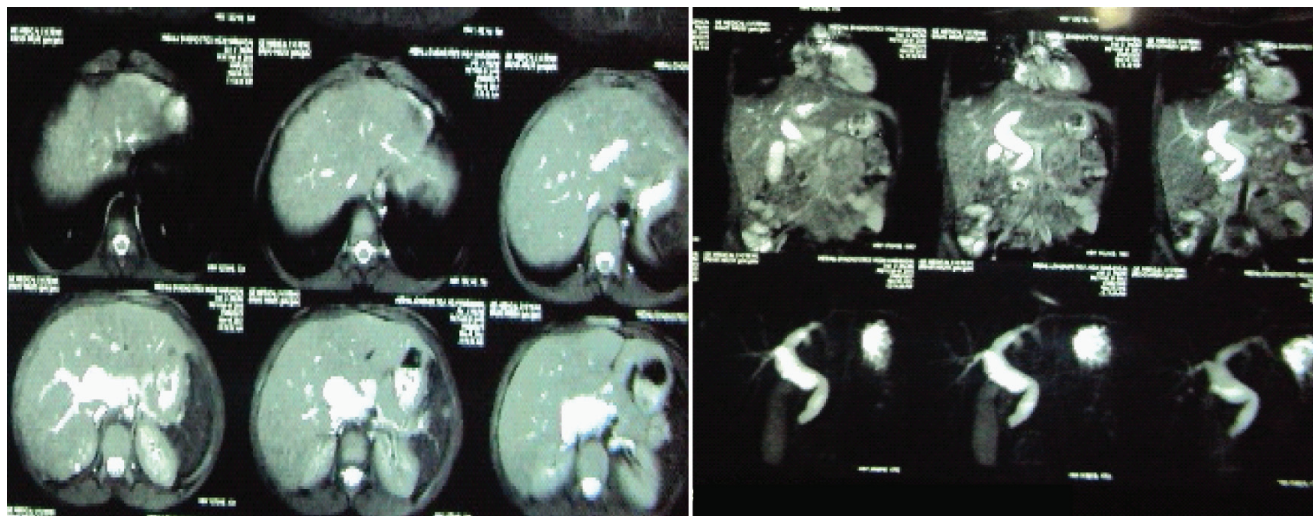
RESULTS

The age of the patients was in between 25 days to 10 years with the youngest age of 25 days and oldest was 10 years old. 50% of the patients were in the age group of 6 years to 10 years with female:male ratio of 3:2. The presenting signs and symptoms in all the 10 patients were as follows: 8 out of 10 patients presented with upper abdominal pain which was localized in right hypochondrium. Two patients out of 10

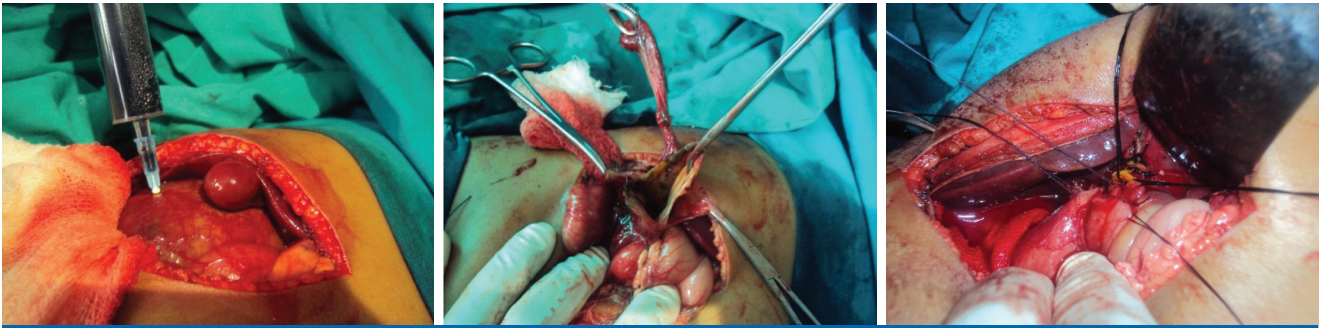
presented with lump in right hypochondrium, 2 patients with jaundice and 2 patients with hepatomegaly with pain in right hypochondrium respectively. Two out of 10 patients showed the classical triad of pain, abdominal lump and jaundice.

An abdominal USG suggested choledochal cyst in all patients. CT-scan was performed in 5 patients to sub categorize the type of choledochal cyst as USG showed moderate to severe dilatation of intra hepatic biliary radicles. MRCP was performed in 5 patients [Table/Fig-1] which showed fusiform dilatation of common bile duct with mild dilatation of right and left hepatic ducts.

All patients underwent routine hematological investigations including liver function tests and coagulation profile preoperatively. Thorough bowel preparation and vitamin 'K' injection was administered the day before surgery. All the cases were operated and cholecystectomy with total excision of the cyst was performed. Choledochal cyst was well dissected away from surrounding structures and the lower end was sutured near the tapering end and the cyst was excised [Table/Fig-2]. Proximally the cyst was excised at the level of common hepatic duct. In one case, there was blockage of the hepatic duct above the choledochal cyst, which on further dissection, we found confluence of right and left hepatic ducts which were anastomosed to jejunum. In another case, there was excessive bleeding near the porta hepatis due to anomalous hepatic artery which was controlled by proper ligation and Abgel was placed to stop oozing. In 2 cases, Lilly's procedure [Table/Fig-3] was performed due to thickened cyst wall and adhesions to the surrounding structure which might be due to intermittent attacks of cholangitis. In one patient hepaticoduodenostomy [Table/Fig-4] was performed because of wide hepatic duct and duodenum was in close vicinity, where the mobilization of duodenum was possible without



[Table/Fig-1]: MRCP images showing fusiform dilatation of entire common bile duct and common hepatic duct measuring 18 mm with mild intra hepatic dilatation of the ducts mainly left one 5mm.



[Table/Fig-2]: Showing cyst intra operatively as a huge cystic swelling below the gall bladder. **[Table/Fig-3]:** Showing Lilly's procedure showing stripping of mucosa of cyst which is cut open. **[Table/Fig-4]:** Showing hepaticoduodenostomy being done during surgery.

much difficulty. In rest of 7 patients, total excision of the cyst and Roux-en-Y hepaticojejunostomy was performed.

Post operative complications included minor wound infection in 2 patients. One patient required secondary suturing.

All patients were followed up for 1 year regularly after discharge. Five patients had occasional abdominal pain and got relieved by analgesics. Abdominal USG on follow-up did not show any abnormality. Liver function tests were normal in all patients. Further follow-ups were lost despite of our instructions at the time of discharge. However, there was one death in our study, one patient who had type-IV anomaly with significant intrahepatic ductal dilatation which led to post operative leak, burst abdomen and later sepsis.

DISCUSSION

In children, choledochal cysts are rarely reported. The incidence is higher in Asian population with incidence of 1:1,000 of which about two third cases reported from Japan [8]. The incidence of jaundice, vomiting, hepatomegaly and acholic stools is high in neonates and infants which resembles correctable biliary atresia [5]. In this study, there are 2 patients in this group having significant jaundice and intrahepatic ductal dilatation [9].

Ultrasound examination studies using high resolution is the best investigation for diagnosing the choledochal cysts in children and was performed in all our cases [10,11]. In addition to ultrasound, five patients were subjected to CT-scan to confirm the diagnosis [12]. MRCP has been advocated as the ideal and non-invasive diagnostic test for accurate visualization of the entire pancreatobiliary tree [13]. It eliminates the necessity of subjecting towards intraoperative cholangiography. The same was performed in 5 of our patients where the anatomy of the biliary tree was clear in diagnosing the choledochal cysts. It helps in the management, as well as planning of surgical procedure.

We also observed that Type-I choledochal cyst was the most common type (80%) and type-IV was seen in 20% as per Todani's classification [Table/Fig-5] [3].

Type	Todani Group	This Study
Type I	50-80%	80%
Type II	2%	--
Type III	1.4-4.5%	--
Type IV	15-35%	20%
Type V	20%	

[Table/Fig-5]: Incidence of different types.

Sarin YK et al., and Narasimhan KL et al., reported that there was an incidence of anomalous hepatic artery and accessory hepatic duct along with choledochal cyst [14,15]. In this study, we also found 2 patients with similar anomaly which needed careful dissection during surgery.

Complete excision of the choledochal cyst should be done in all cases as there is high risk of carcinoma developing from the cyst wall [3]. If complete excision of choledochal cysts is difficult in some cases where adhesions are present or wall is thickened due to cholangitis, Lilly's procedure with mucosal removal is recommended. We observed the same and performed this procedure in 2 patients of this study. Most surgeons advocated total excision with hepaticojejunostomy is the procedure of choice [5,9]. We also performed the same in 7 out of 10 patients in this study. In one patient, we performed hepaticoduodenostomy as the duodenum was easily mobilized due to huge choledochal cyst mass [16]. Laparoscopic surgery is also performed by some experienced surgeons. They performed complete excision of the choledochal cyst with hepaticocenterostomy. They felt, this technique provides clear visualization of structures surrounding the cyst and hepatic hilum with minimal loss of blood, less hospital stay, less postoperative nosocomial infection and excellent wound healing [17].

This study suggests that MRCP is the best investigation to confirm the diagnosis and management of choledochal cyst. The complete excision of the cyst and hepatico jejunostomy is the best treatment as proved by the various studies in the literature.

LIMITATIONS

This study might have been extended as this was conducted in district level teaching hospital with few facilities. It was not feasible to take high risk cases as well equipped PICU and SICU were not available. Due to lack of facilities, we could not take up laparoscopic procedures in our patients.

CONCLUSION

In infants with cholestatic jaundice and older children with intermittent abdominal pain in right hypochondrium should be evaluated for choledochal cysts. Ultrasonography of the abdomen is a basic radiological investigation for evaluation of a patient of choledochal cyst and for obtaining more anatomical details MRCP is preferred over CT-scan of abdomen.

REFERENCES

- [1] Bhavsar MS, Vora HB, Giriappa VH. Choledochal cysts: A review of literature. *Saudi J Gastroenterol.* 2012;18(4):230-36.
- [2] Alonso-Lej F, Rever WB, Pessagno DJ, Congenital choledochal cyst with a report of two and analysis of 94 cases. *Abstr Surg.* 1959;108:01-30.
- [3] Todani T, Watanab Y, Narusue, Tabuchi K, Okajima K. Classification, operative procedure and reviews of 37 cases including cancer from choledochal cysts. *Am J Surg.* 1977;134: 263-69.
- [4] Poddar U, Thapa BR, Chhabra M, Rao KL, Mitra SK, Dilawari JB, et al. Choledochal cysts in infants and children. *Indian Pediatr.* 1998;35(7):613-18.
- [5] Miyano T, Yamataka A, Li L. Congenital biliary dilatation. *Semin Pediatr Surg.* 2000;9(4):187-95.
- [6] Sawyer Michael AJ. Choledochal cysts treatment & management. 2016;Feb10. <http://emedicine.medscape.com/article/172099-treatment>.
- [7] Stringer MD, Dhawan A, Davenport M, Mieli-Vergani G, Mowat AP, Howard ER. Choledochal cyst: lessons from a 20 years experience. *Arch Dis Child.* 1995 ;73(6):528-31.
- [8] Mishra A, Pant N, Chadha R, Choudhury SR. Choledochal cysts in infancy and childhood. *Indian J Pediatr.* 2007;74(10):937-43.
- [9] Joseph VT. Surgical techniques and long term results in the treatment of choledochal cyst. *J Pediatr Surg.* 1990;25(7):782-87.
- [10] Mukhopadhyay B, Roy J, Bommayya N, Mukhopadhyay M, Deb P, Chatterjee TK, et al. Choledochal cyst-experience in five years. *Journal Indian Assoc Pediatr Surg.* 1999;4(3): 118-22.
- [11] Le L, Pham AV, Dessanti A. Congenital dilatation of extrahepatic bile ducts in children. Experience in the central hospital of Hue, Vietnam. *Eur J Pediatr Surg.* 2006;16:24-27.
- [12] O'Neill JA Jr. Choledochal cyst. *Curr Probl Surg.* 1992;29(6):361-410.
- [13] Suzuki M, Shimizu T, Kudo T, Suzuki R, Ohtsuka Y, Yamashiro Y, et al. Usefulness of non-breathhold 1-shot magnetic resonance cholangiopancreatography for the evaluation of choledochal cyst in children. *J Pediatr Gastroenterol Nutr.* 2006;42:539-44.
- [14] Sarin YK. Biliary ductal and vascular anomalies associated with choledochal cyst. *J Indian Ass Pediatric Surgeons.* 2005;10:86-88.
- [15] Narasimhan KL, Chaudhury SK, Ral KLN. Management of accessory hepatic ducts in choledochal cysts. *J Pediatr Surg.* 2001;7:1092-93.
- [16] Todani T, Watanabe Y, Mizuguchi T et al. Hepaticoduodenostomy at the hepatic hilum after excision of choledochal cyst. *Am J Surg.* 1981;142:584-87.
- [17] Ruiz C Hierro. Laparoscopic repair of choledochal cyst in children: current status. *World Journal of Laparoscopic Surgery.* 2012;5(2):76-79.

AUTHOR(S):

1. Dr. Anil Balraj Thatipamula
2. Dr. Jaganmohan Moka

PARTICULARS OF CONTRIBUTORS:

1. Assistant Professor, Department of Paediatric Surgery, Kakatiya Medical College, MGM Hospital, Warangal, Telangana, India.
2. Associate Professor, Department of Paediatric Surgery, Gandhi Medical College, Secunderabad, Telangana, India.

NAME, ADDRESS, E-MAIL ID OF THE CORRESPONDING AUTHOR:

Dr. Anil Balraj Thatipamula,
#2-4-164, Haritowers, Ramnagar, Hanamkonda,
Warangal-506001, Telangana, India.
E-mail: aniltatipamula30@gmail.com

FINANCIAL OR OTHER COMPETING INTERESTS:

None.

Date of Publishing: Oct 01, 2016