

# Bilobed Gall Bladder: A Rare Hepatobiliary Anomaly

MANJYOT BAJWA, ANUJ MAHAJAN, RAVINDER PAL SINGH, JASPAL SINGH, CHIRANJIV SINGH GILL

## ABSTRACT

Gallbladder duplication is a rare anomaly and bilobed gall bladder is an extremely rare entity. Duplicate gallbladder is an congenital defect, results from abnormal embryogenesis during the fifth and sixth weeks of gestation. Diagnosis of such a patient may be difficult pre-operatively.

Identification of such anomalies can avoid biliary injuries and other complications during laparoscopic procedures being done on the gall bladder. We present a case of bilobed gall bladder that was diagnosed and managed intra-operatively.

**Keywords:** Acute cholecystitis, Adhesions, Laparoscopic cholecystectomy

## CASE REPORT

A 58-years old male presented in the Department of General Surgery with chief complaint of pain in right upper quadrant since 3 days. The pain was sudden in onset, moderate and colicky in nature. Abdominal examination revealed a soft abdomen with tenderness on deep palpation in right hypochondrium. Differential diagnosis of acute cholecystitis or peptic ulcer disease was kept.

After obtaining consent the patient was investigated.

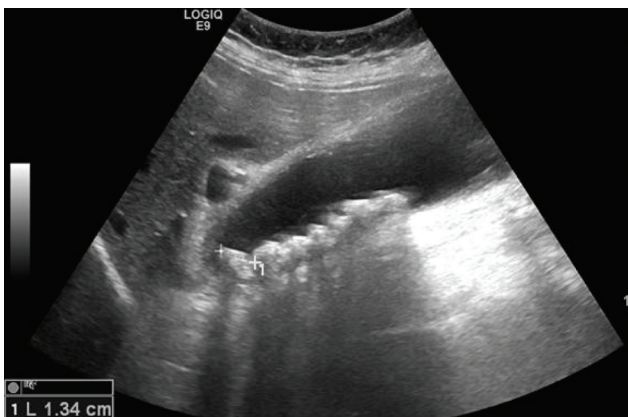
Laboratory investigation revealed baseline values of hematology, biochemistry and LFTs were within normal limits. Ultrasound abdomen showed an overdistended gallbladder with multiple intraluminal gallstones [Table/Fig-1].

Provisional diagnosis of acute or chronic calculous cholecystitis was made and the patient was prepared for laparoscopic

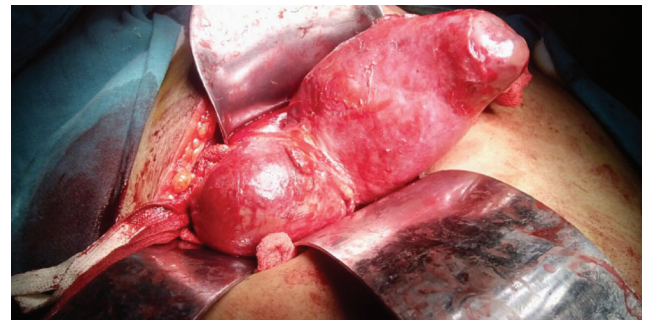
cholecystectomy.

Intraoperatively, in view of extensive adhesions, laparoscopic procedure was abandoned and the procedure was converted to open cholecystectomy. Patient was explored by right subcostal [Kocker's] incision, dense adhesions were found over gallbladder and Calot's triangle which were freed by careful dissection.

Fundus of gallbladder was traced to its body and surprisingly, another lobe of gallbladder was found lying over the common bile duct [Table/Fig-2]. Both lobes of gallbladder were freed of adhesions and found to open in a single infundibulum leading



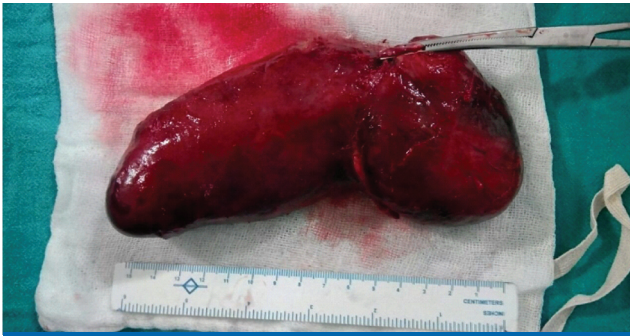[Table/Fig-1]: Ultrasound abdomen showing multiple gallstones.



[Table/Fig-2]: Intraoperative view of bilobed gall bladder.

to a single cystic duct which was ligated and incised followed by ligation and incision of cystic artery. Gallbladder was freed from liver bed with complete hemostasis [Table/Fig-3].

Post op patient was managed with routine antibiotics as per the hospital policy. Patient was started with oral diet once he started passing flatus. He was discharged on post operative day 4 in stable condition.






[Table/Fig-3]: View of the gall bladder after removal from the body.

On follow-up, post surgery the patient was asymptomatic with no active complaints.

## DISCUSSION

Bifurcation of the gallbladder primordium during the sixth embryonic week is called as duplication. Duplicated gall bladder was classified by Boyden [Table/Fig-4][1]. Two separate fundus that have a common base and are drained by a single cystic duct are characteristic.

Vesica fellea divisa	Vesica fellea duplex	
	Y-shaped type	H-shaped type
		

[Table/Fig-4]: Boyden classification [1].

The out pouching that develops from the normal extra hepatic biliary system during the fifth and sixth weeks of gestation is responsible for duplication. These outpouching typically regress; however, their persistence results in formation of an accessory gallbladder.

Simultaneous removal of both the lobes is recommended to avoid cholecystitis and symptomatic gallstones in the remaining organ [2,3]

Several publications have reported a successful laparoscopic procedure for this entity [4]. However, surgery in an asymptomatic patient is not indicated [2]. Ultrasound is generally the first choice of imaging modality in patients with suspected biliary disease. It may diagnose gallbladder duplication if the viscera are located separately but it is not uncommon for ultrasound to miss the disease [5]. Other anatomical anomalies of the biliovascular structures may also be present in such patients. These may be a reason for intraoperative injuries. Thus, complete evaluation of the biliary anatomy must be done intra-operatively.

## CONCLUSION

Duplication of the gallbladder is a rare congenital abnormality. Most of the times symptomatic cases are treated laparoscopically. However, in view of high chances of anomalous bilio-vascular anatomy the threshold of conversion to an open procedure should always be low.

## REFERENCES

- [1] Boyden EA. The accessory gallbladder: an embryological and comparative study of aberrant biliary vesicles occurring in man and the domestic mammals. *American Journal of Anatomy*. 1926; 38:177-23.
- [2] Gigot J, Van Beers B, Goncette L, Etienne J, Collard A, Jadoul P et al. Laparoscopic treatment of gallbladder duplication: a plea for removal of both gallbladders. *Surgical Endoscopy*. 1997; (11)5:479-82.
- [3] Horattas MC. Gallbladder duplication and laparoscopic management. *J Laparoendosc Adv Surg Tech A*. 1998;8(4):231-35.
- [4] Borghi F, Giraudo G, Geretto P, Ghezzi L. Perforation of missed double gallbladder after primary laparoscopic cholecystectomy: endoscopic and laparoscopic management. *J Laparoendosc Adv Surg Tech A*. 2008;18(3):429-31.
- [5] McDonald KL, Lwin T. Sonographic and scintigraphic evaluation of gallbladder duplication. *Clin Nucl Med*. 1986;11(10):692-93.

### AUTHOR(S):

1. Dr. Manjyot Bajwa
2. Dr. Anuj Mahajan
3. Dr. Ravinder Pal Singh
4. Dr. Jaspal Singh
5. Dr. Chiranjiv Singh Gill

### PARTICULARS OF CONTRIBUTORS:

1. Resident, Department of Surgery, Dayanand Medical College, Ludhiana, Punjab, India.
2. Resident, Department of Surgery, Dayanand Medical College, Ludhiana, Punjab, India.
3. Associate Professor, Department of Surgery, Dayanand Medical College, Ludhiana, Punjab, India.

4. Professor and Head, Department of Surgery, Dayanand Medical College, Ludhiana, Punjab, India.
5. Professor, Department of Surgery, Dayanand Medical College, Ludhiana, Punjab, India.

### NAME, ADDRESS, E-MAIL ID OF THE CORRESPONDING AUTHOR:

Dr. Anuj Mahajan,  
Mahajan Nursing Home, Dhangu Road,  
Pathankot, 145001, Punjab, India.  
E-mail: anuj0mahajan@yahoo.co.in

### FINANCIAL OR OTHER COMPETING INTERESTS:

None.

Date of Online Ahead of Print: Aug 16, 2016

Date of Publishing: Oct 01, 2016