

# Sonographic Detection of Traumatic Intraperitoneal Bladder Rupture: A Case Report

DONBOKLANG LYNSEER, EVARISALIN MARBANIANG

## ABSTRACT

Urinary bladder rupture is associated with high morbidity and mortality. Early diagnosis and repair is the treatment of choice. Diagnosis is usually done by conventional X-ray or computed tomography (CT) cystography. We present a

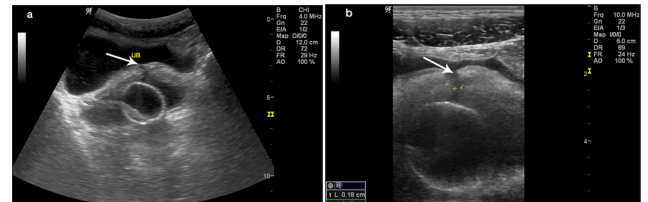
post-traumatic intraperitoneal bladder dome rupture which was diagnosed exclusively using ultrasound and then confirmed on fluoroscopic cystography and finally at laparotomy. Ultrasound imaging therefore, in an appropriate emergency clinical setting can diagnose urinary bladder rupture.

**Keywords:** Cystography, Computed tomography, Ultrasound

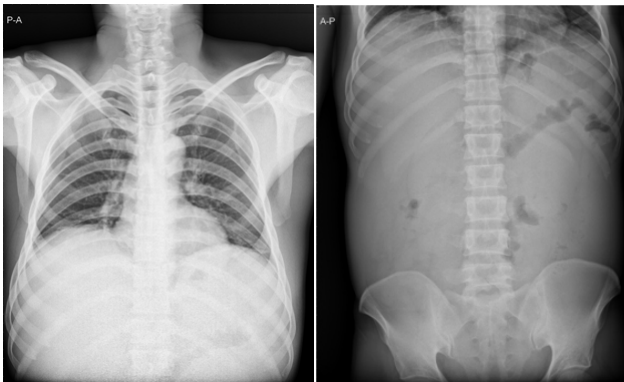
## CASE REPORT

A 45 year old male sustained fall from height, 5 days back in one of the coal mines in Meghalaya, India leading to blunt abdominal injury. The patient had no loss of consciousness but he had an episode of vomiting after the injury. At presentation the patient had abdominal distension, sub conjunctival haemorrhage in the left eye and reddish discoloration of urine. All vitals were within normal limits. No external injury was noted over the abdomen and pelvis. Liver and renal function tests were within normal limits. Ascites was tapped and Foleys catheter was kept in the urinary bladder. X-ray of the chest and abdomen showed no fracture [Tables/Fig- 1,2]. Ultrasound was performed using Logiq P5 ultrasound system (GE Healthcare, Milwaukee, USA) which showed a defect (18mm) in the bladder dome communicating between the bladder and the peritoneum with presence of ascites [Tables/

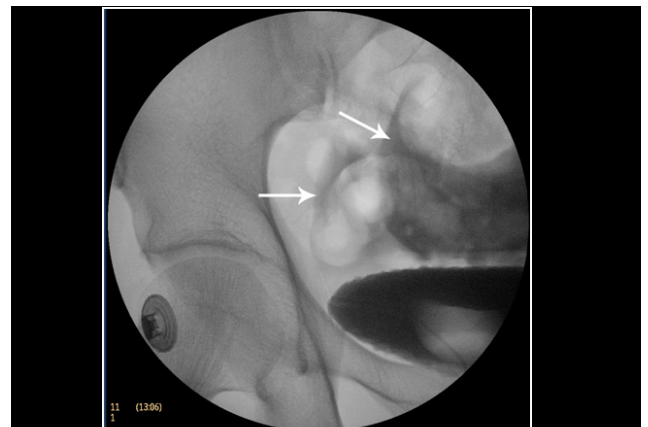
Fig-3a,3b]. Sonographically the findings were consistent with an intraperitoneal bladder rupture. No other obvious visceral injury was noted. Immediately contrast cystography was done on BV Endura C arm machine (Philips, Holland), which showed



**[Table/Fig-3a,b]:** Ultrasound of 45 old male with traumatic Intra-peritoneal bladder rupture **a.** Pelvic free fluid and bladder dome rupture (white arrow) **b.** Magnified Image with clearer visualization of the bladder rupture (white arrow)



**[Table/Fig-1]:** Chest X-ray is normal **[Table/Fig-2]:** X-ray abdomen shows obvious abnormality



**[Table/Fig-4]:** Cystography showing intraperitoneal pelvic contrast extravasation outlining the bowel walls (white arrows)

intraperitoneal spillage of contrast into the pelvis outlining the adjacent bowel loops confirming our diagnosis [Table/Fig-4]. Emergency laparotomy was performed which showed a 5 cm long rupture in the bladder dome. Bladder was repaired by urologist in three layers after placing a suprapubic catheter in the urinary bladder. The patient recovered over a period of one month.

## DISCUSSION

Urinary bladder ruptures are most frequently seen in multitrauma patients with blunt injuries [1-3]. Bladder distension at the time of injury increases the likelihood of bladder rupture. Treatment of intraperitoneal bladder rupture requires laparotomy and surgical repair of the bladder defect and cystostomy. Computed tomography (CT) cystography is the investigation of choice for any suspected bladder injury. Our case presented was an intraperitoneal bladder injury primarily diagnosed by ultrasound imaging and subsequently confirmed by cystography and operative findings.

Bladder injuries were considered to be fatal in the past. Any delay in diagnosis is usually associated with increased mortality. Therefore, early diagnosis using imaging can assist the decision of the surgeon for emergency laparotomy. Bladder injury can be intraperitoneal, extraperitoneal or combined. Though extraperitoneal bladder rupture is most common, intraperitoneal bladder rupture can occur in approximately 10–20% of major bladder injuries [4]. In a study by Wah et al., 80% of patients with bladder injuries have associated pelvic fractures [5]. Our case has no evidence of pelvic fracture or any other bony injury. The sudden increase in intravesical pressure

due to blunt injury resulted in the rupture at the bladder dome. Visualization of the rupture using ultrasound is challenging as the ruptures are usually small. However in our case, the presence of the linear anechoic wall discontinuity, outlined by fluid in both the pelvis and bladder led to the ultrasonic diagnosis of post-traumatic intraperitoneal bladder dome rupture. Peritoneal contrast extravasation in cystography using CT or fluoroscopy is still the choice investigation. However, ultrasound being a cheap, rapid and non-invasive method, it is an invaluable procedure to detect bladder rupture leading to immediate and prompt management.

## CONCLUSION

Blunt abdominal injury resulting in intraperitoneal bladder injury without evidence of pelvic fracture is uncommon. Though cystography is the investigation of choice, yet ultrasound being a cheap, rapid, non-invasive, radiation free and easy to perform procedure can lead to or assist in it confirming the diagnosis.

## REFERENCES

- [1] Cass AS. Diagnostic studies in bladder rupture: indications and techniques. *Urol Clin North Am.* 1989; 16(2):267-73.
- [2] Sandler CM. Bladder trauma. In: Pollack HW, ed. *Clinical urology*. Vol 2. Philadelphia, Pa: Saunders, 1990; 1505-21.
- [3] Corriere JN, Sandler CM. Bladder rupture from external trauma: diagnosis and management. *World J Urol.* 1999;17(2):84-89.
- [4] Mirvis SE, Dunham C. Abdominal/pelvic trauma. In: Mirvis SE, Young JW, eds. *Diagnostic imaging in trauma and critical care*. Baltimore, Md: Williams & Wilkins, 1992; 148-242.
- [5] Wah TM, Spencer JA. CT of adult urinary tract trauma. *Imaging.* 2005;17(1): 53-68.

### AUTHOR(S):

1. Dr. Donboklang Lynser
2. Dr. Evarisalin Marbaniang

### PARTICULARS OF CONTRIBUTORS:

1. Radiologist, Department of Radiology and Imaging, Ganesh Das Hospital, Lawmali, Shillong 793001, Meghalaya, India.
2. Assistant Professor, Department of Pathology, North Eastern Indira Gandhi Regional Institute of Health and Medical Sciences, Mawdiangdiang, Shillong 793018, Meghalaya, India.

### NAME, ADDRESS, E-MAIL ID OF THE CORRESPONDING AUTHOR:

Dr. Donboklang Lynser,  
Department of Radiology and Imaging, Ganesh Das  
Hospital, Lawmali, Shillong-793001, Meghalaya, India.  
E-mail: bokdlynser@yahoo.co.in

### FINANCIAL OR OTHER COMPETING INTERESTS:

None.

Date of Publishing: Oct 01, 2015